'It is more blessed to give than to receive.

Contents

Heart

- Radiology of the cardiovascular system 2
- Normal heart X ray 6
- Radiological signs of cardiac chambre enlargement 8
- Cardiomegaly without characteristic shape 13
- Cardiomegaly with characteristic shape 18
  . Pericardial effusion (flask shaped heart) 18
  . Fallot tetralogy (boot shaped heart) 20
  . Transposition of great arteries (egg shaped heart) 21
- Isolated dextrocardia 22
- Dextrocardia with situs inversus 23

Chest

- Radiology of the respiratory system 24
- Normal chest X ray 26
- Unilateral opacity occupying one side 28
  . Pleural effusion 29
  . Lobar pneumonia 37
  . Lung fibrosis 42
  . Lung collapse 43
- Bilateral small opacities 47
  . Miliary shadows 48
  . Bronchopneumonia 50
  . Bronchiectasis 52
- Air fluid level 53
  . Lung abscess 54
  . Hydropneumothorax or pyopneumothorax 59
- Unilateral hypertranslucency 61
  . Pneumothorax 62
  . Emphysema 63
- Hilar shadows 64

WhiteKnightLove

Freely you have received; freely give.

Bones

- Radiology of long bones 65
- Normal bone 66
- Chronic hemolytic anemia 67
- Active rickets 69
- Healing rickets 71
- Healed rickets 73
- Osteogenesis imperfecta 74
- Osteopetrosis 76

Skull

- Normal skull X ray 78
- Microcephaly 79
- Increased intracranial tension 80
- Craniostenosis 83
- Chronic hemolytic anemia 84
- Intracranial calcification 85

Abdomen

- Congenital hypertrophic pyloric stenosis 87
- Duodenal atresia 89
- Intestinal obstruction (low obstruction) 90

WhiteKnightLove

'It is more blessed to give than to receive.

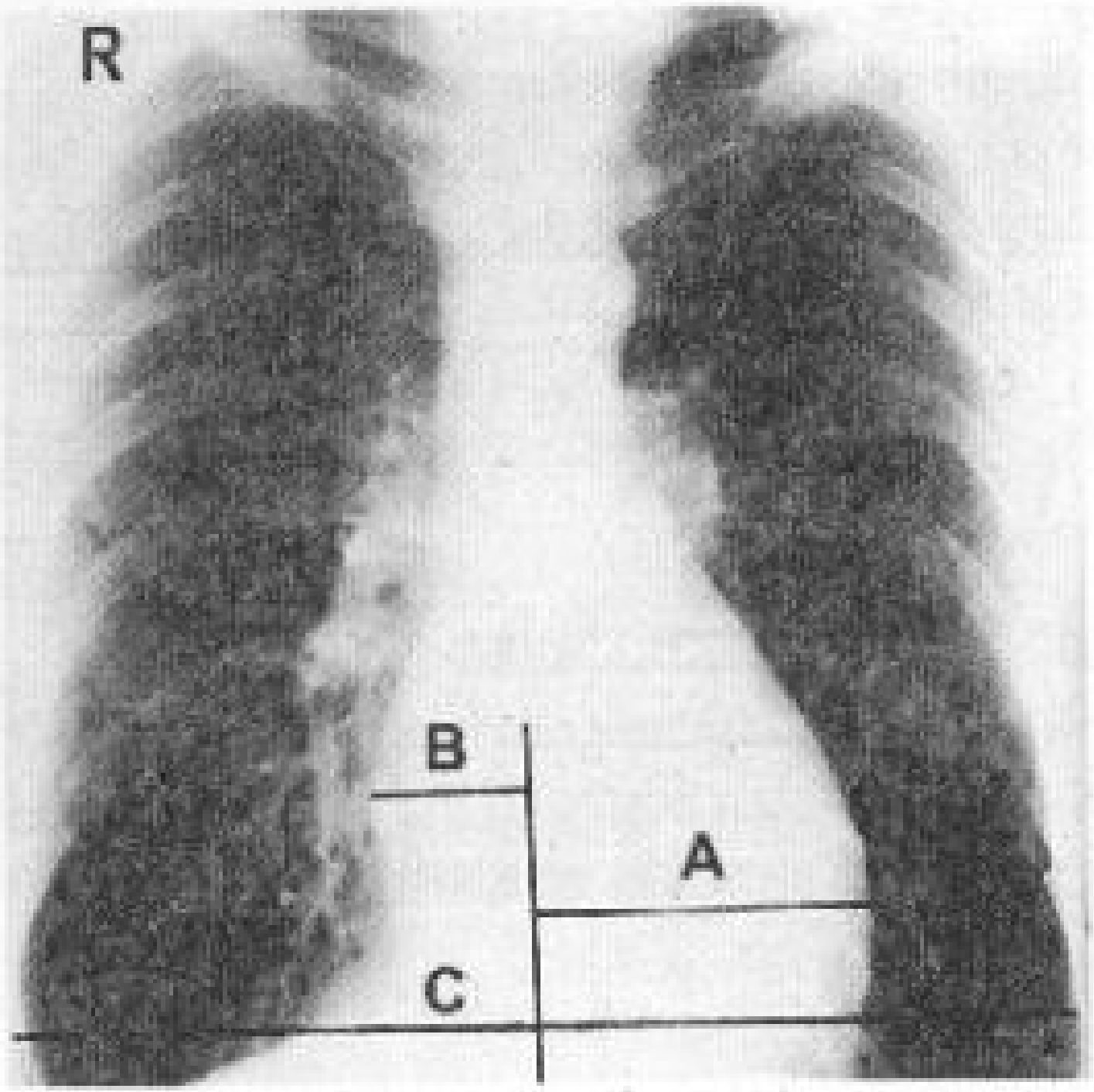

Comment as: *Cardio-thoracic ratio is normal or Cardio-thoracic ratio increased.*

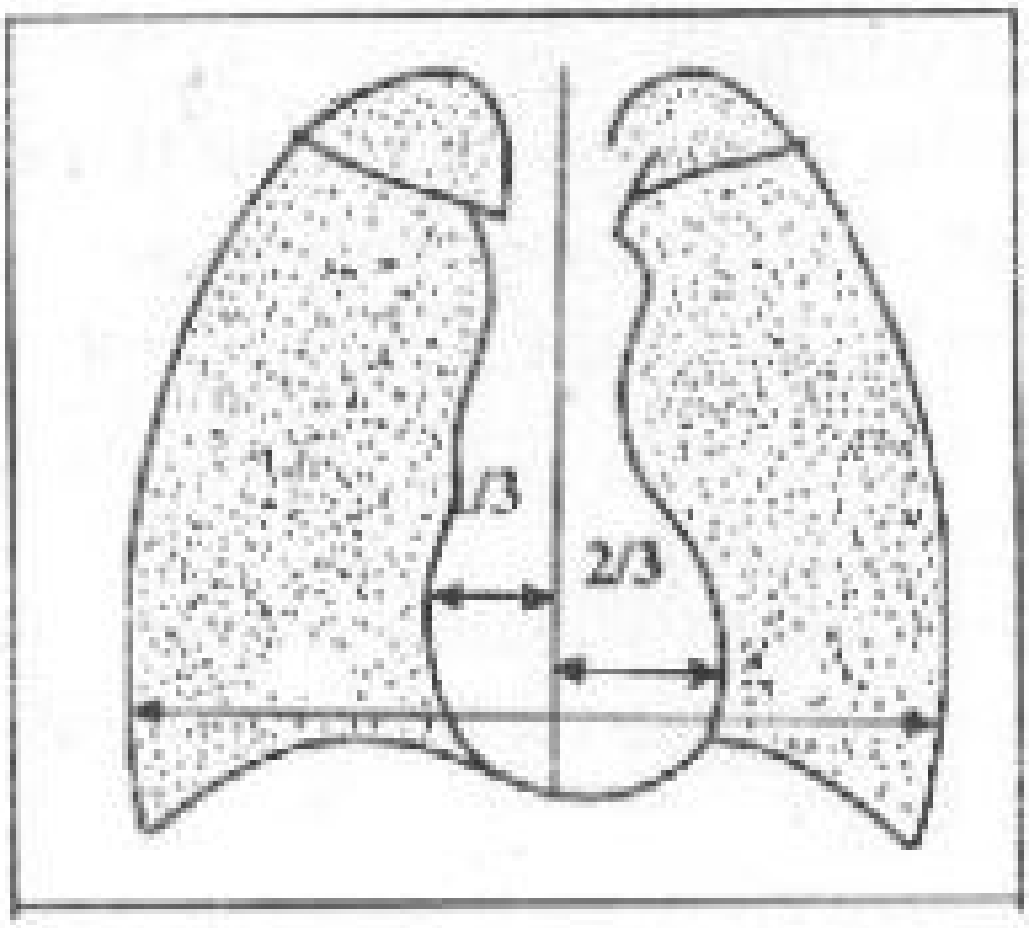

Normally, two third of the cardiac shadow lies to the left side of the middle line and one third to the right.

6- Cardiophrenic angle on the left side
It is the angle between the left copula of the diaphragm and left border of heart, normally it is acute angle

WhiteKnightLove

Freely you have received; freely give.

Normal heart X ray

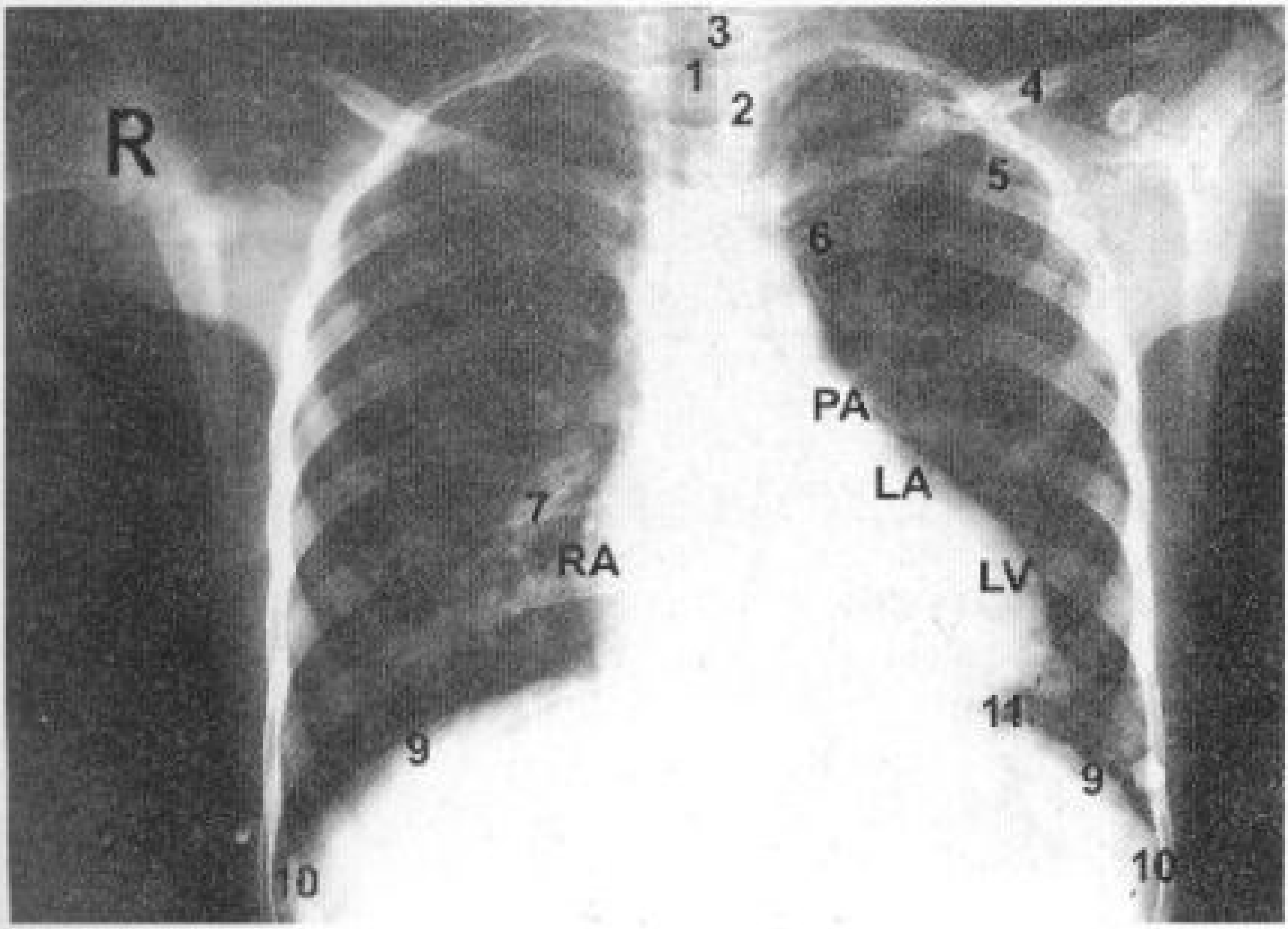

1- Tracheal air column
2- Vertebral column
3- Spinous processes of the vertebrae
4- Clavicles
5- Anterior ribs
6- Posterior ribs
7- Bronchovascular markings
8- Lung fields
9- Diaphragmatic copulae
10- Costophrenic angles
11- Cardiophrenic angle
RA: - right atrium
PA: - Pulmonary artery
LA: - left atrium
LV: - left ventricle

WhiteKnightLove

'It is more blessed to give than to receive.

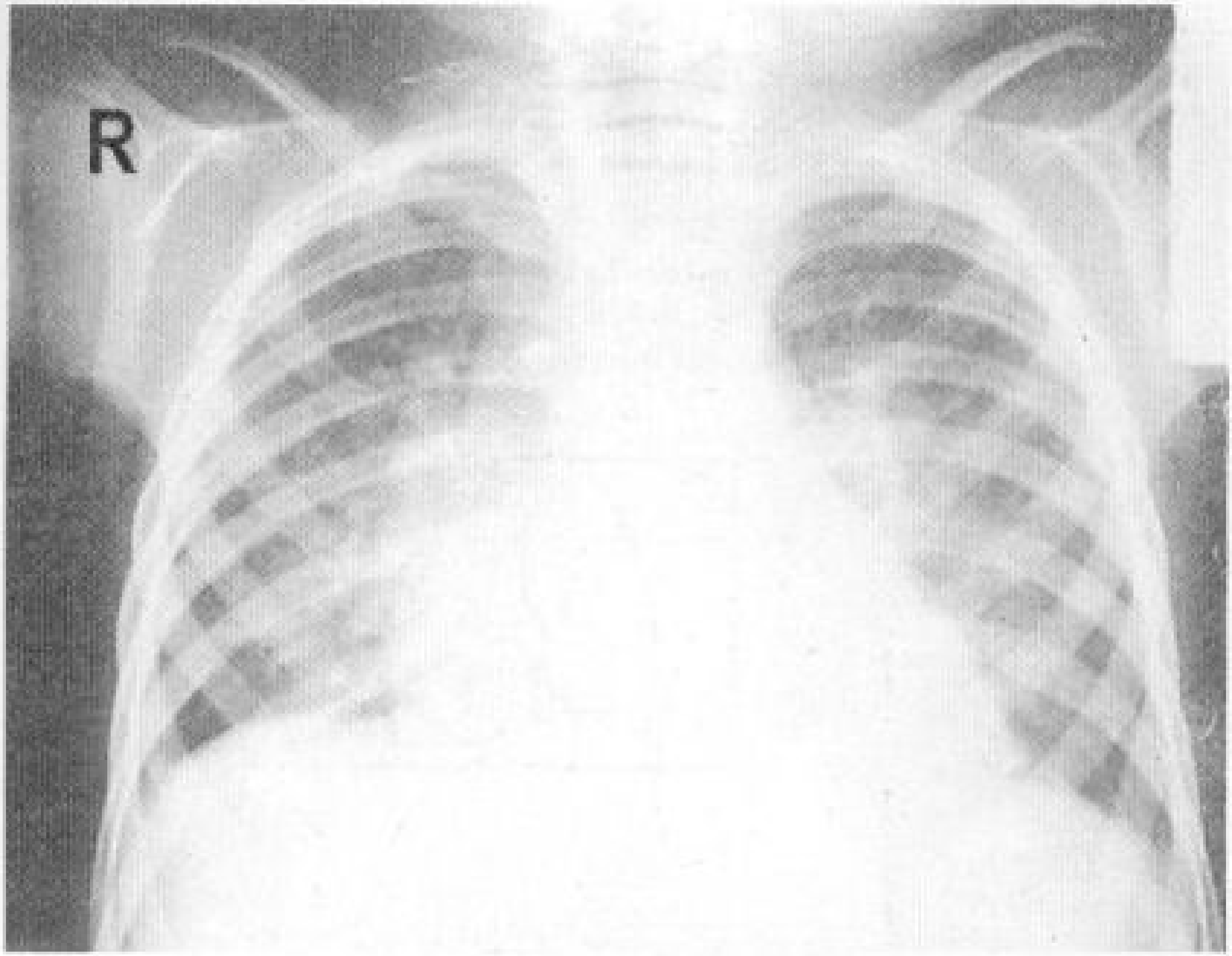

Left ventricular enlargement

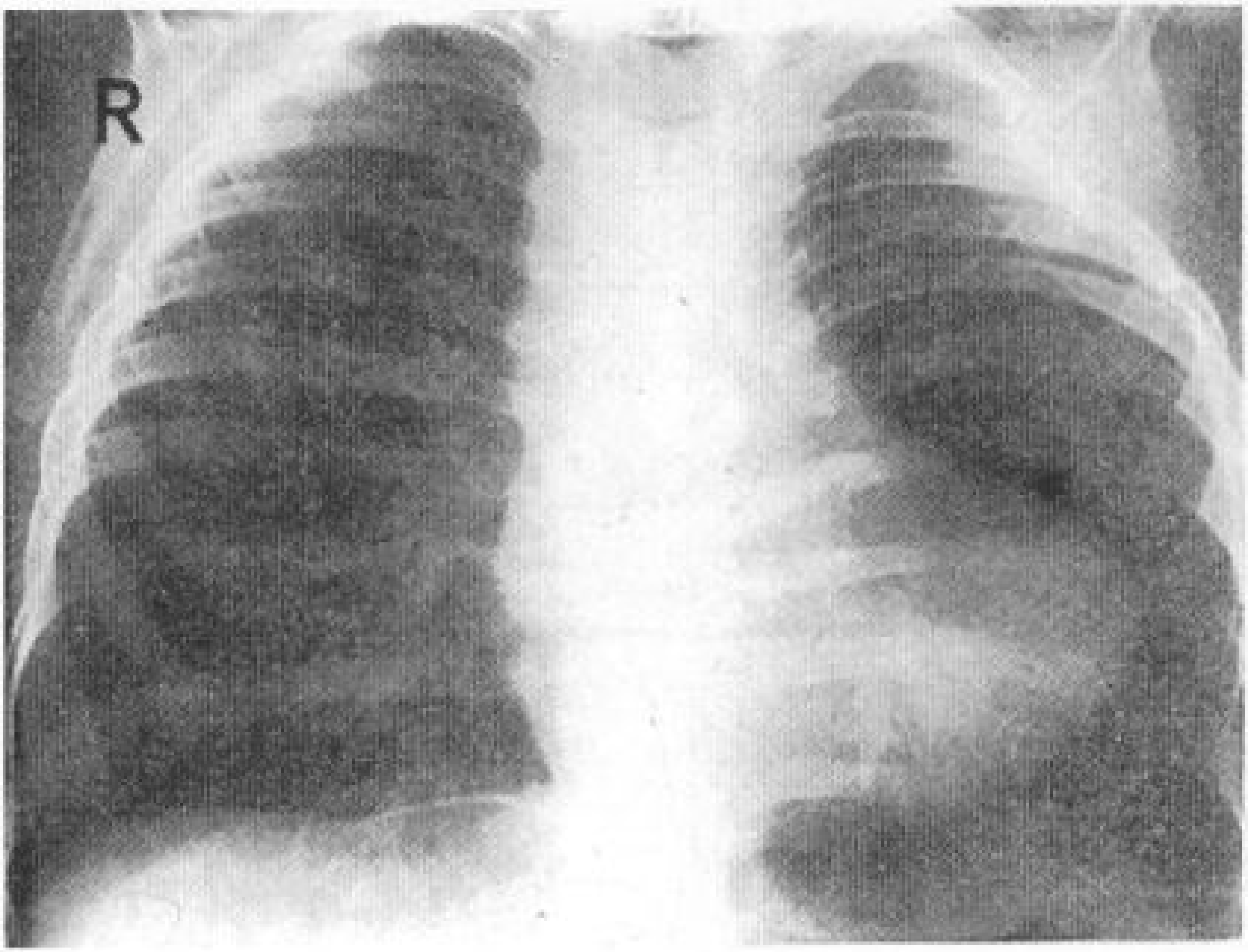

Right ventricular enlargement

WhiteKnightLove

Freely you have received; freely give.

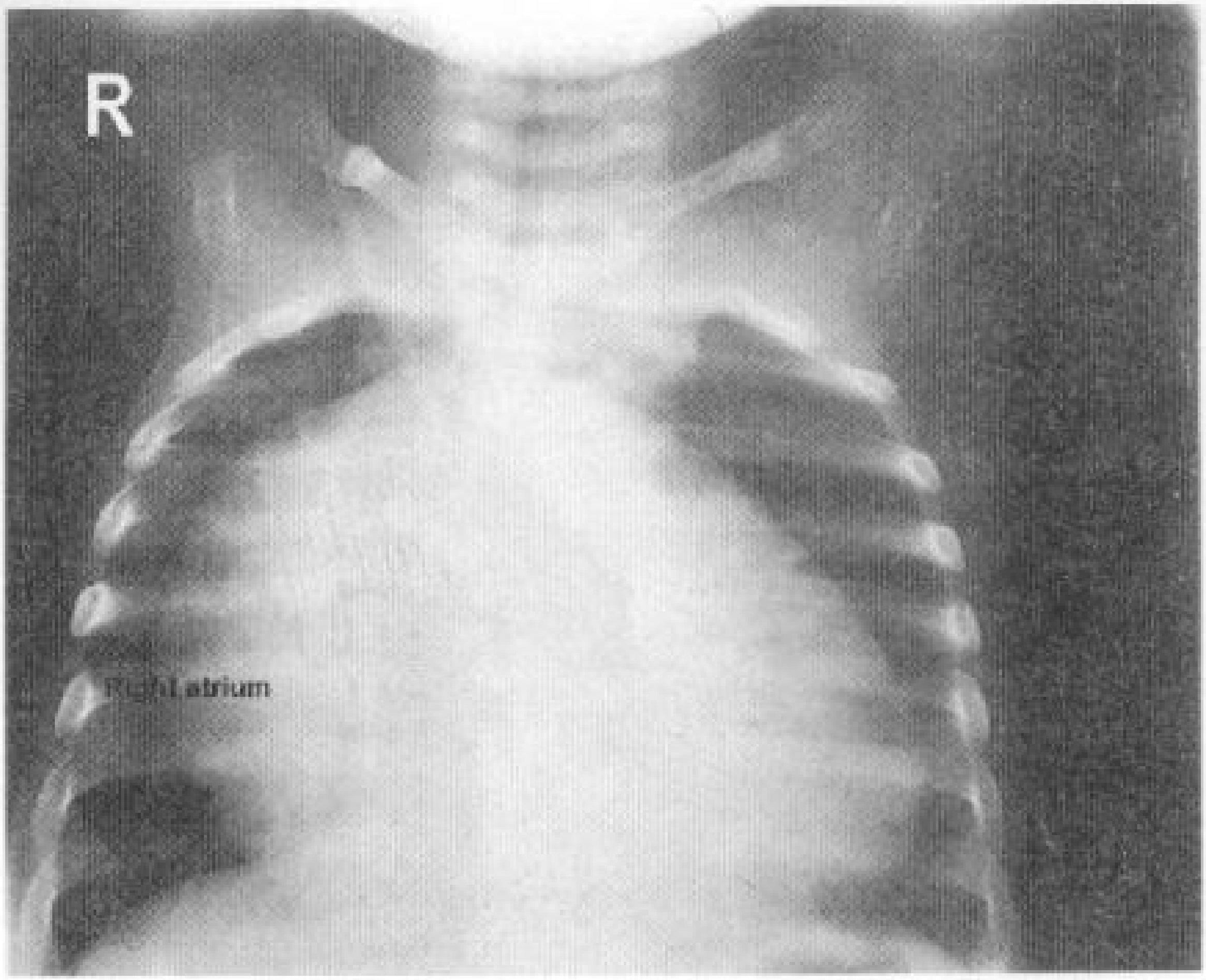

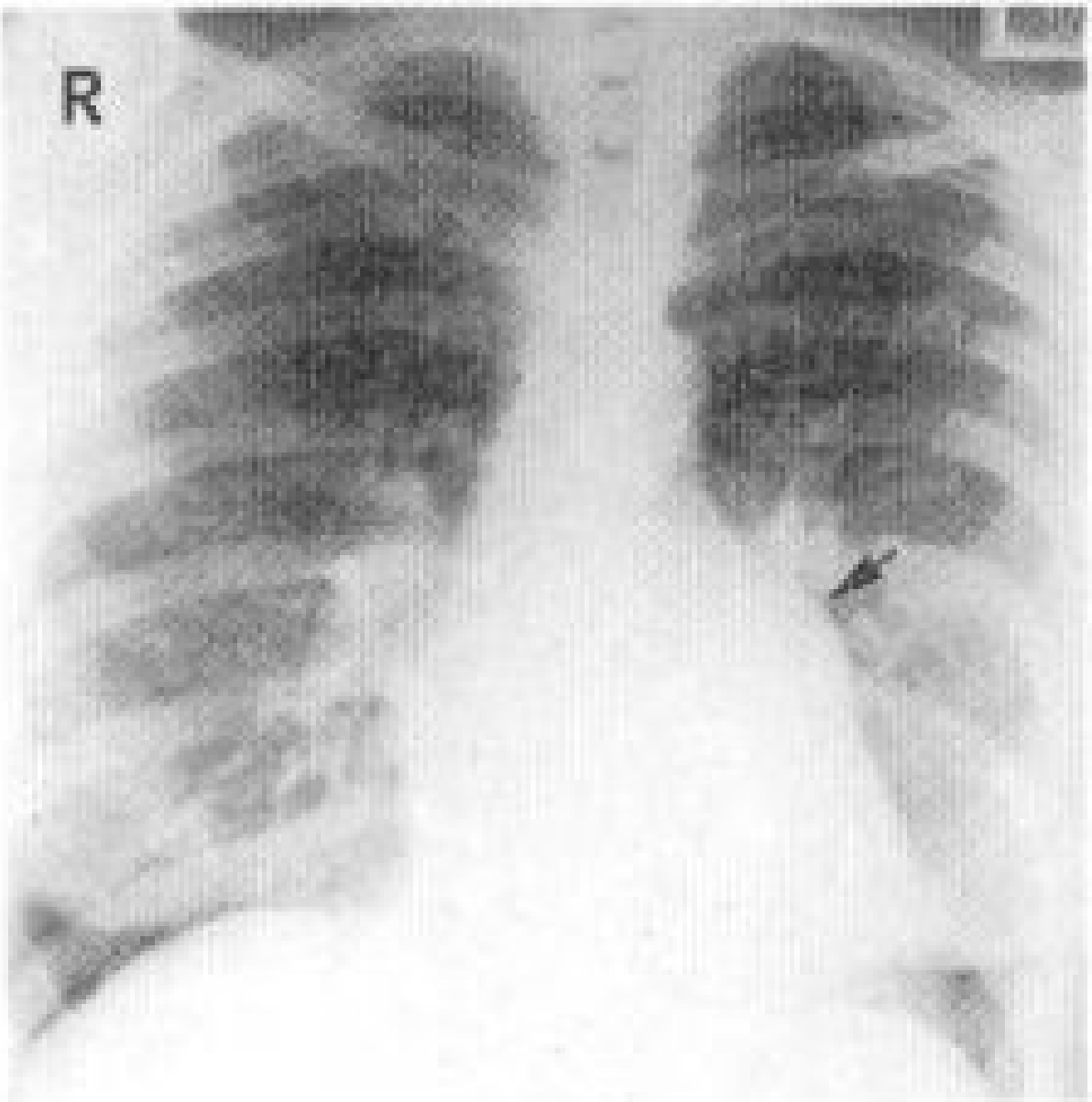

Left atrium dilatation

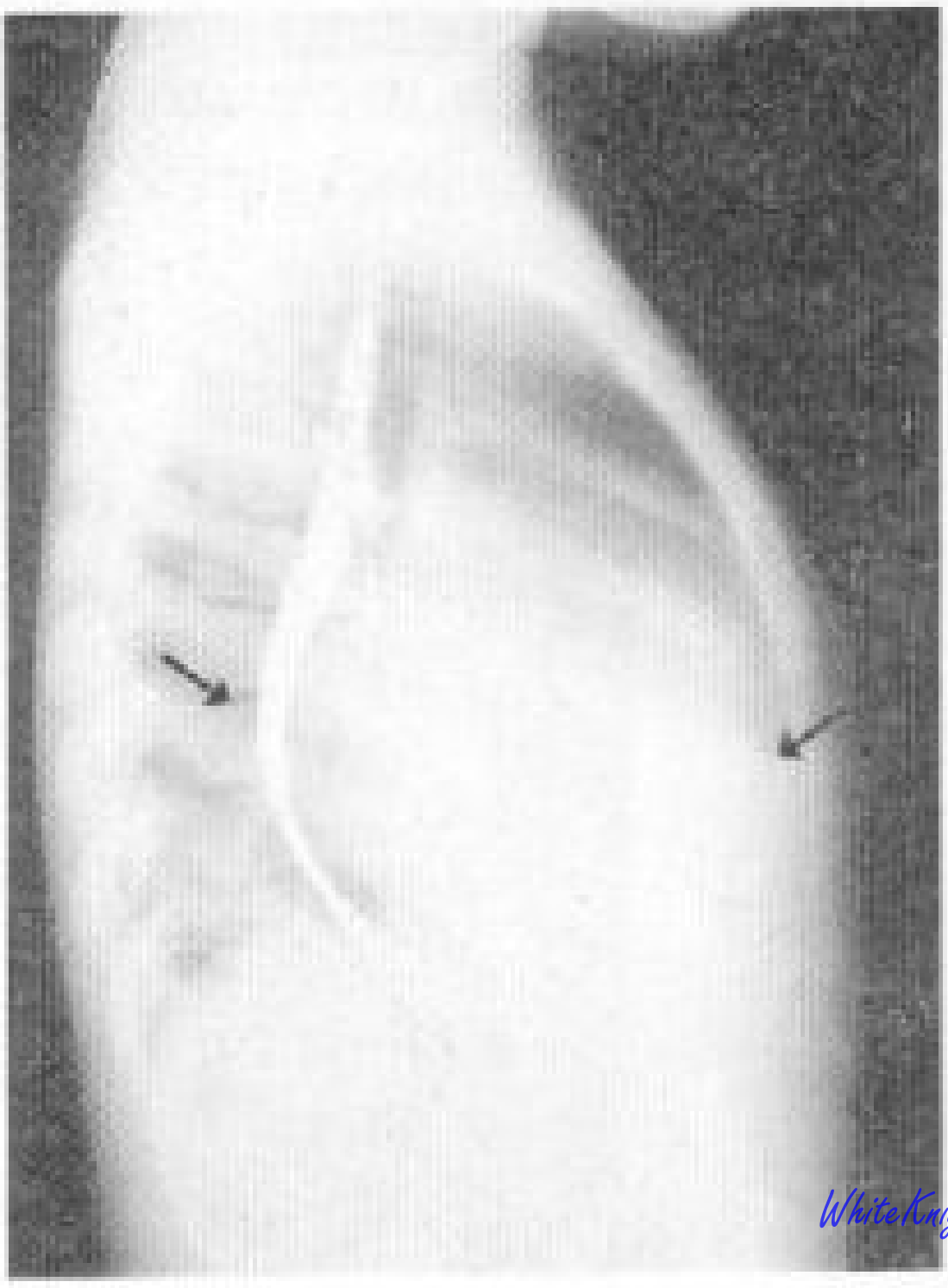

WhiteKnightLove

'It is more blessed to give than to receive.

Radiological abnormalities of pulmonary blood vessels

1- Pulmonary plethora

. It results from increased blood flow to the lung e.g. ventricular septal defect

. Vascular markings are enlarged at the hilum and visible in the outer third of the lung filed.

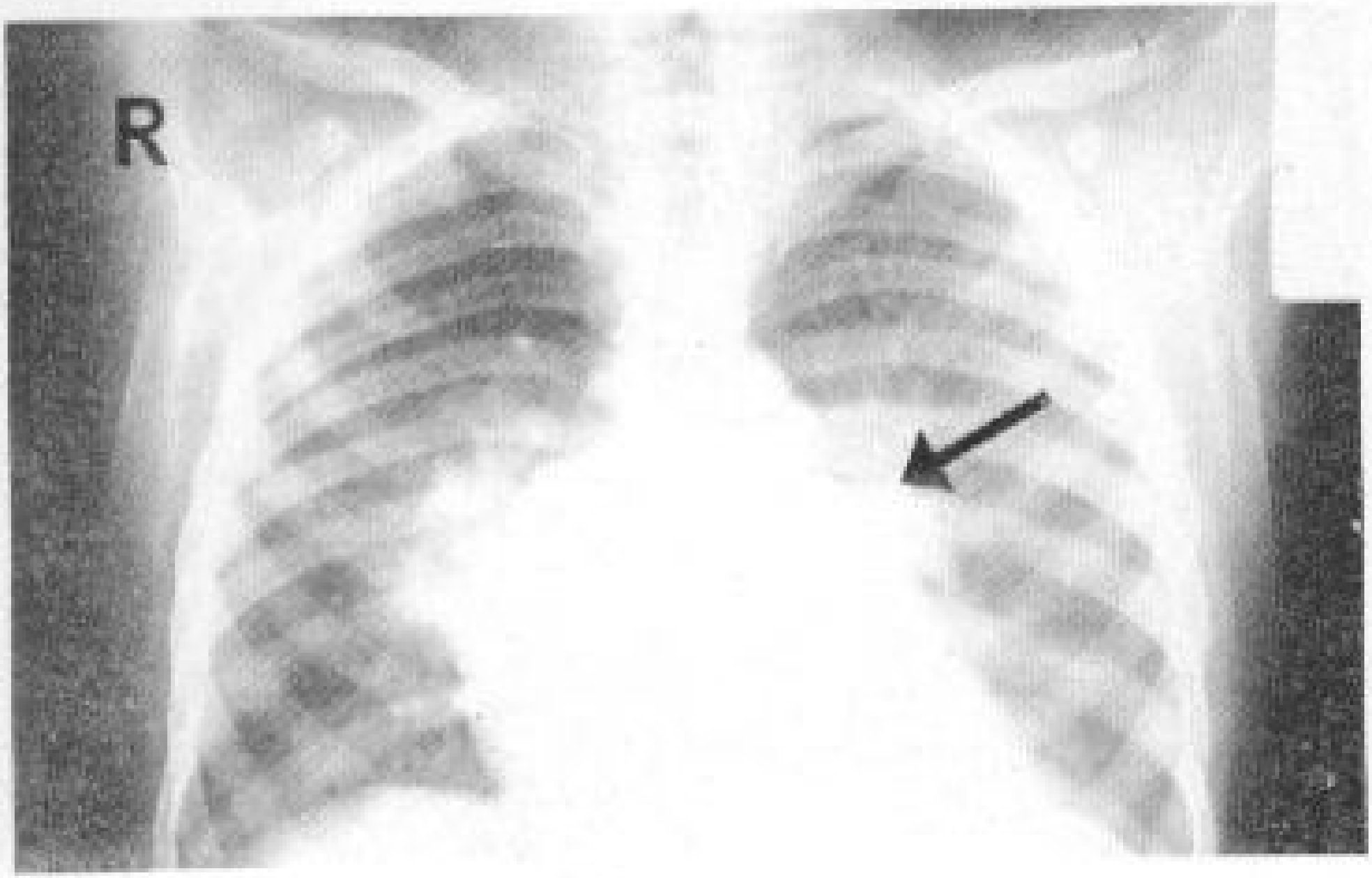

2- Pulmonary oligemia

. It results from decreased blood flow to the lung e.g. Fallot tetralogy

. The vascular markings are few and only seen in the hilum

WhiteKnightLove

Freely you have received; freely give.

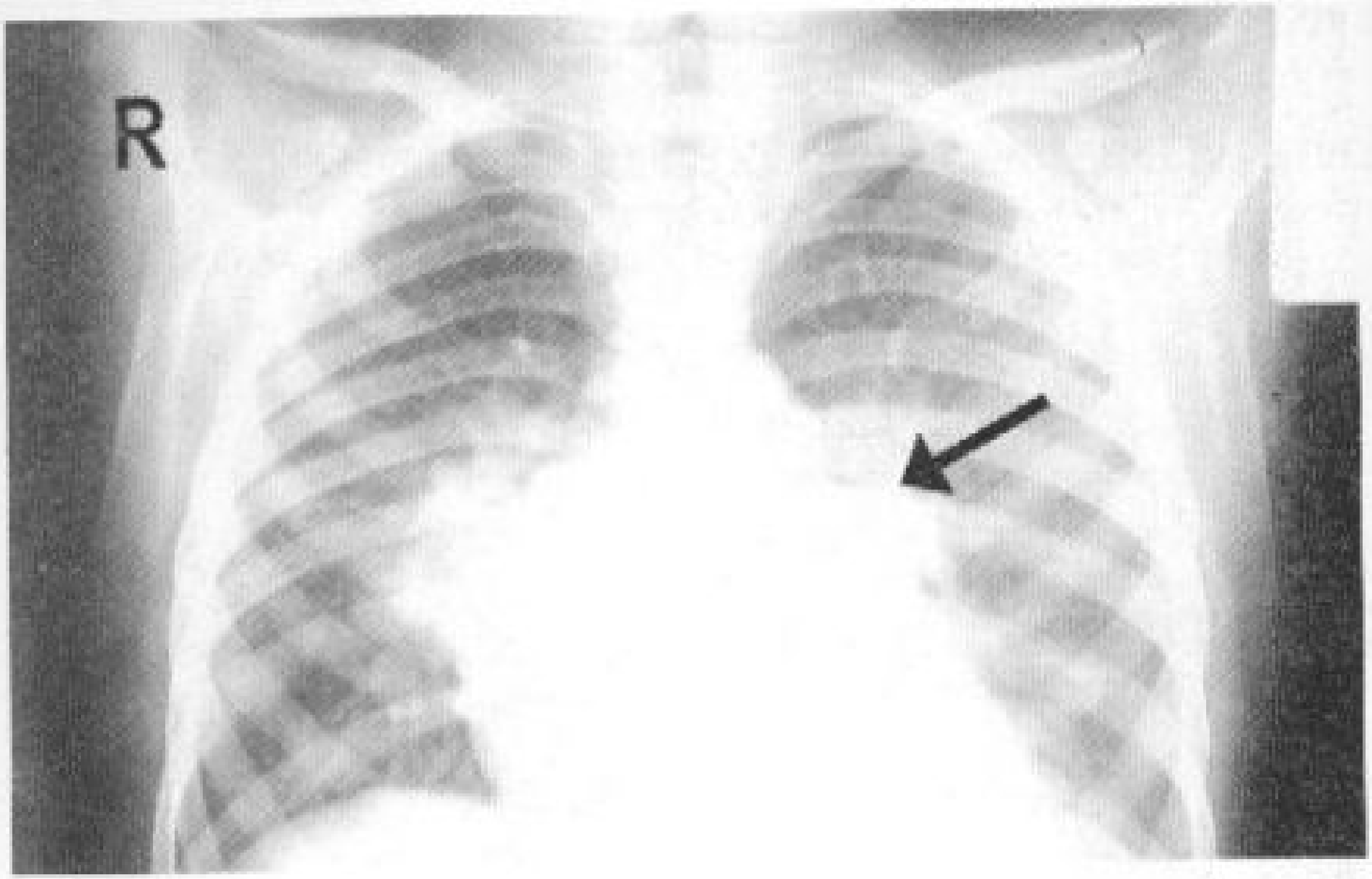

- Plain X ray chest and heart
- Postero-anterior view
- The patient is well centralized
- Costophrenic angles are free on both sides
- Cardio-thoracic ratio increased
- Cardiophrenic angle on the left side is obtuse
- Bulging left cardiac border on the second space and third space
- Bulging right cardiac border
- Pulmonary plethora

Radiological diagnosis (anatomical diagnosis)

Cardiomegaly due to enlargement of left ventricle, left atrium pulmonary artery and right atrium

Etiological diagnosis: - Cardiomegaly for differential diagnosis

- Rheumatic heart disease
  Mitral valve lesion alone or in association with aortic valve
- Congenital heart disease e.g. ventricular septal defect
- Myocarditis and heart failure e.g. viral myocarditis
- Cardiomyopathy e.g. congestive cardiomyopathy

WhiteKnightLove

'It is more blessed to give than to receive.

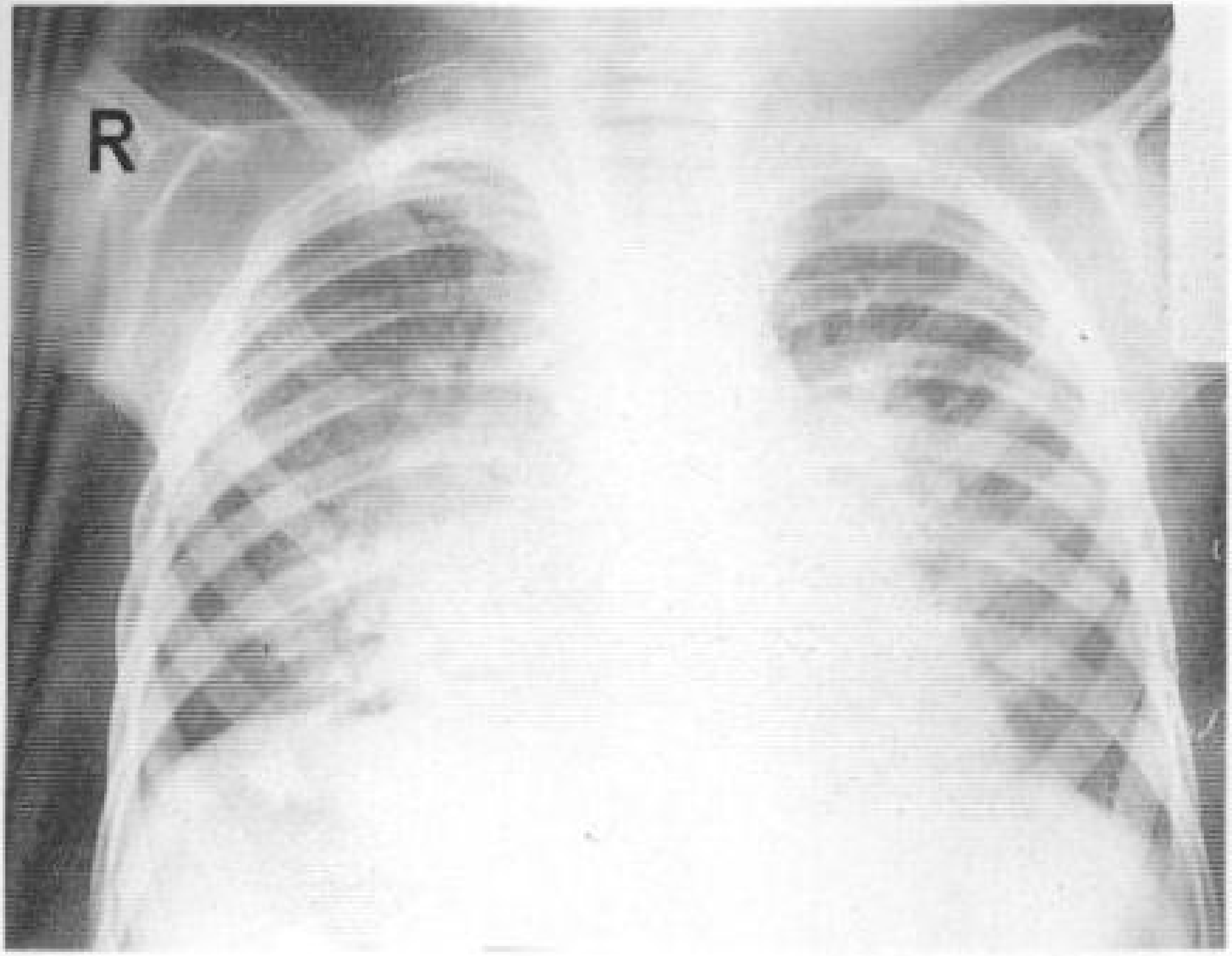

- Plain X ray chest and heart
- Postero-anterior view
- The patient is not well centralized
- Costophrenic angles are free on both sides
- Cardio-thoracic ratio increased
- Cardiophrenic angle on the left side is obtuse
- Straight left cardiac border (waist obliteration): mitralized heart
- Bulging right cardiac border
- Pulmonary plethora

Radiological diagnosis (anatomical diagnosis)

Cardiomegaly due to enlargement of left ventricle, left atrium, pulmonary artery and right atrium

Etiological diagnosis: - cardiomegaly for differential diagnosis

- Rheumatic heart disease
  Mitral valve lesion alone or in association with aortic valve
- Congenital heart disease e.g. ventricular septal defect
- Myocarditis and heart failure e.g. viral myocarditis
- Cardiomyopathy e.g. congestive cardiomyopathy

WhiteKnightLove

Freely you have received; freely give.

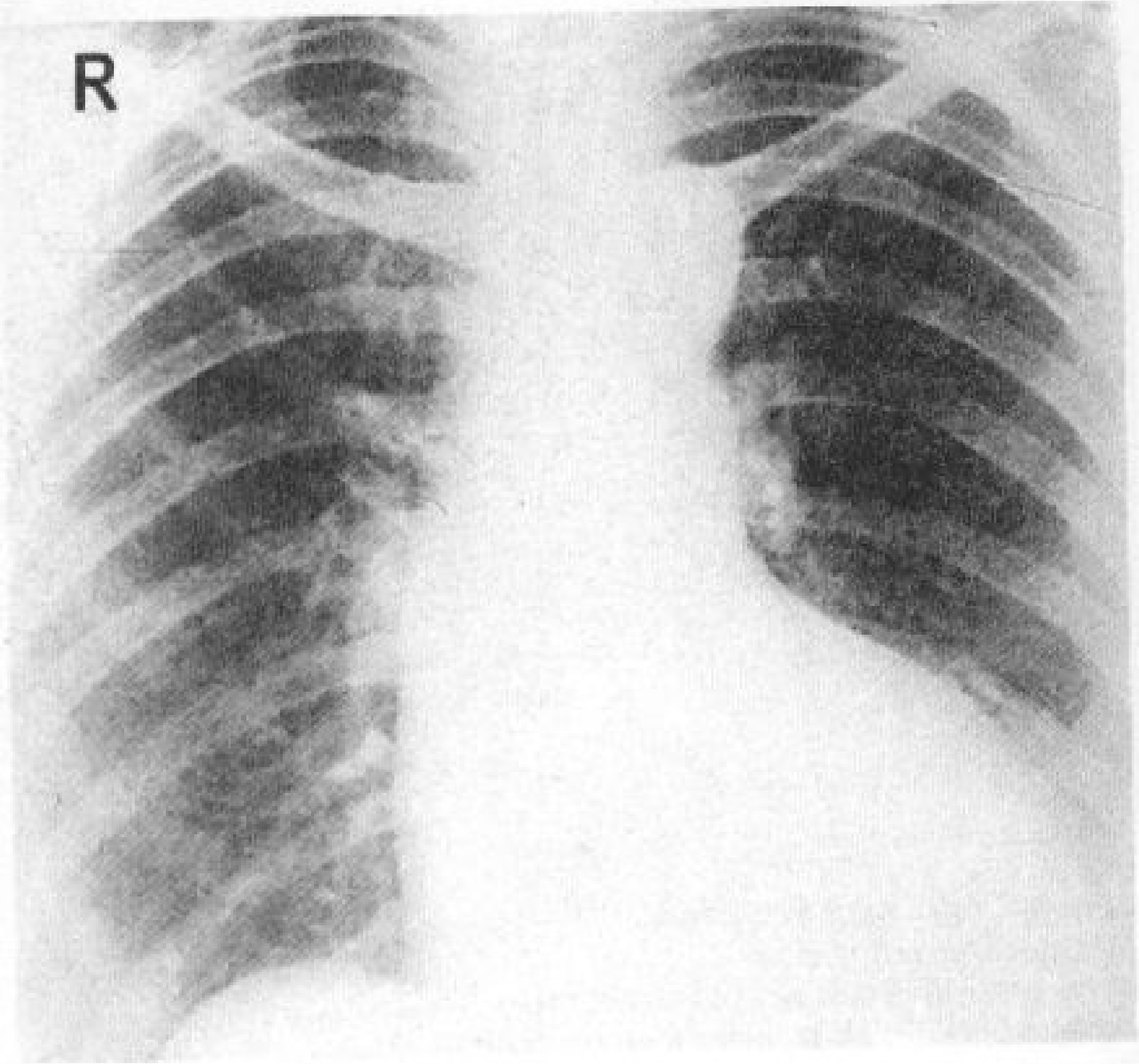

- Plain X ray chest and heart
- Postero-anterior view
- The patient is well centralized
- Costophrenic angles are free on both sides
- Cardio-thoracic ratio increased
- Cardiophrenic angle on the left side is obtuse
- Normal right cardiac border

Radiological diagnosis (anatomical diagnosis)

Cardiomegaly due to enlargement of left ventricle

Etiological diagnosis: - causes of left ventricular enlargement

- Aortic valve disease
- Systemic hypertension
- Mitral valve disease: mitral regurgitation

WhiteKnightLove

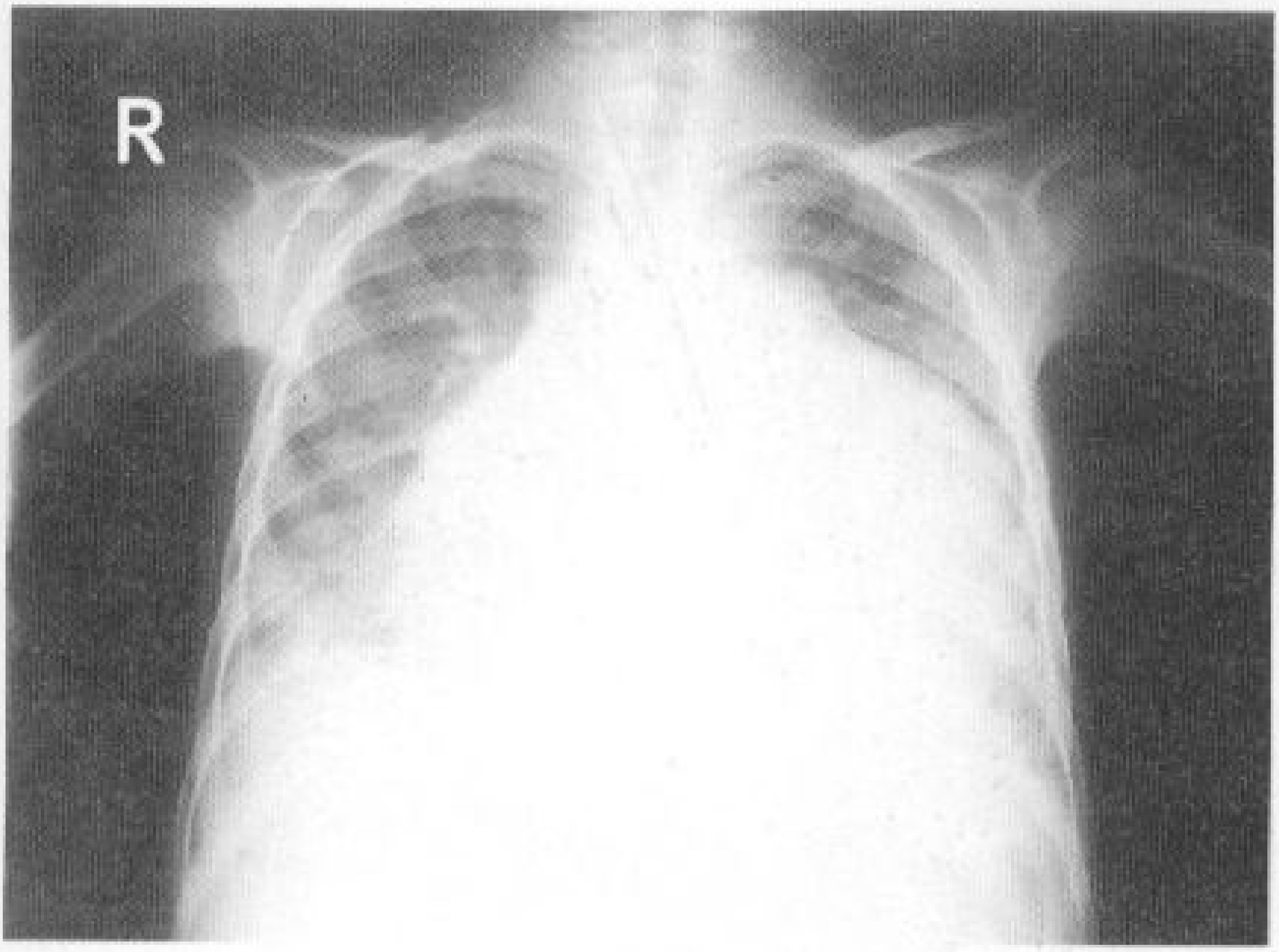

- Plain.X ray chest and heart
- Postero-anterior view
- The patient is well centralized
- Costophrenic angles are free on both sides
- Cardio-thoracic ratio increased markedly
- Cardiophrenic angle on the left side is obtuse
- Marked bulge of the left and right cardiac borders
- Increased in the pulmonary vascular markings

Radiological diagnosis (anatomical diagnosis)

Huge cardiomegaly due to marked enlargement of all cardiac chambers

Etiological diagnosis: - Cardiomegaly for differential diagnosis

- Rheumatic heart disease
  Mitral valve lesion alone or in association with aortic valve
- Congenital heart disease e.g. ventricular septal defect
- Myocarditis and heart failure e.g. viral myocarditis
- Cardiomyopathy e.g. congestive cardiomyopathy

However with huge cardiac shadow like this, pericardial effusion should be excluded by echocardiography

WhiteKnightLove

Freely you have received; freely give.

II- Cariomegaly with characteristic shape

1- Flask shaped heart: pericardial effusion

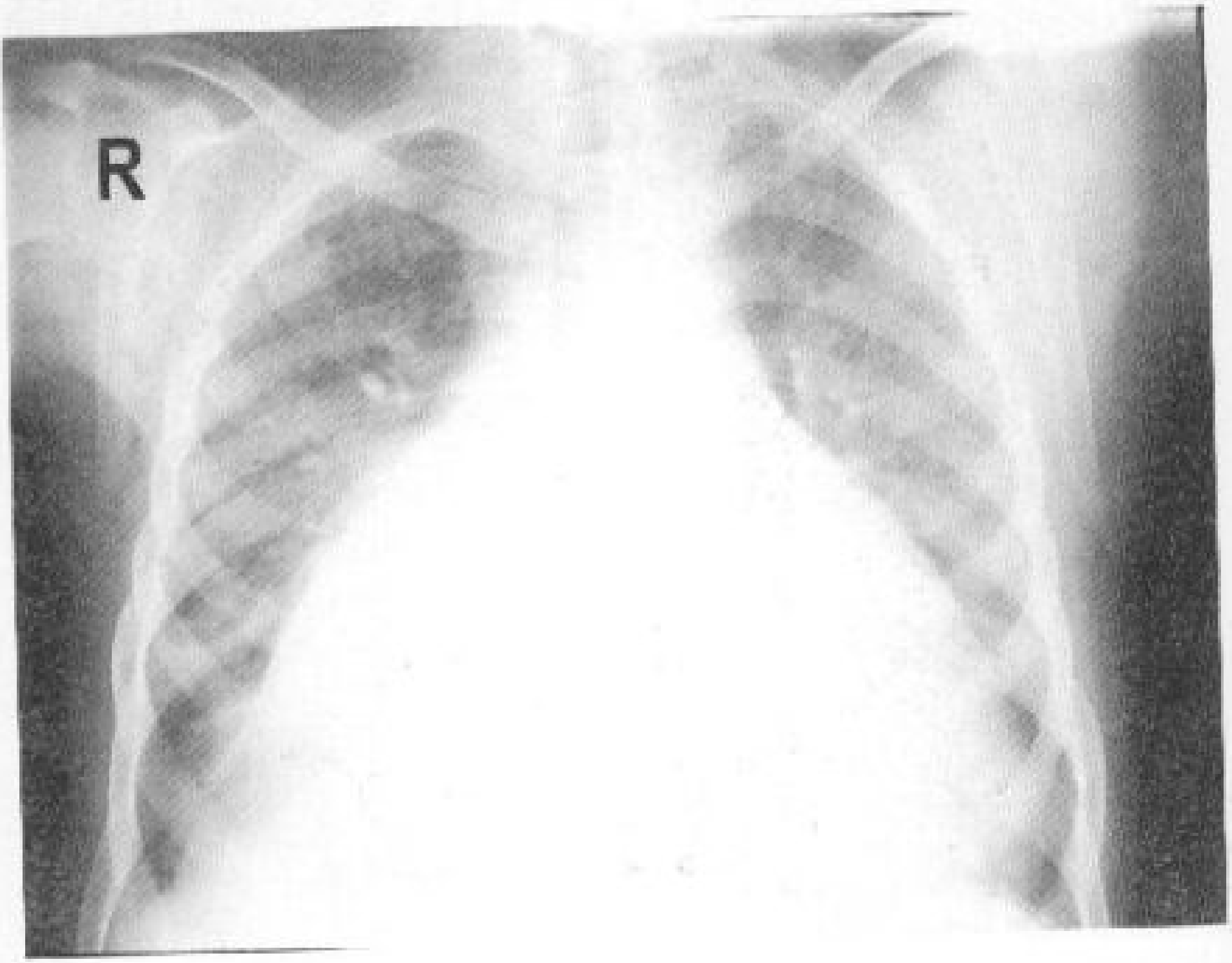

- Plain X ray chest and heart
- Postero-anterior view
- The patient is well centralized
- Costophrenic angles are free on both sides
- Cardiophrenic angle on the left side is <u>acute</u>
- Marked increase in the cardio-thoracic ratio
- Symmetrical bulge of the left and right cardiac borders
- The borders are very well defined (stenciled)
- Broad cardiac base(accumulation of fluid in the pericardial sac)
- Normal pulmonary vascular markings

Causes of pericardial effusion

- Serous: -
  Rheumatic disease: - rheumatic fever- systemic lupus
  Infections: - viral pericarditis- TB
- Pus: - suppurative pericarditis
- Blood: - trauma

WhiteKnightLove

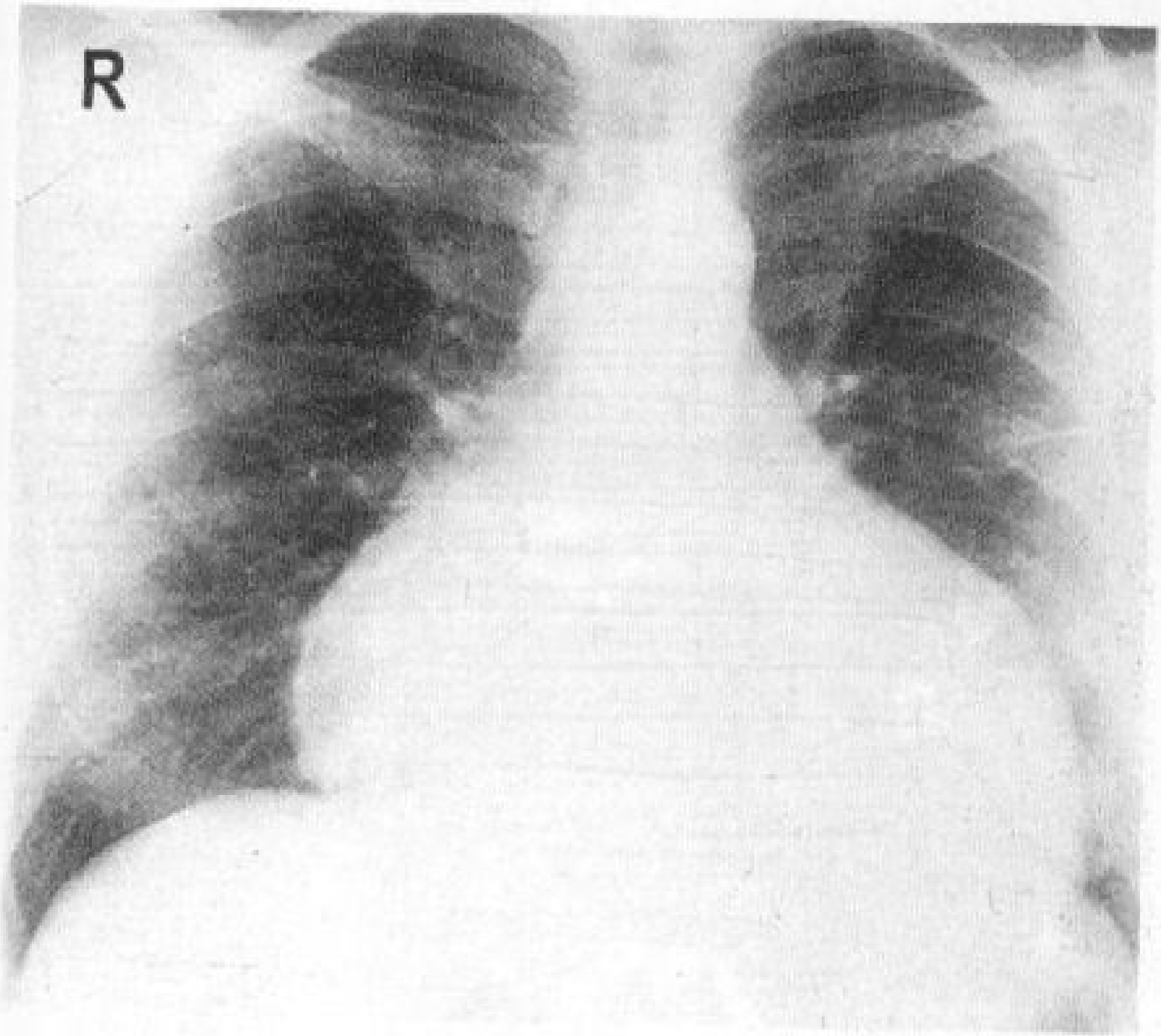

- Plain X ray chest and heart
- Postero-anterior view
- The patient is well centralized
- Costophrenic angles are free on both sides
- Cardiophrenic angle on the left side is acute
- Marked increase in the cardio-thoracic ratio
- Symmetrical bulge of the left and right cardiac borders
- The borders are very well defined (stenciled)
- Broad cardiac base(accumulation of fluid)
- Normal pulmonary vascular markings

Flask shaped heart: pericardial effusion

WhiteKnightLove

Freely you have received; freely give.

2- Boot shaped heart: Fallot tetralogy

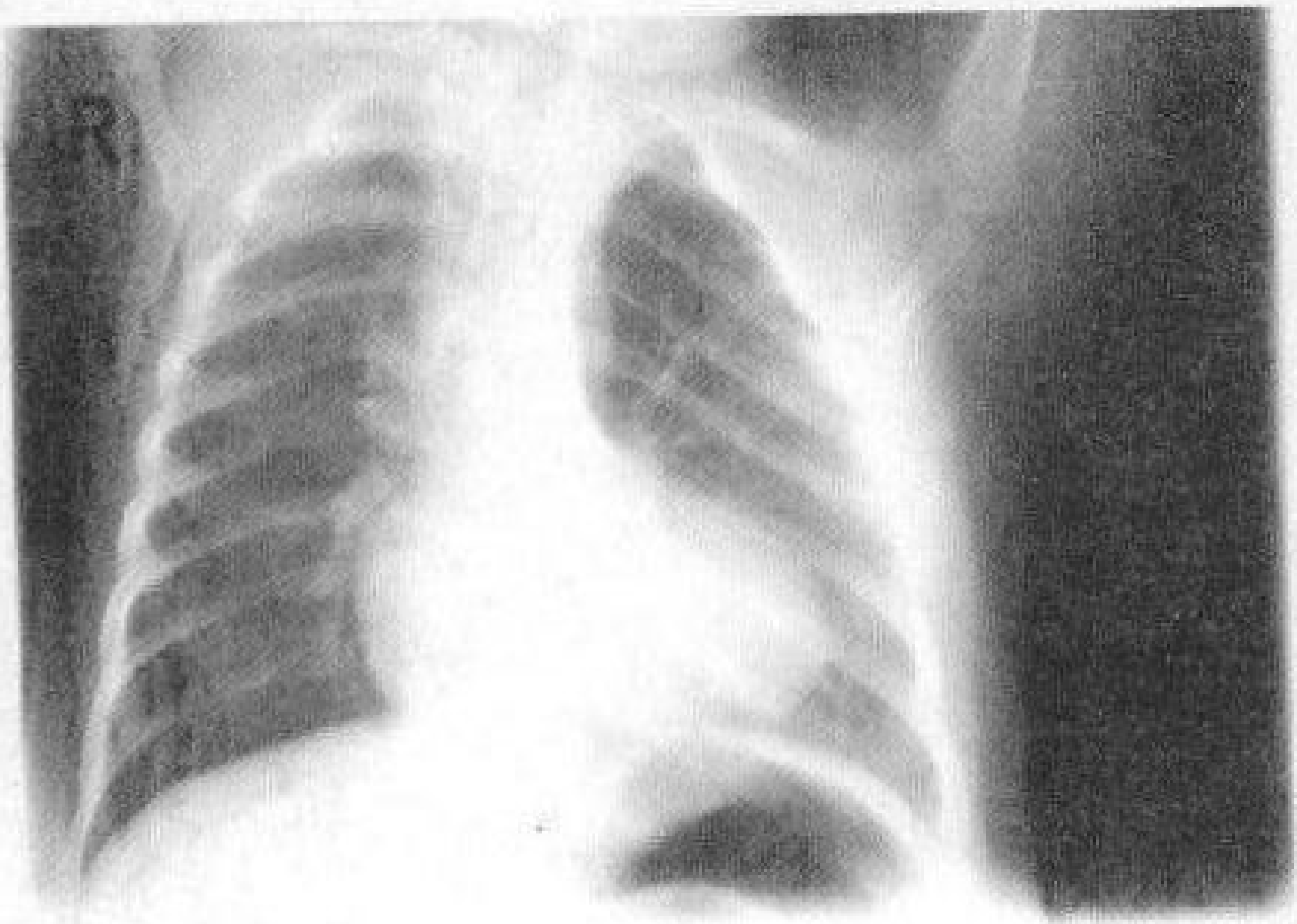

- Plain X ray chest and heart
- Postero-anterior view
- The patient is not centralized
- Costophrenic angles are free on both sides
- Cardio-thoracic ratio is normal or mildly increased
- Cardiophrenic angle on the left side is acute with uplifted apex
- Exaggerated waist (pulmonary hypoplasia)
- Decreased pulmonary vascular markings(lung oligemia)

WhiteKnightLove

'It is more blessed to give than to receive.

3- Egg shape heart: transposition of great arteries (TGA)

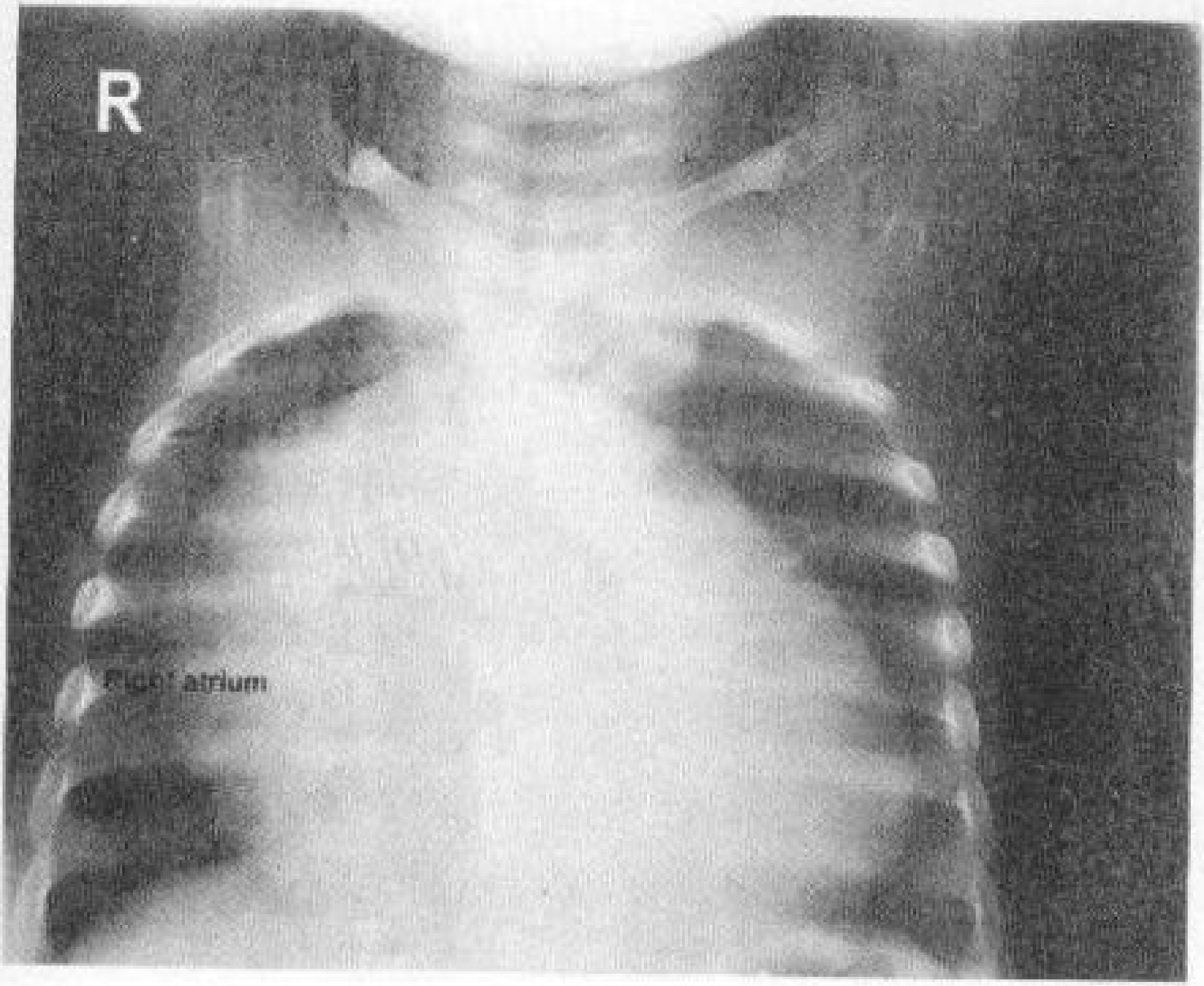

- Plain X ray chest and heart
- Postero-anterior view
- The patient is not centralized
- Costophrenic angles are free on both sides
- Cardio-thoracic ratio increased
- Cardiophrenic angle on the left side is acute (right ventricle)
- Marked bulge of the right border (right atrium)
- Narrow cardiac base (the aorta is displaced anteriorly)
- Increased pulmonary vascular markings

WhiteKnightLove

Freely you have received; freely give.

III- Abnormalities of the cardiac site

1- Isolated dextrocardia

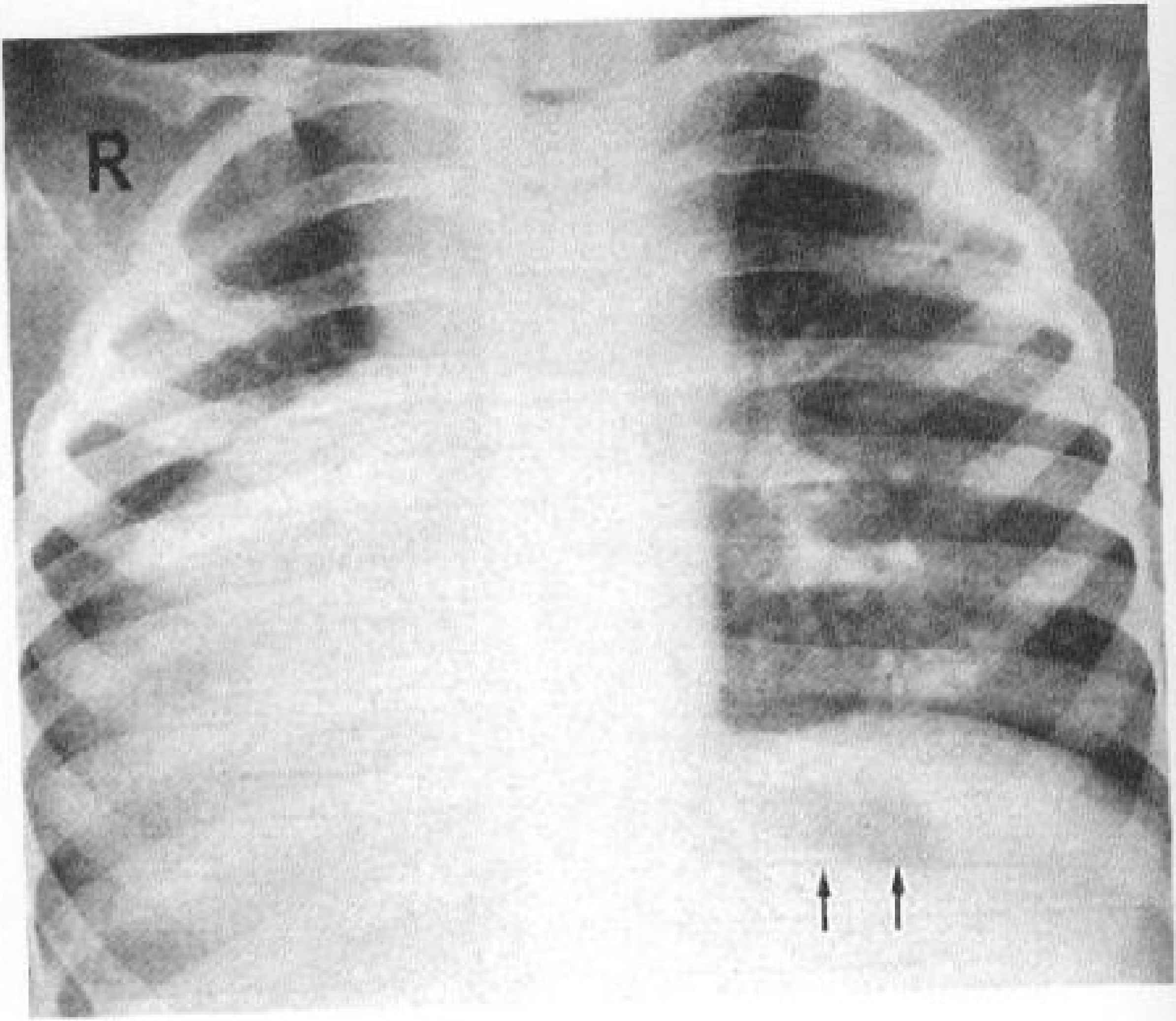

- Plain X ray chest and heart
- Postero-anterior view
- The patient is centralized
- Costophrenic angles are free on both sides
- Cardio-thoracic ratio is mildly increased

- Abnormal site of the heart
  . The heart lies mainly to the right side
  . The cardiac apex is on the right side
  . The left border is formed by right atrium while the right one is formed by pulmonary artery, left atrium and left ventricle
- The stomach is normal in site (gastric air bubbles on the left side)

WhiteKnightLove

2- Dextrocardia with situs inversus

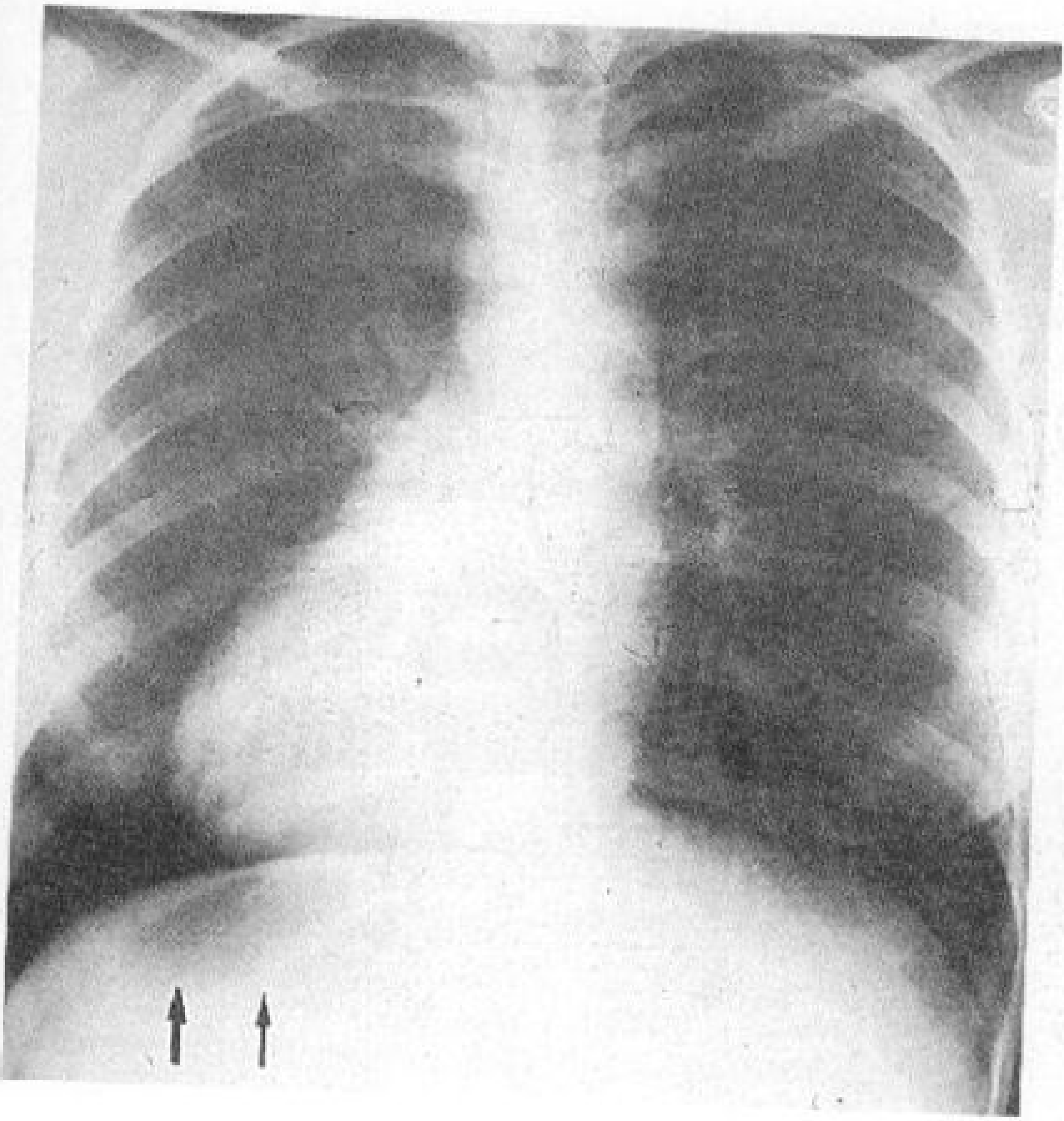

- Plain X ray chest and heart
- Postero-anterior view
- The patient is centralized
- Costophrenic angles are free on both sides
- Cardio-thoracic ratio is normal
- Abnormal site of the heart
  - . The heart lies mainly to the right side
  - . The cardiac apex is on the right side
  - . The left border is formed by right atrium while the right one is formed by pulmonary artery, left atrium and left ventricle
- Abnormal position of the stomach and liver (gastric air bubbles on the right side while the liver shadow is on the left side)

WhiteKnightLove

Freely you have received; freely give.

Normal chest X ray

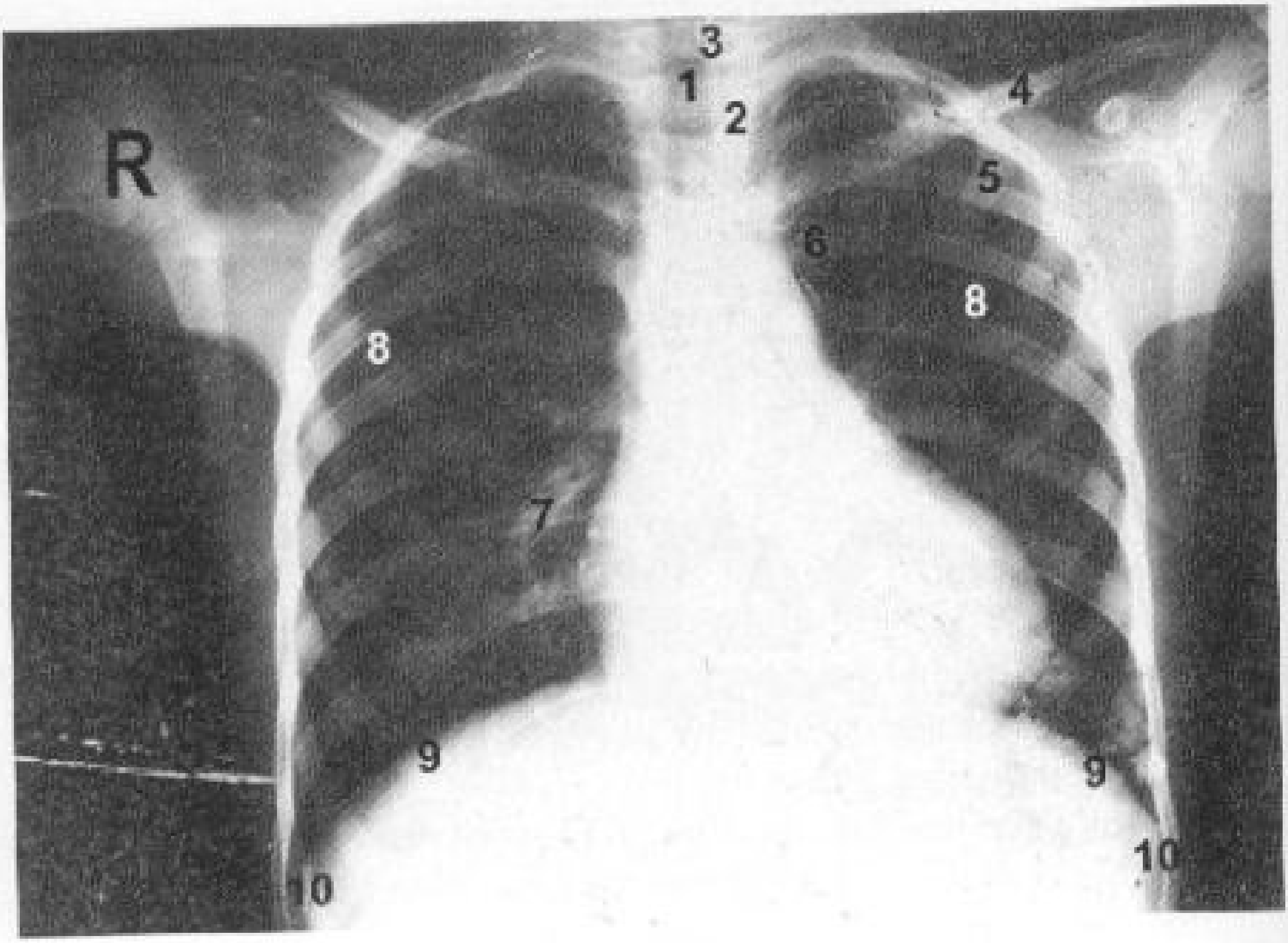

1- Tracheal air column
2- Vertebral column
3- Spinous processes of the vertebrae
4- Clavicles
5- Anterior ribs
6- Posterior ribs
7- Bronchovascular markings
8- Lung fields
9- Diaphragmatic copulae
10- Costophrenic angles

WhiteKnightLove

1- Pleural effusion

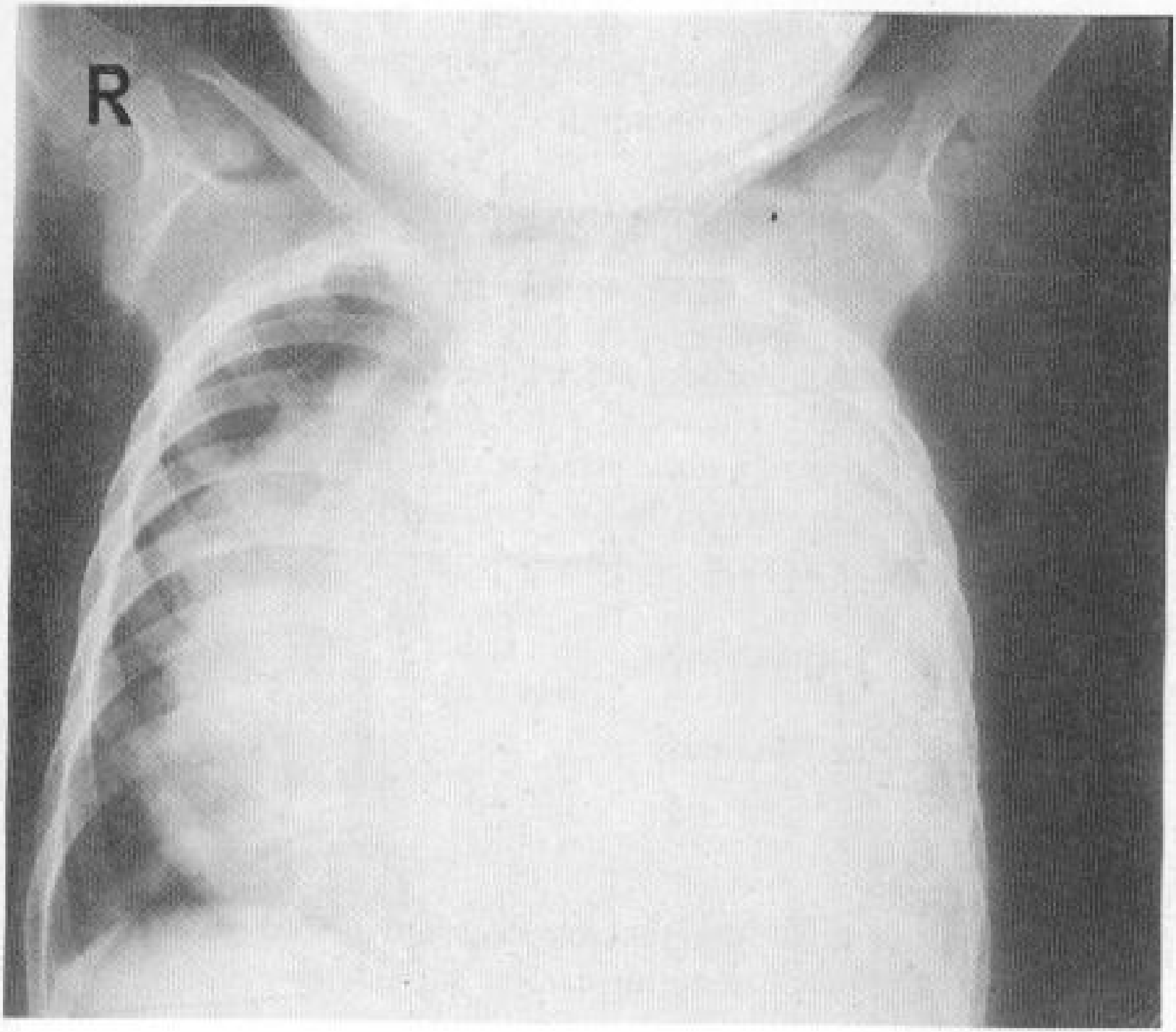

- Plain X ray chest and heart
- Postero-anterior view
- The patient is centralized
- Costophrenic angle on the right side is free,
- Costophrenic angle on the left side is obliterated by homogenous opacity occupying all the left hemithorax.
- The mediastinum is shifted to the opposite side of the lesion

Left side massive pleural effusion

WhiteKnightLove

Freely you have received; freely give.

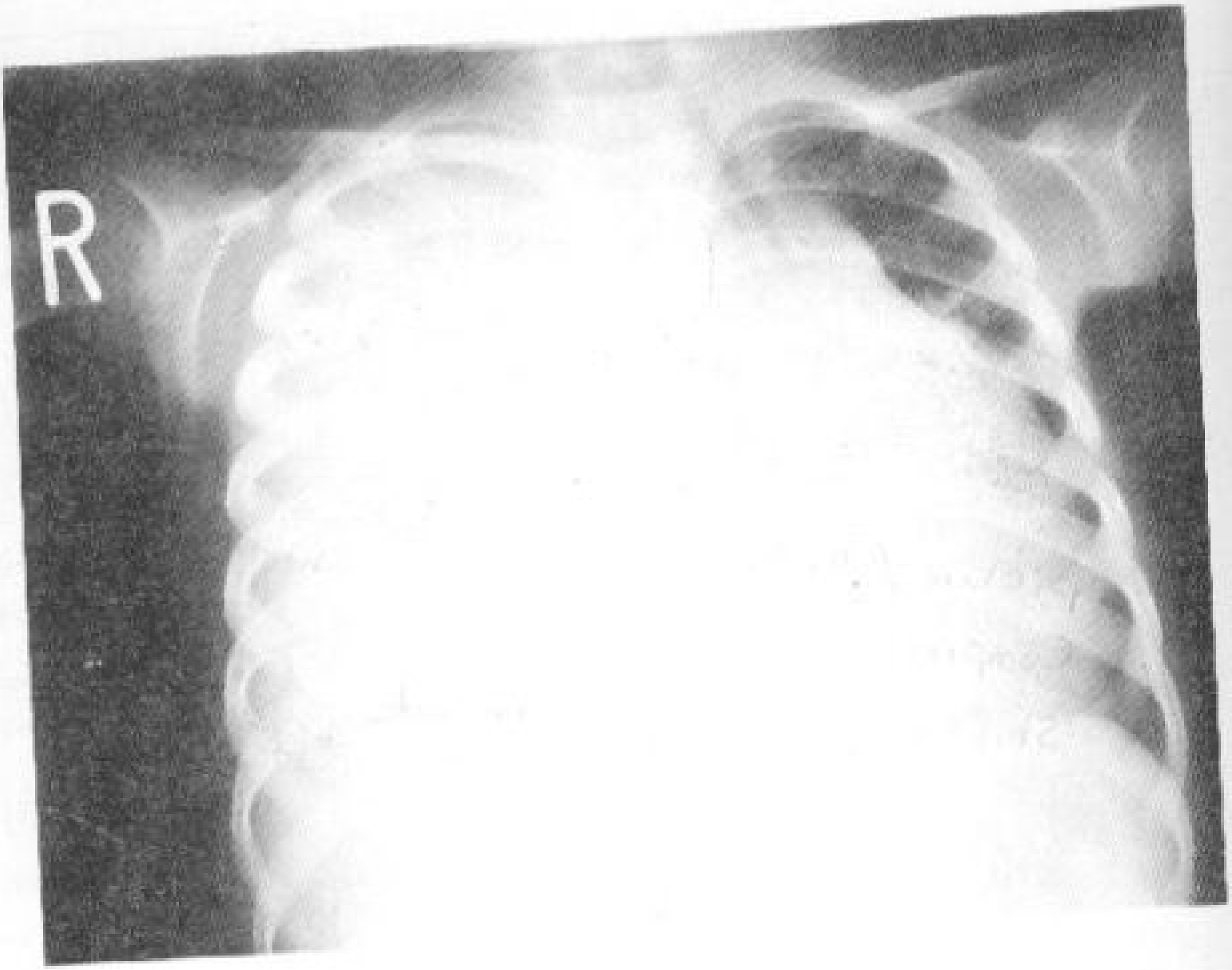

- Plain X ray chest and heart
- Postero-anterior view
- The patient is centralized
- Costophrenic angle on the left side is free
- The right costophrenic angle is obliterated by homogenous opacity occupying all the right hemithorax
- The mediastinum is shifted to the opposite side of the lesion

Right side massive pleural effusion

WhiteKnightLove

'It is more blessed to give than to receive.

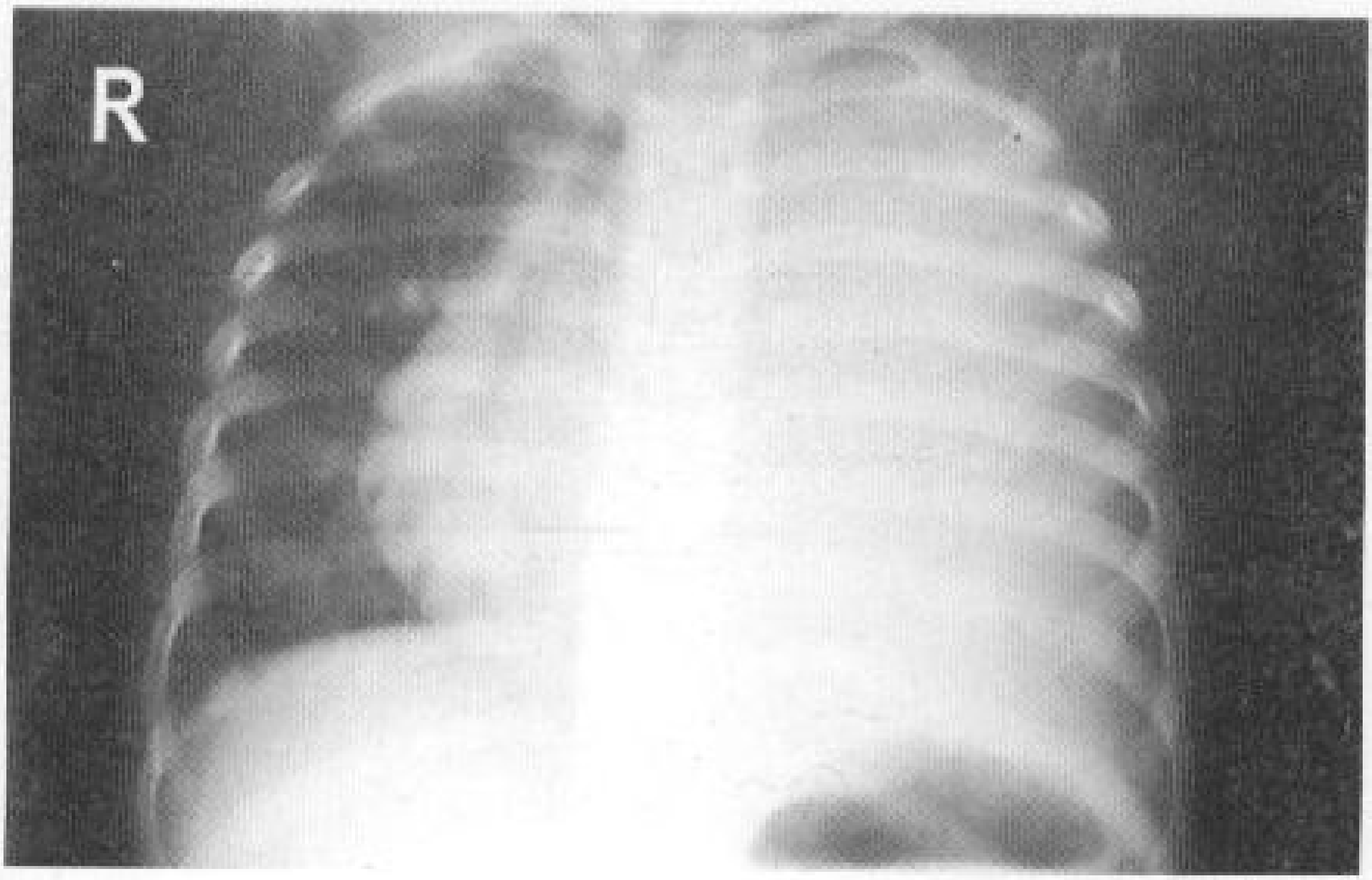

- Plain X ray chest and heart
- Postero-anterior view
- The patient is centralized
- The right costophrenic angle is free
- The left costophrenic angle is obliterated by homogenous opacity occupying all the left hemithorax
- The mediastinum is shifted to the opposite side of the lesion

<u>Left side massive pleural effusion</u>

WhiteKnightLove

Freely you have received; freely give.

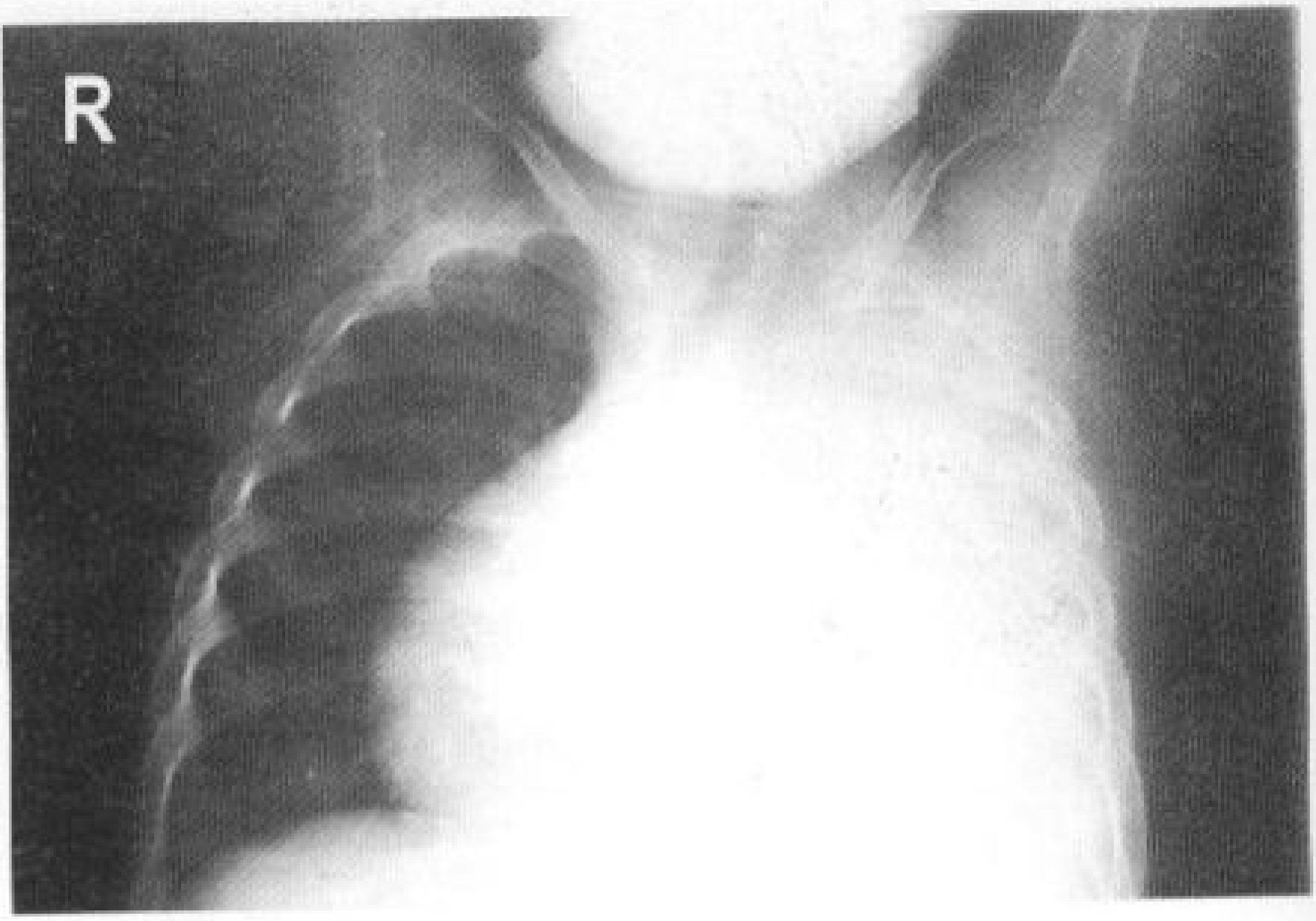

- Plain X ray chest and heart
- Postero-anterior view
- The patient is centralized
- The right costophrenic angle is free
- The left costophrenic is obliterated by homogenous opacity occupying all the left hemithorax
- The mediastinum is shifted to the opposite side of the lesion

Left side massive pleural effusion

WhiteKnightLove

'It is more blessed to give than to receive.

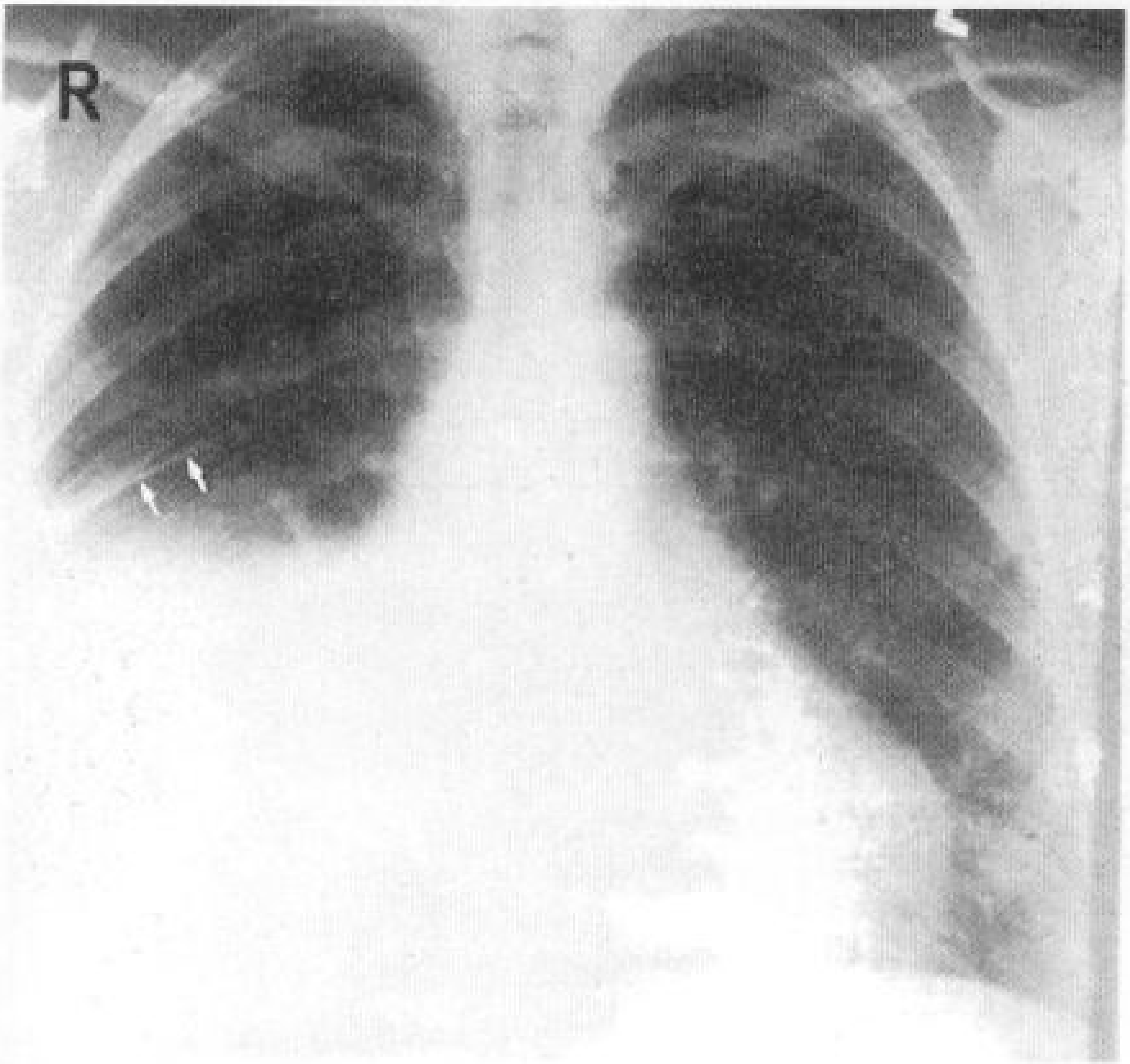

- Plain X ray chest and heart
- Postero-anterior view
- The patient is centralized
- Costophrenic angle on the left side is free.
- Costophrenic angle on the right side is obliterated by homogenous opacity with concave upper border (raising to the axilla)
- The mediastinum is shifted to the opposite side of the lesion

Right side moderate pleural effusion

WhiteKnightLove

Freely you have received; freely give.

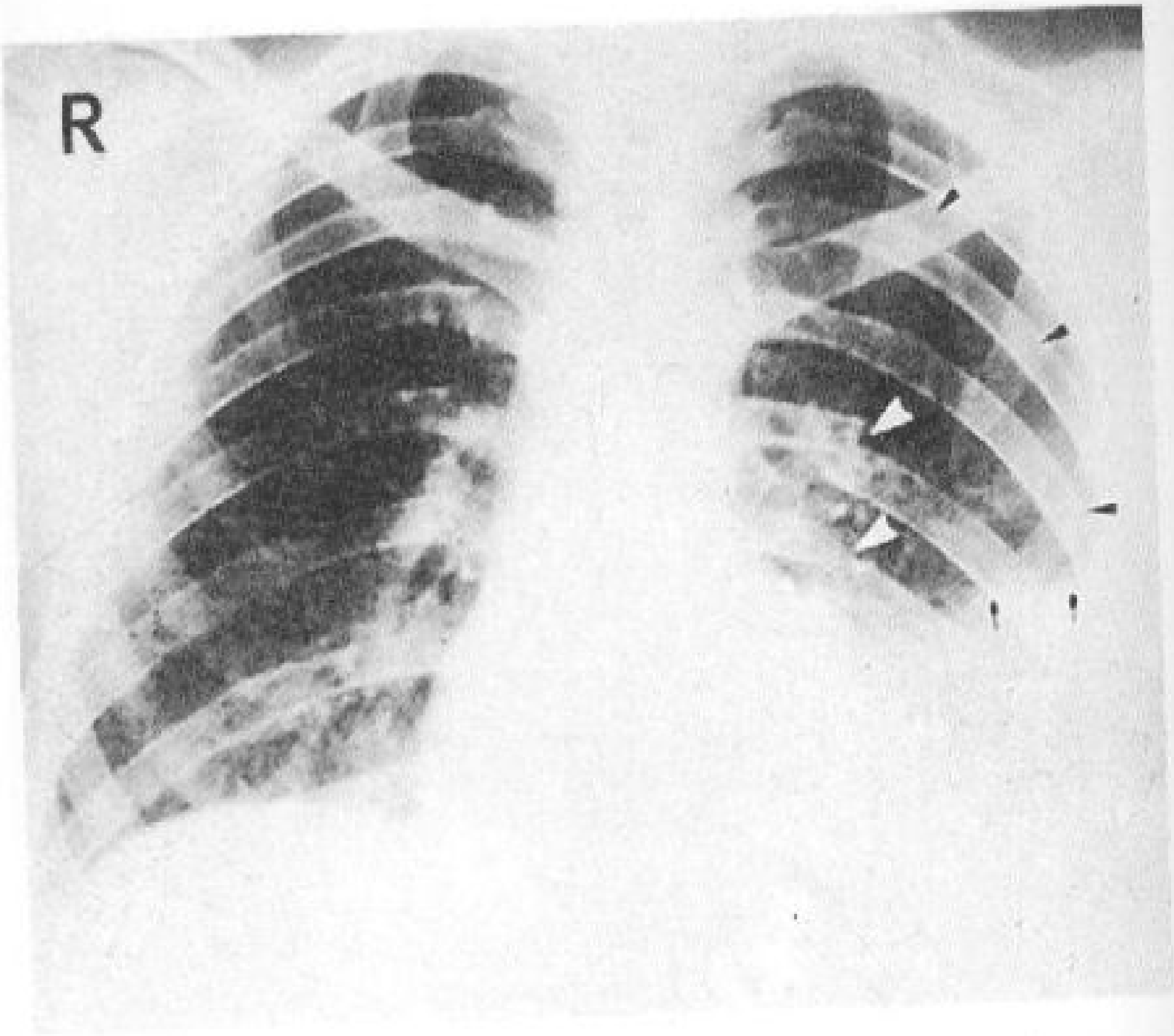

- Plain X ray chest and heart
- Postero-anterior view
- The patient is not centralized
- Costophrenic angle on the right side is free
- Costophrenic angle on the left side is obliterated by homogenous opacity with concave upper border raising to the axilla
- The mediastinum is shifted to the opposite side of the lesion. There is rib fractures (the arrows) due to chest trauma

Left side moderate pleural effusion (hemothorax)

WhiteKnightLove

'It is more blessed to give than to receive.

2- Lobar pneumonia

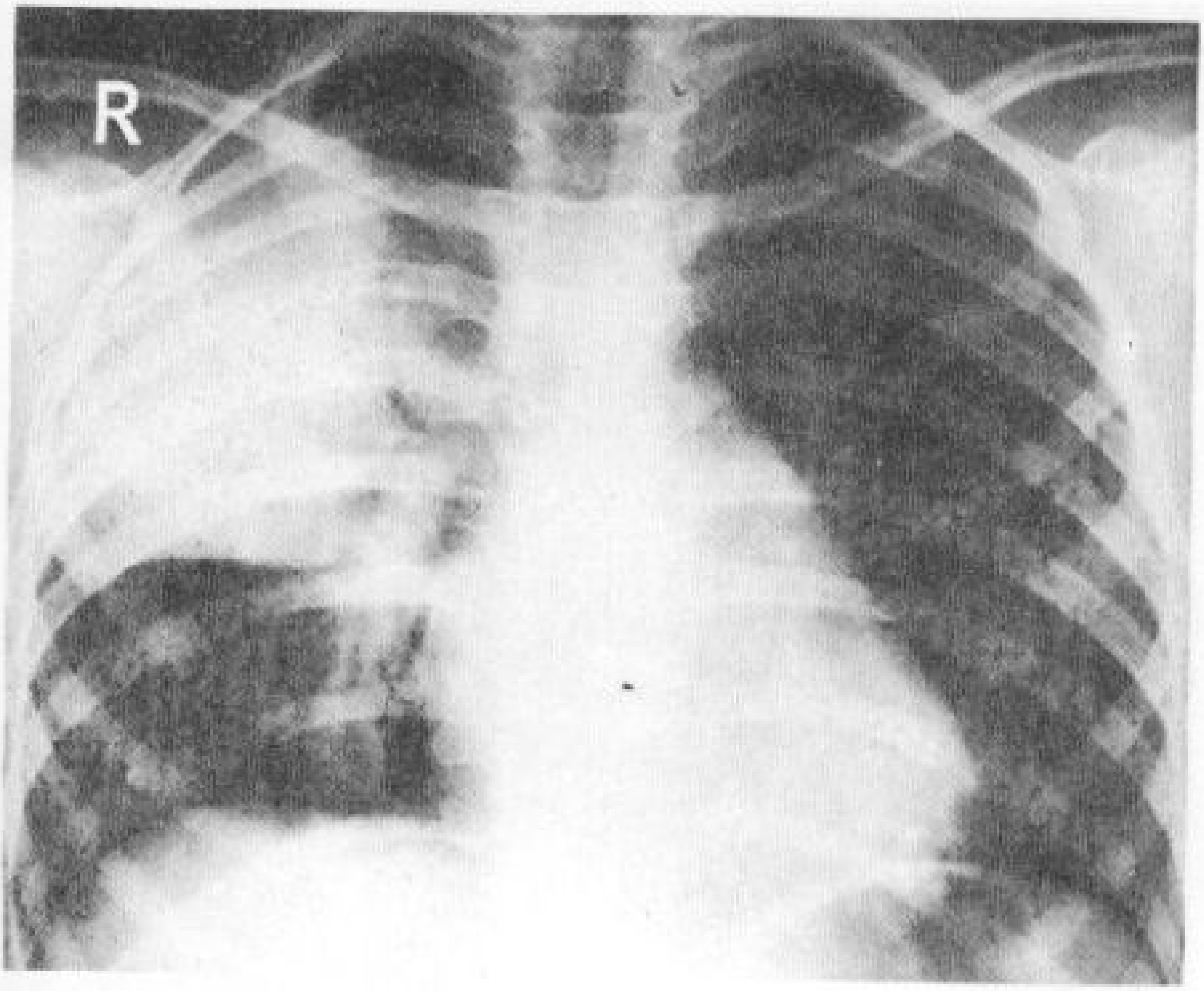

- Plain X ray chest and heart
- Postero-anterior view
- The patient is centralized
- Costophrenic angles are free on both sides
- There is homogenous opacity on the upper and middle zone of the right lung
- Central mediastinum

Right side lobar pneumonia

Causes of lobar pneumonia

- The most important: -pneumococci
- Other organism: - TB-Klebsiella-H.influenza

WhiteKnightLove

Freely you have received; freely give.

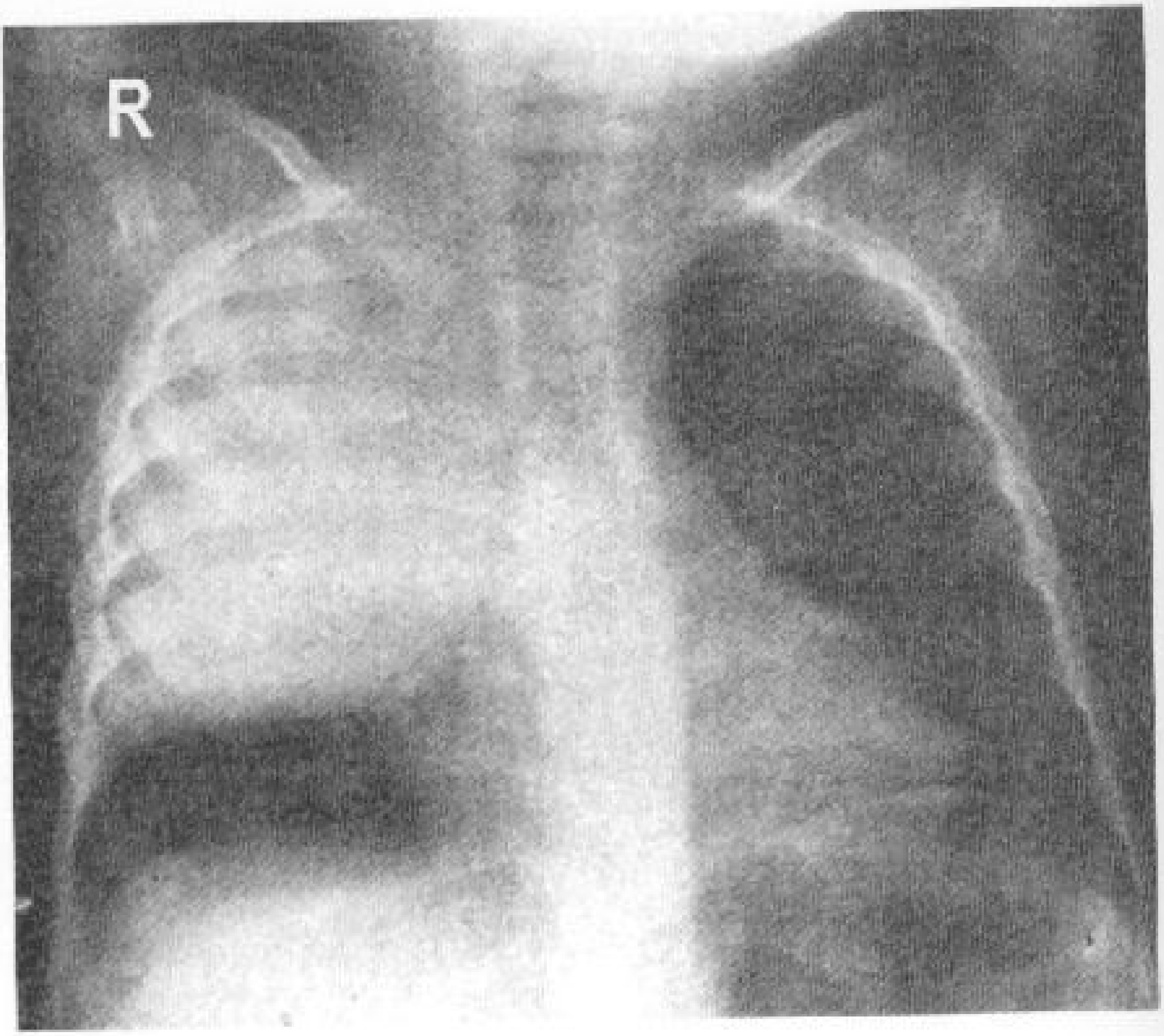

- Plain X ray chest and heart
- Postero-anterior view
- The patient is centralized
- Costophrenic angles are free on both sides
- There is homogenous opacity on the upper and middle zone of the right lung
- Central mediastinum

Right side lobar pneumonia

WhiteKnightLove

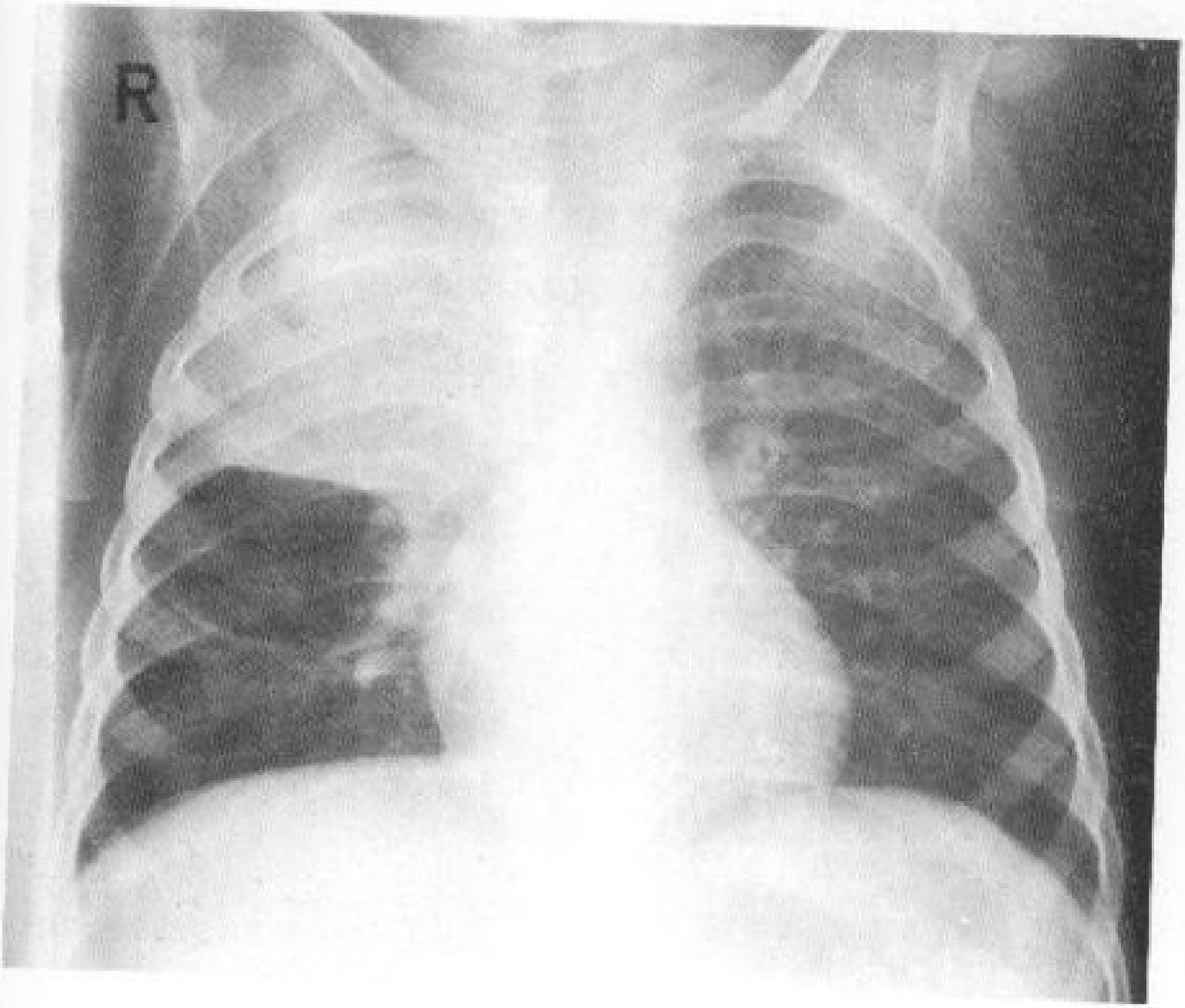

- Plain X ray chest and heart
- Postero-anterior view
- The patient is not centralized
- Costophrenic angles are free on both sides
- There is homogenous opacity on the upper and middle zone of the right lung
- Central mediastinum

Right side lobar pneumonia

WhiteKnightLove

Freely you have received; freely give.

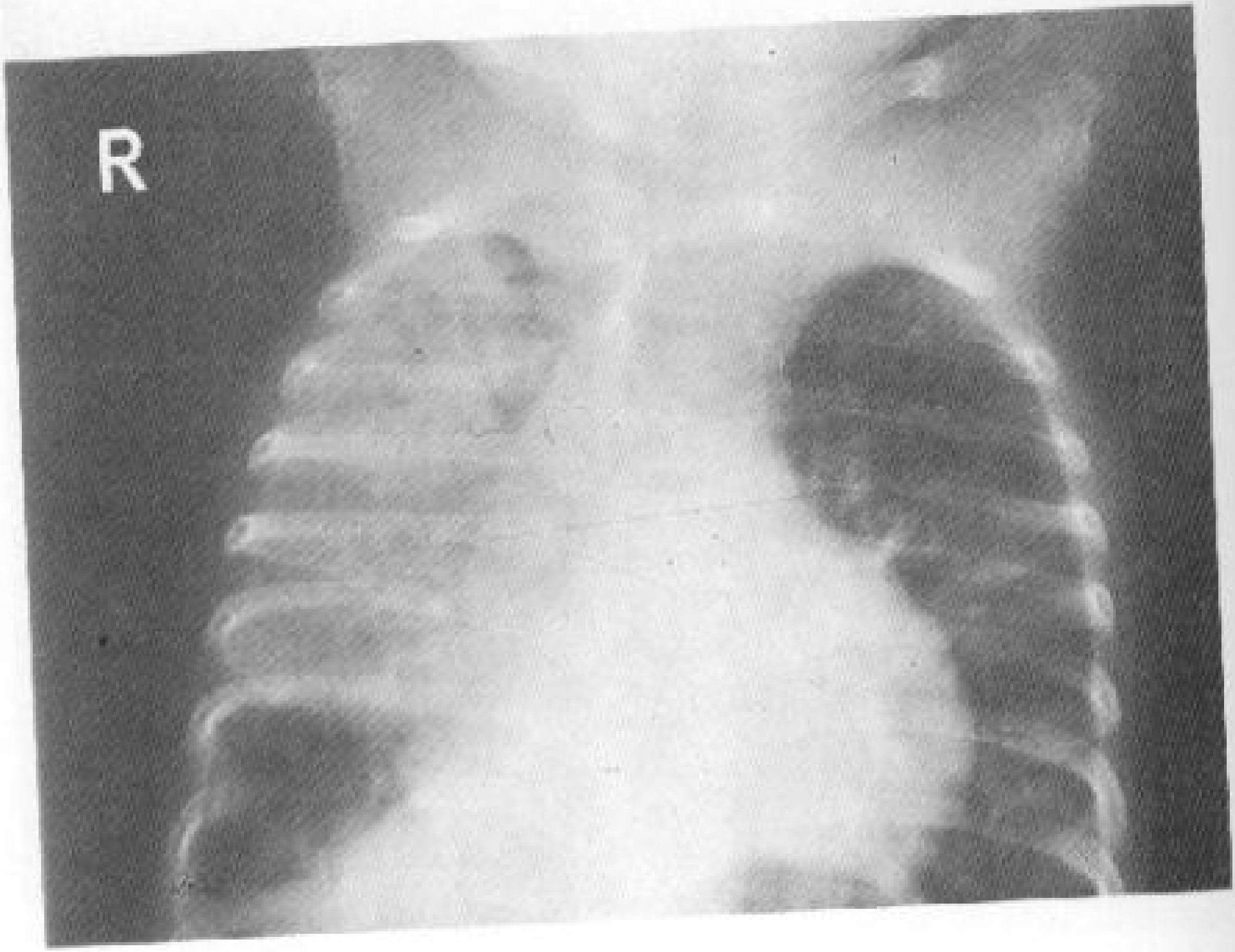

- Plain X ray chest and heart
- Postero-anterior view
- The patient is not centralized
- Costophrenic angles are free on both sides
- There is heterognous opacity on the upper and middle zone of th[e] right lung
- Central mediastinum

Right side lobar pneumonia (on resolution)

WhiteKnightLove

'It is more blessed to give than to receive.

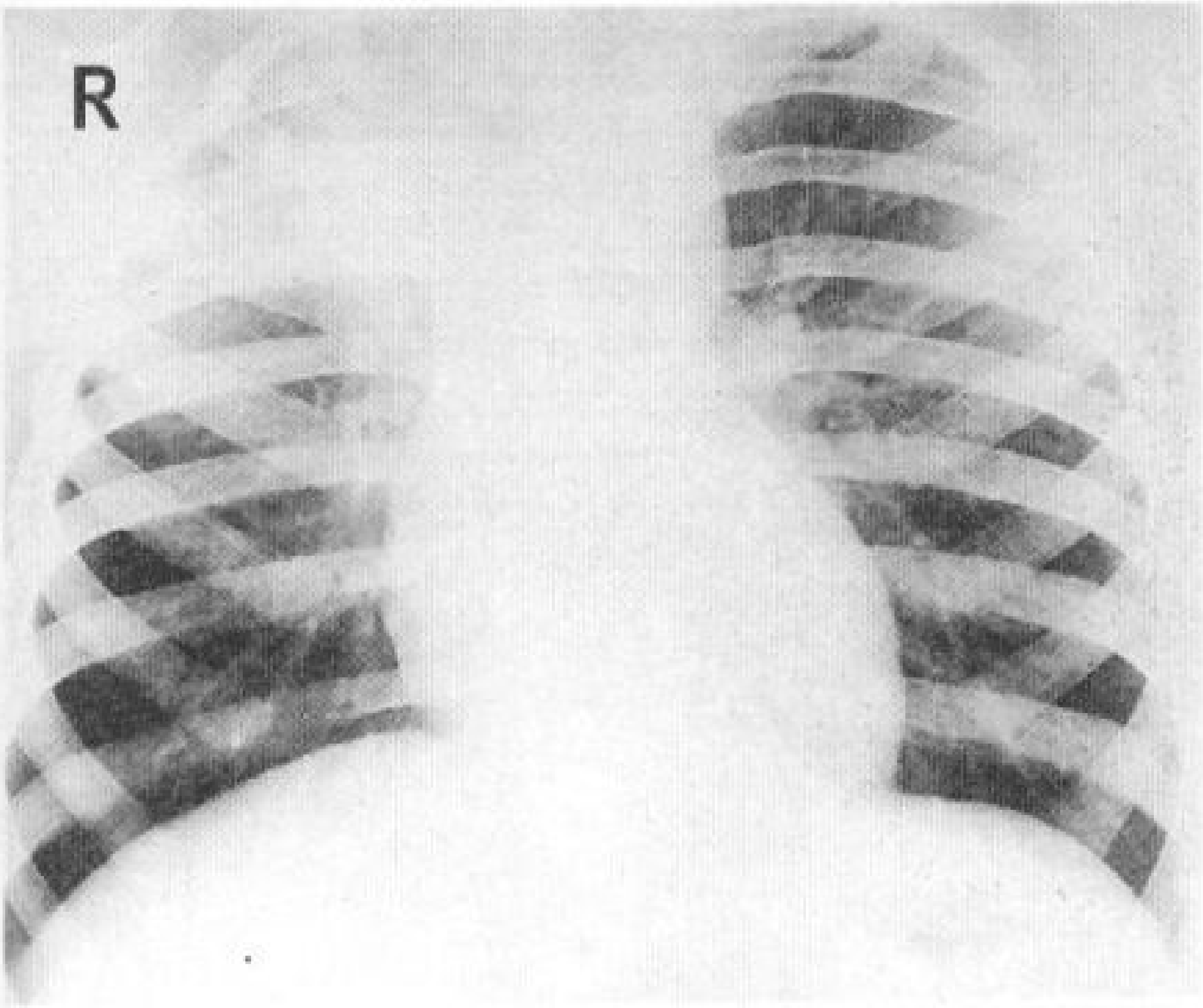

- Plain X ray chest and heart
- Postero-anterior view
- The patient is centralized
- Costophrenic angles are free on both sides
- There is homogenous opacity on the upper zone of the right lung
- Central mediastinum

<u>Right side lobar pneumonia affecting the upper lobe</u>

WhiteKnightLove

Freely you have received; freely give.

3- Lung fibrosis

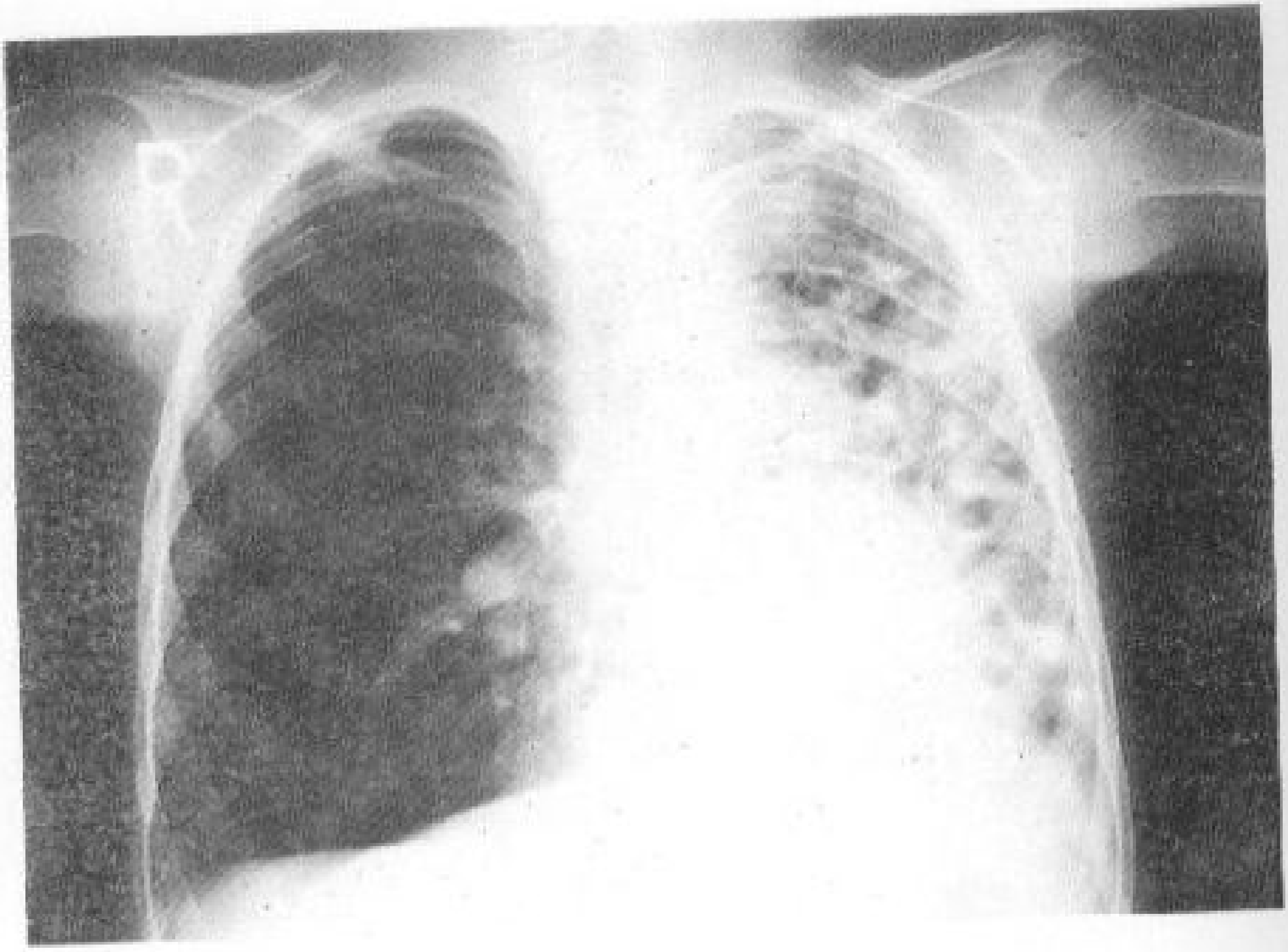

- Plain X ray chest and heart
- Postero-anterior view
- The patient is centralized
- There is heterogeneous opacity occupying most of the left lung
- The mediastinum is shifted to the same side of the lesion

Left side massive fibrosis

Causes of lung fibrosis

- Tuberculosis
- Emyema (improperly drained)
- Bronchiectasis

WhiteKnightLove

'It is more blessed to give than to receive.

4- Lung collapse

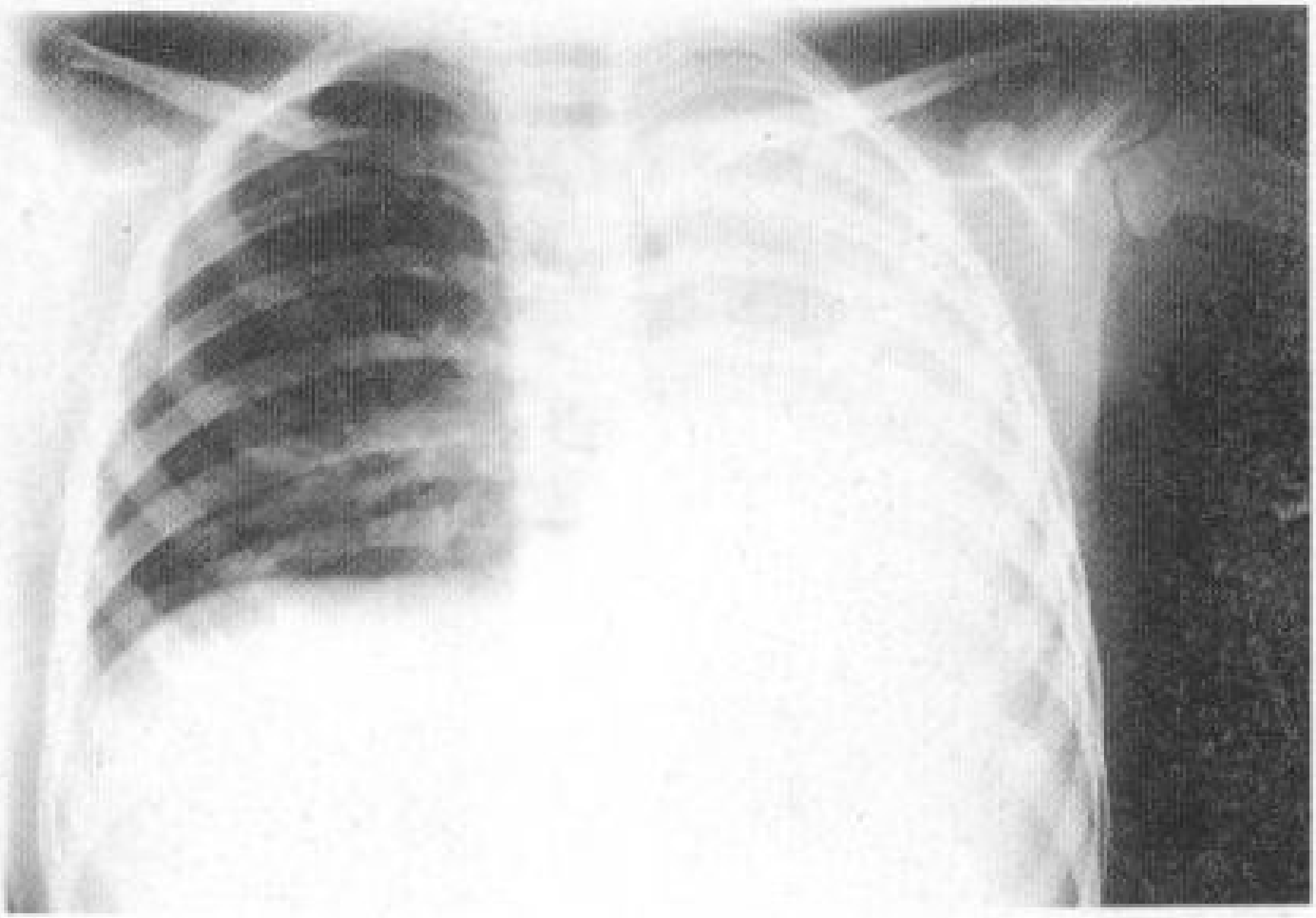

- Plain X ray chest and heart
- Postero-anterior view
- The patient is centralized
- Costophrenic angles are free on both sides
- There is homogenous opacity occupying all the left hemithorax
- The mediastinum is shifted to the same side of the lesion

Left side massive collapse

Causes of lung collapse

- Intrabronchial obstruction :- foreign body- mucous plug- granuloma (TB) Treated by bronchoscopic removal
- External compression: Enlarged lymph nodes- tumor

WhiteKnightLove

Freely you have received; freely give.

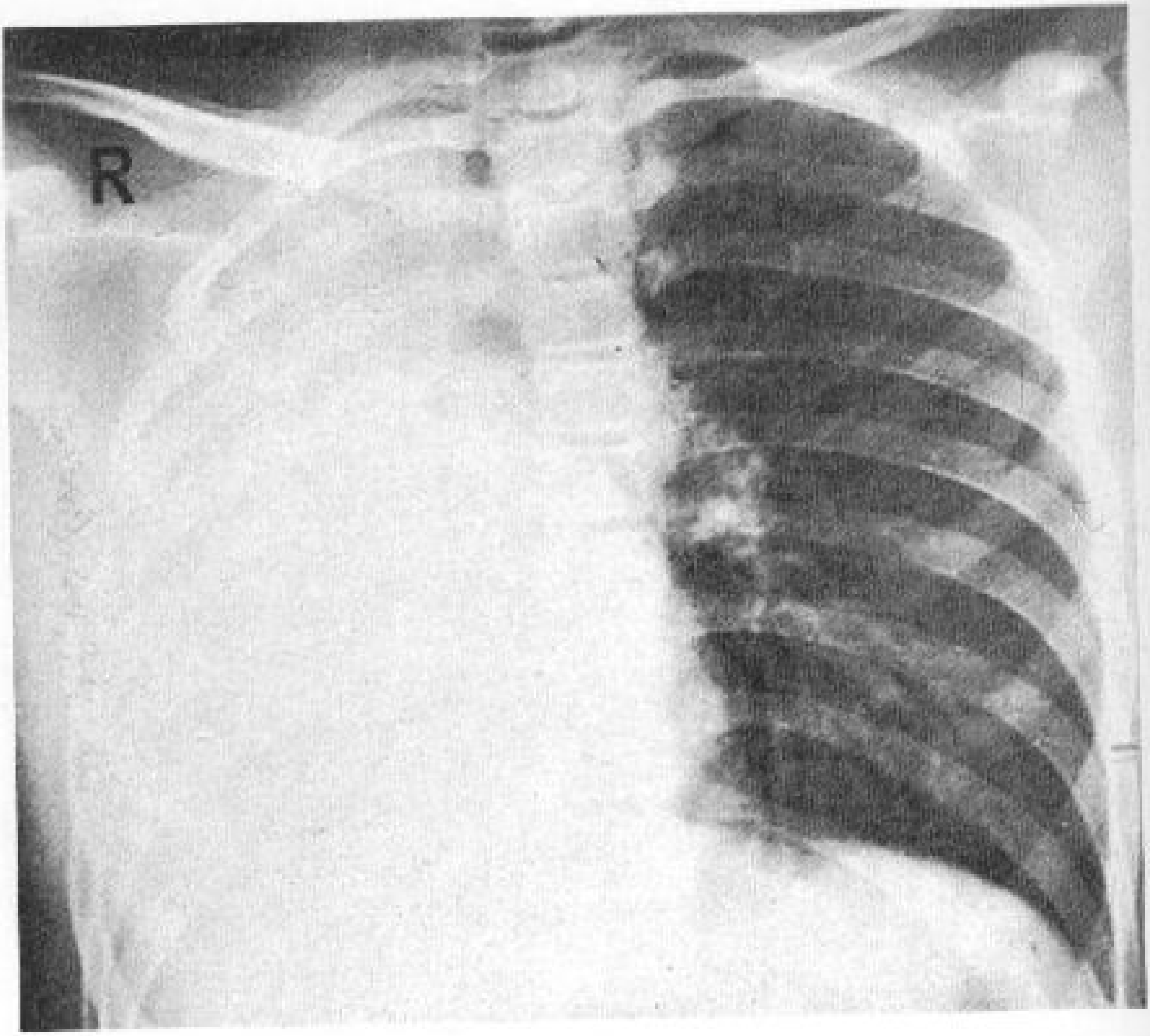

- Plain X ray chest and heart
- Postero-anterior view
- The patient is centralized
- Costophrenic angles are free on both sides
- There is homogenous opacity occupying all the right hemithorax
- The mediastinum is shifted to the same side of the lesion

Right side massive collapse

WhiteKnightLove

Lobar collpase

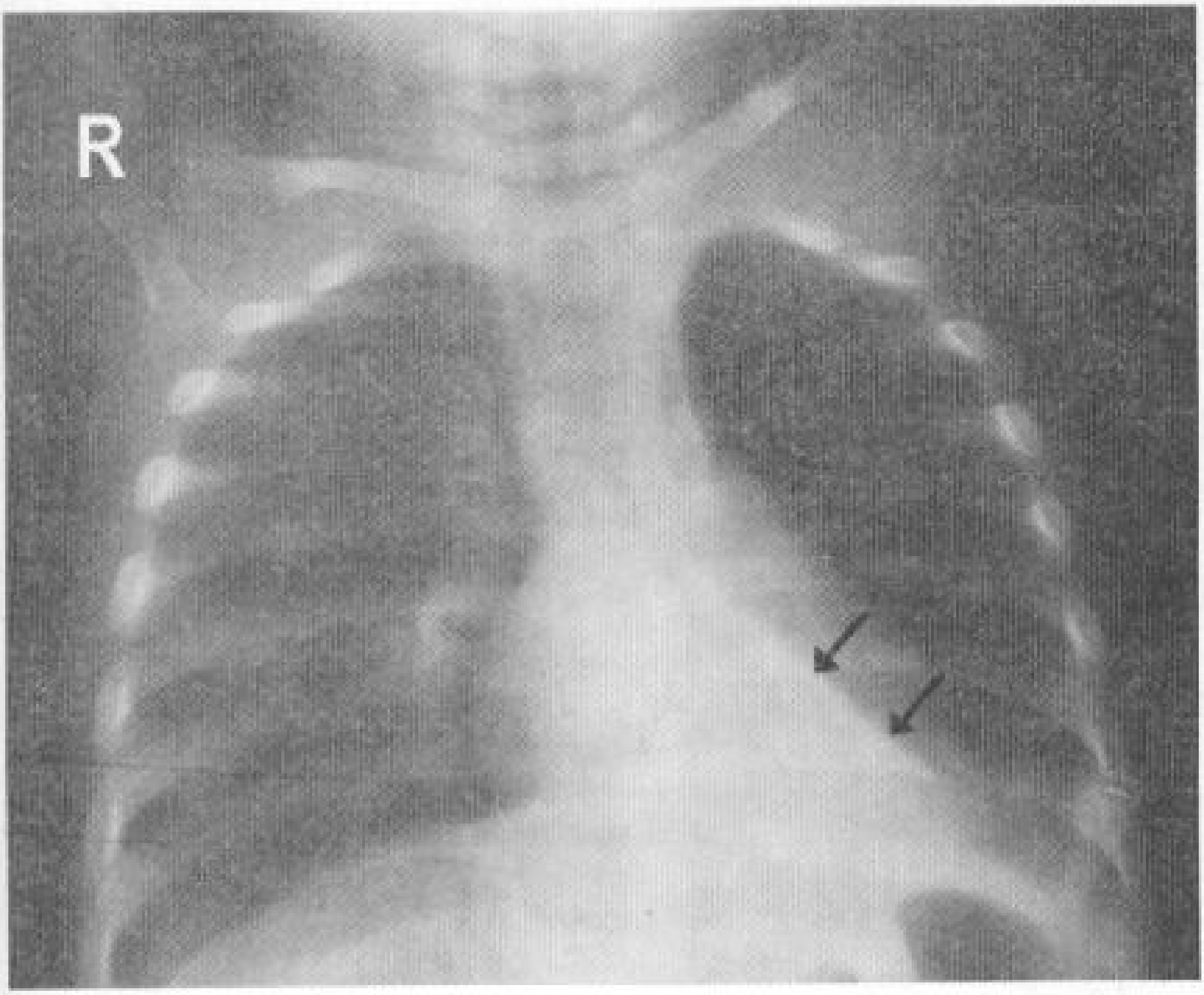

- Plain X ray chest and heart
- Postero-anterior view
- The patient is not centralized
- Costophrenic angles are free on both sides
- There is homogenous opacity on the left side (the arrows)
  Triangular in shape with
  Sharp upper border,
  Rretrocardic in position (behind the cardiac shadow)
- The upper lobe of the left lung is more translucent (compensatory emphysema)

Left lower lobe collapse

WhiteKnightLove

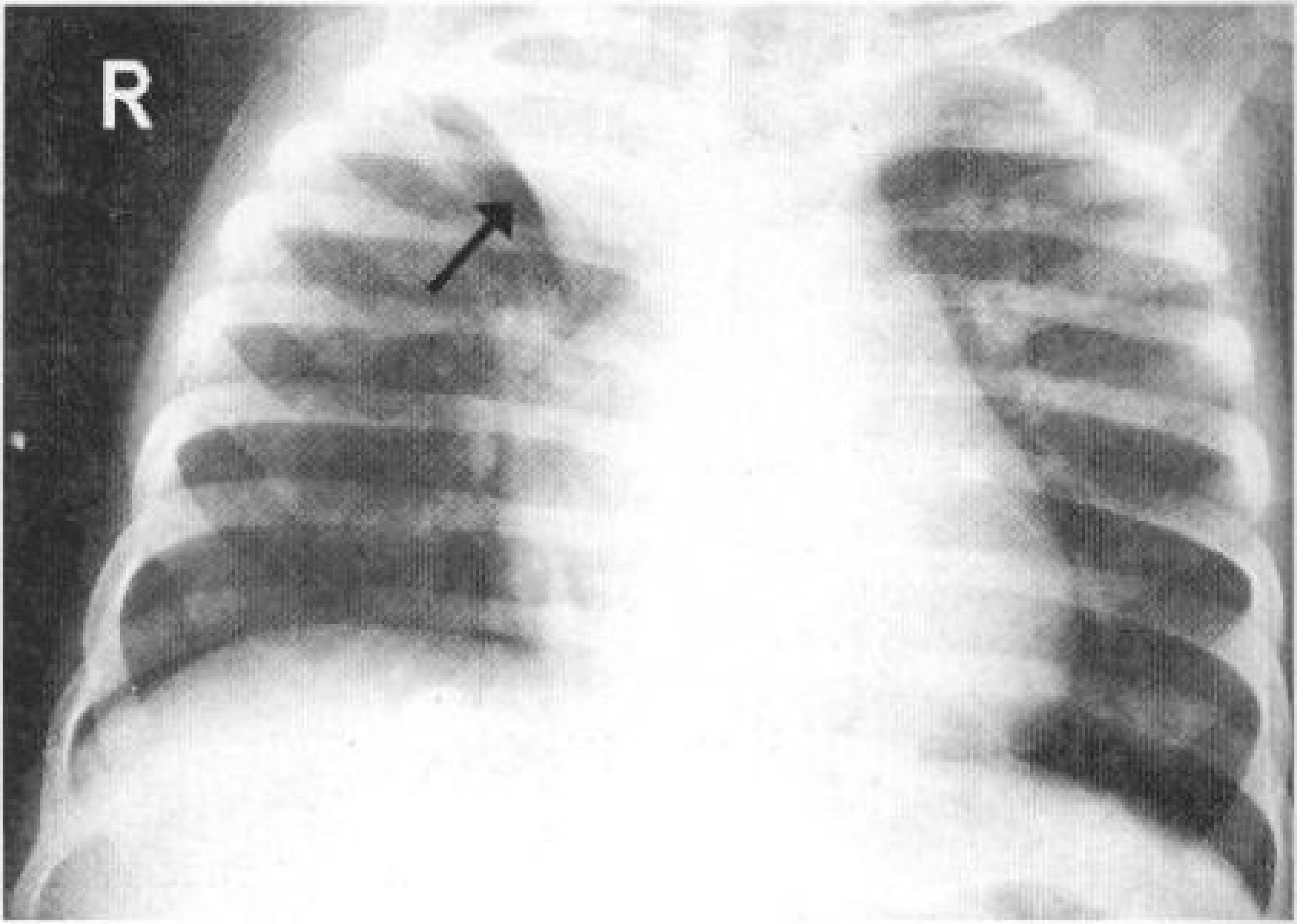

- Plain X ray chest and heart
- Postero-anterior view
- The patient is not centralized
- Costophrenic angles are free on both sides

- There is homogenous opacity on the right side (the arrows)
  Triangular in shape with
  Concave sharp lower border,

Right upper lobe collapse

WhiteKnightLove

'It is more blessed to give than to receive.

1- Miliary shadows

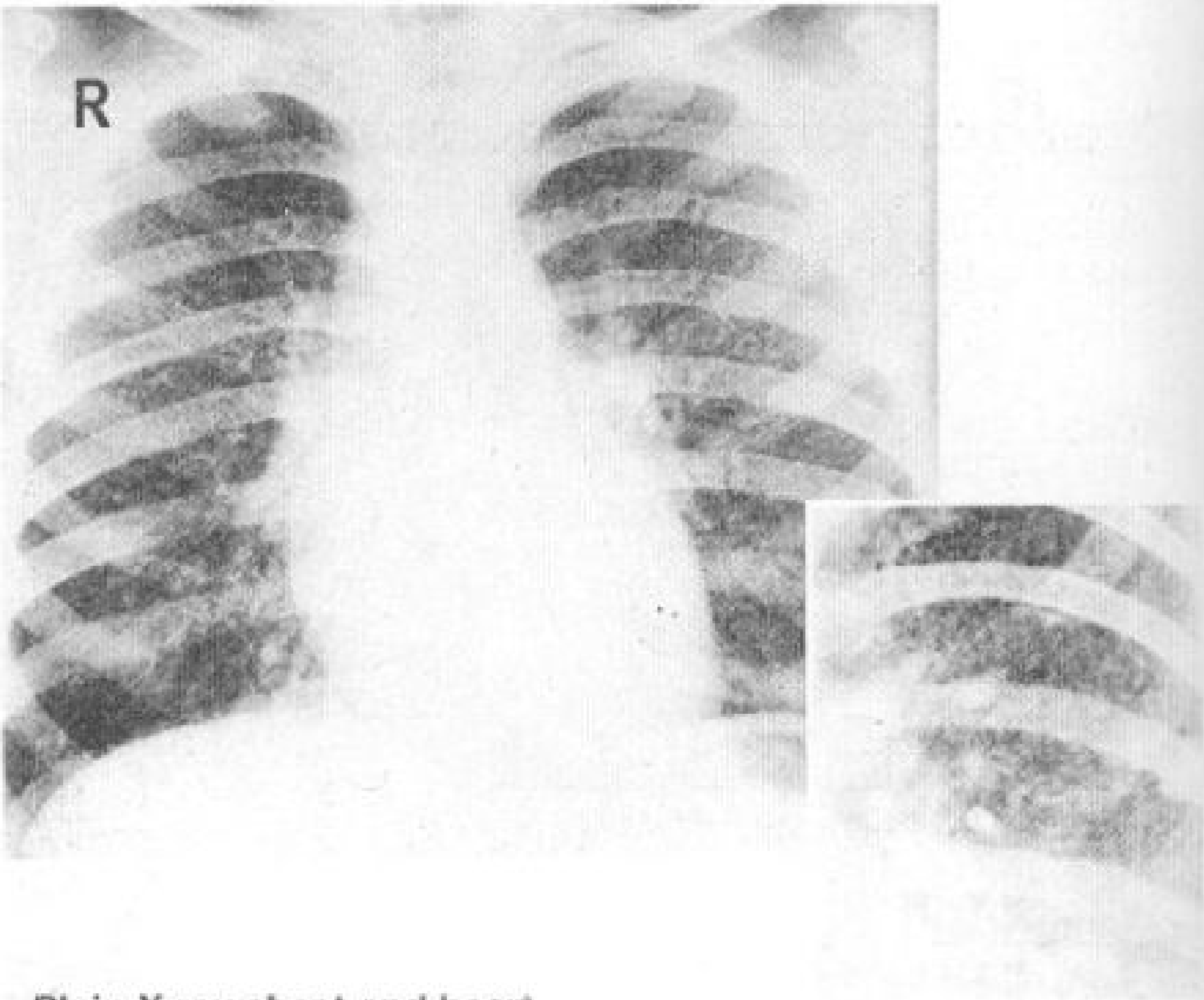

- Plain X ray chest and heart
- Postero-anterior view
- The patient is centralized
- Costophrenic angles are free on both sides
- There are multiple small lesions with well defined outline distributed on both lung fields
- Central mediastinum

Miliary shadows for differential diagnosis

Causes

- Tuberculosis
- Toxoplasmosis
- Histocytosis
- Hemosidrosis
- Viral pneumonia

WhiteKnightLove

Freely you have received; freely give.

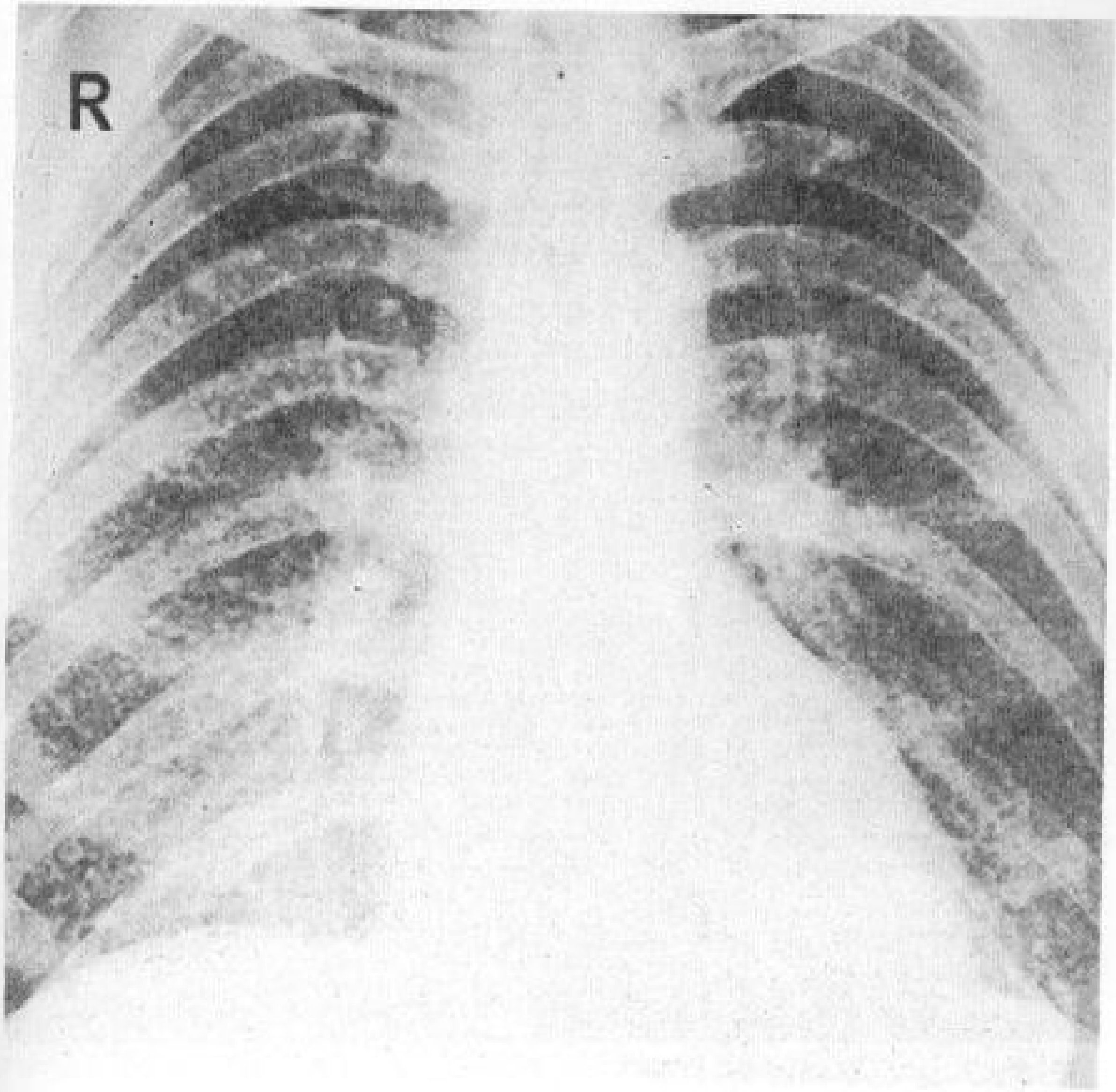

- Plain X ray chest and heart
- Postero-anterior view
- The patient is centralized
- Costophrenic angles are free on both sides
- There are multiple small lesions with well defined outline distributed on both lung fields
- Central mediastinum

Miliary shadows for differential diagnosis

WhiteKnightLove

'It is more blessed to give than to receive.

2- Bronchopneumonia

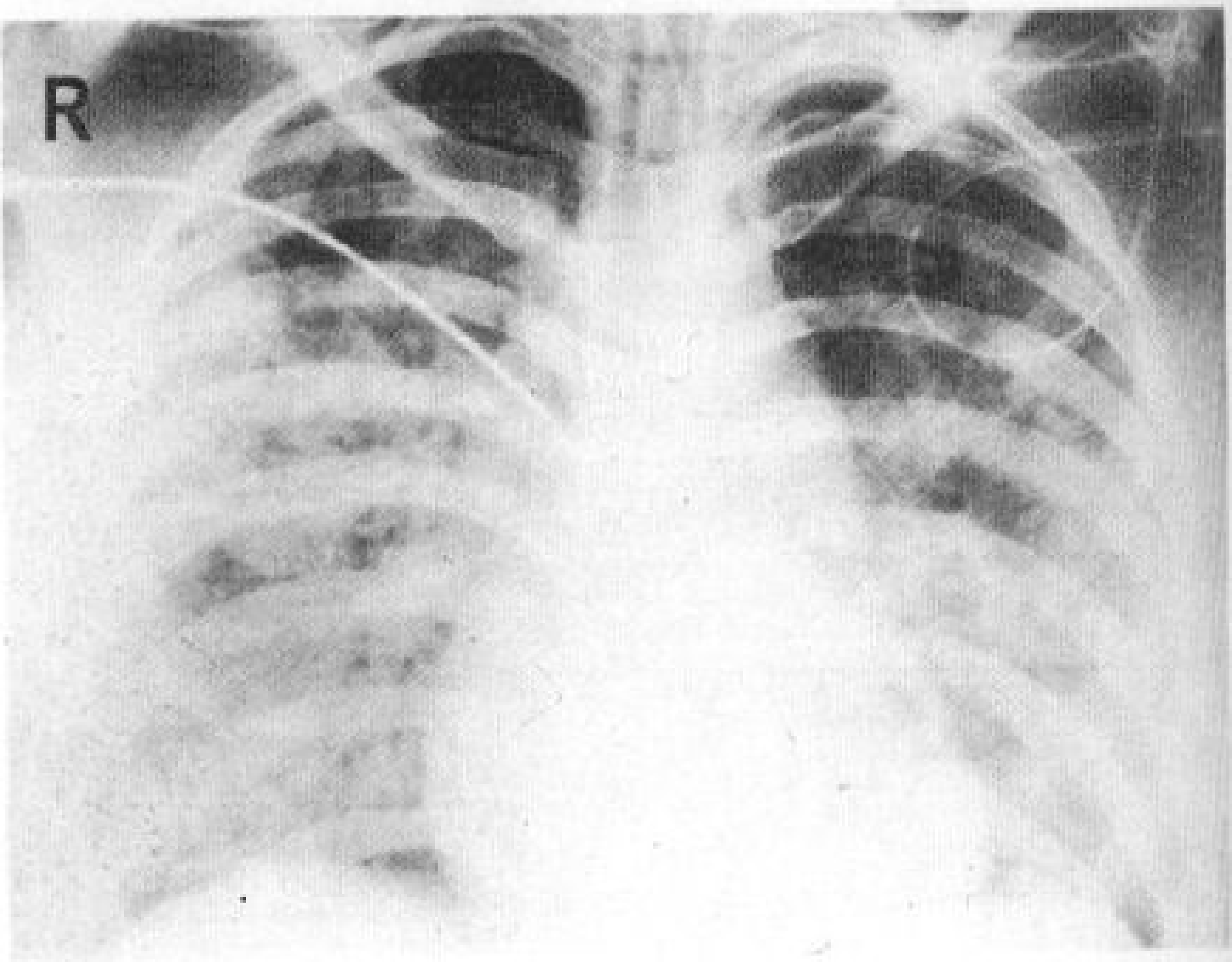

- Plain X ray chest and heart
- Postero-anterior view
- The patient is centralized
- Costophrenic angles are free on both sides
- There are multiple patches with ill-defined outline distributed on both lung fields
- Central mediastinum

Causes of bronchopneumonia

. Streptococci
. Klebsiella
. Hemophilus Influenza
. Staphylococci
. T.B

WhiteKnightLove

Freely you have received; freely give.

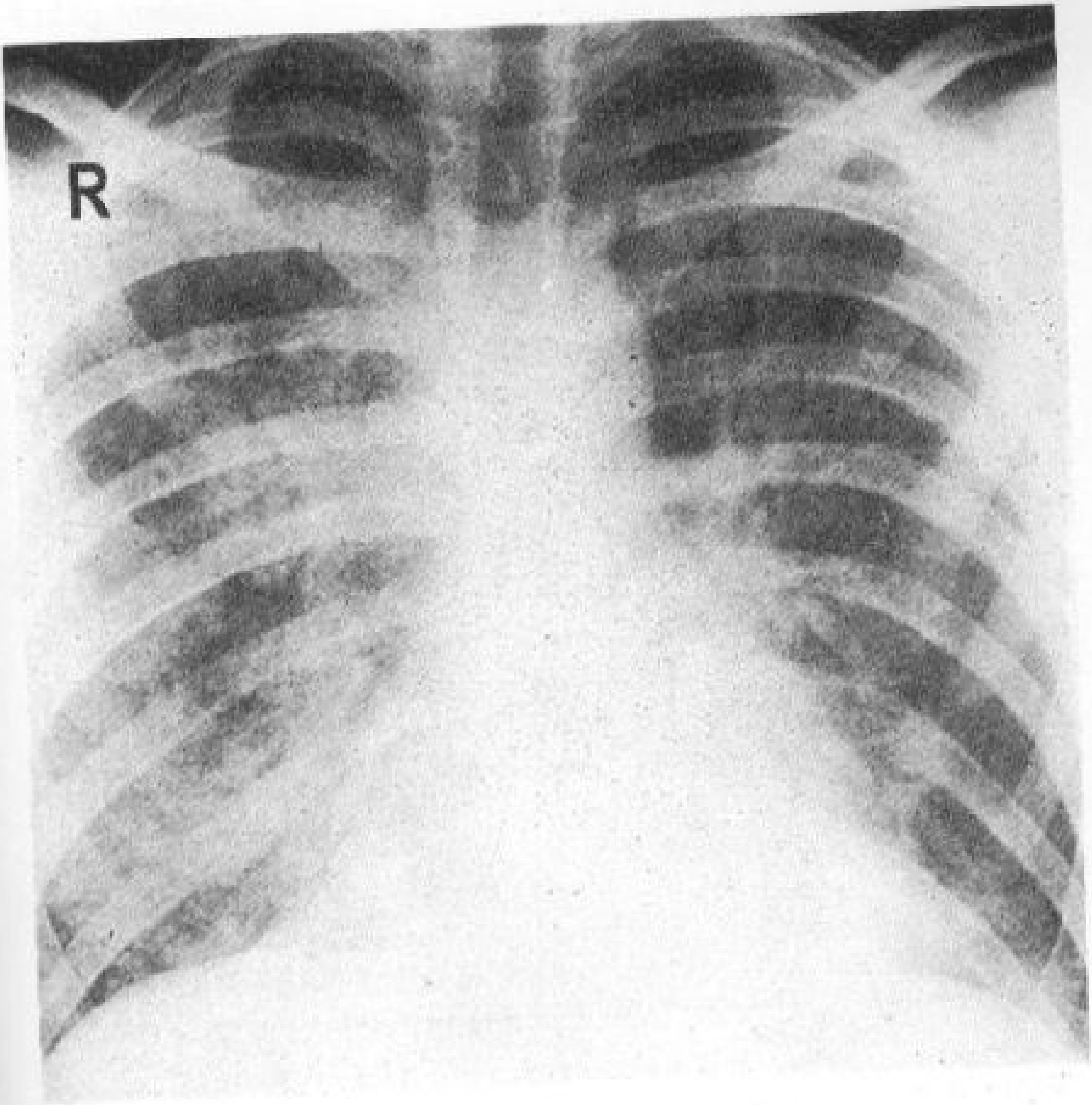

- Plain X ray chest and heart
- Postero-anterior view
- The patient is centralized
- Costophrenic angles are free on both sides
- There are multiple patches with ill-defined outline distributed on both lung fields (more marked on the right lung)
- Central mediastinum

<u>Bronchopneumonia</u>

WhiteKnightLove

'It is more blessed to give than to receive.

3- Bronchiectasis

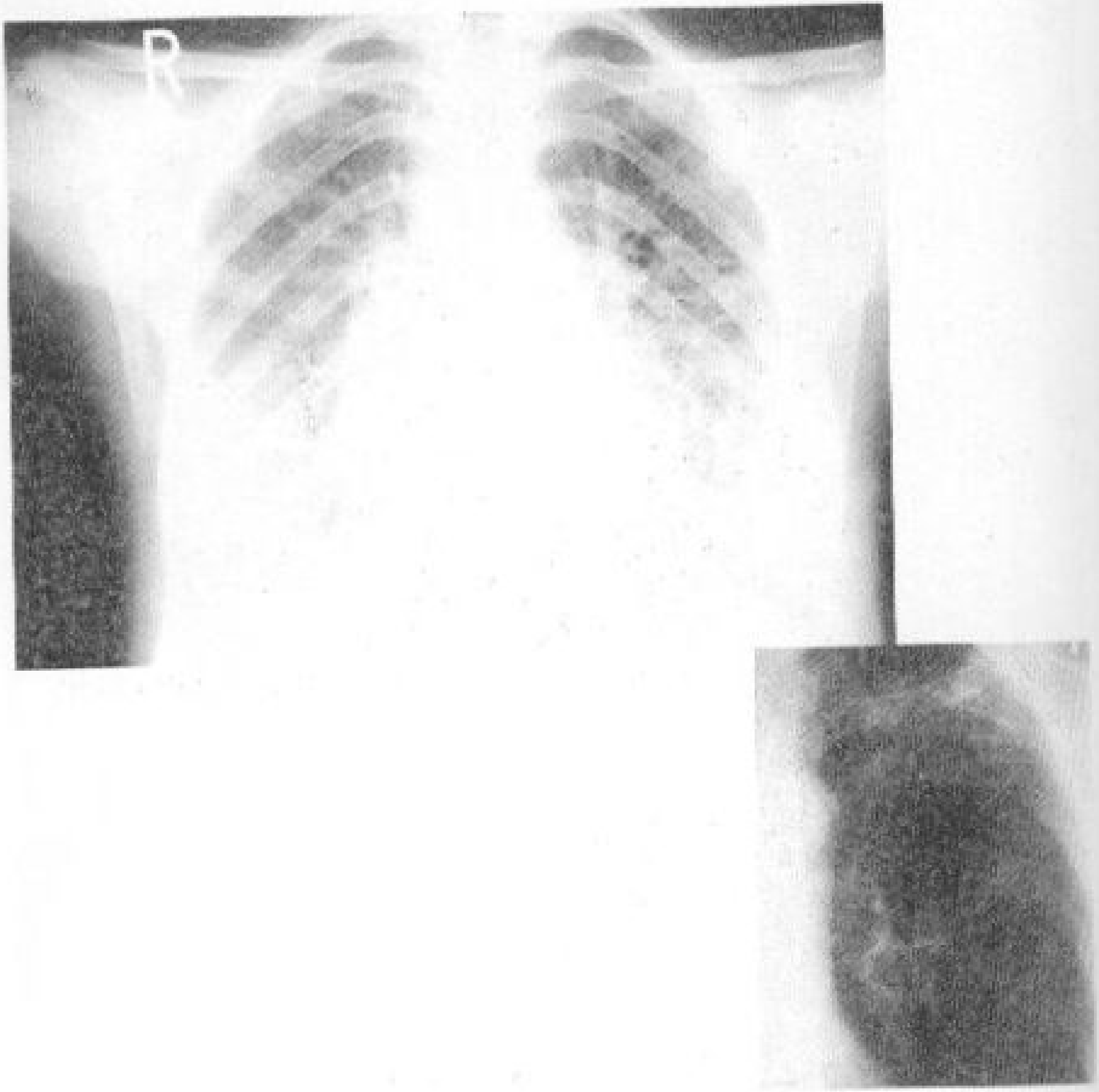

- Plain X ray chest and heart
- Postero-anterior view
- The patient is centralized
- Costophrenic angles are free on both sides
- The upper lung zone is free on both sides
- The middle and lower lung zone show bilateral lesions having honey comb appearance

WhiteKnightLove

Freely you have received; freely give.

1- Lung abscess

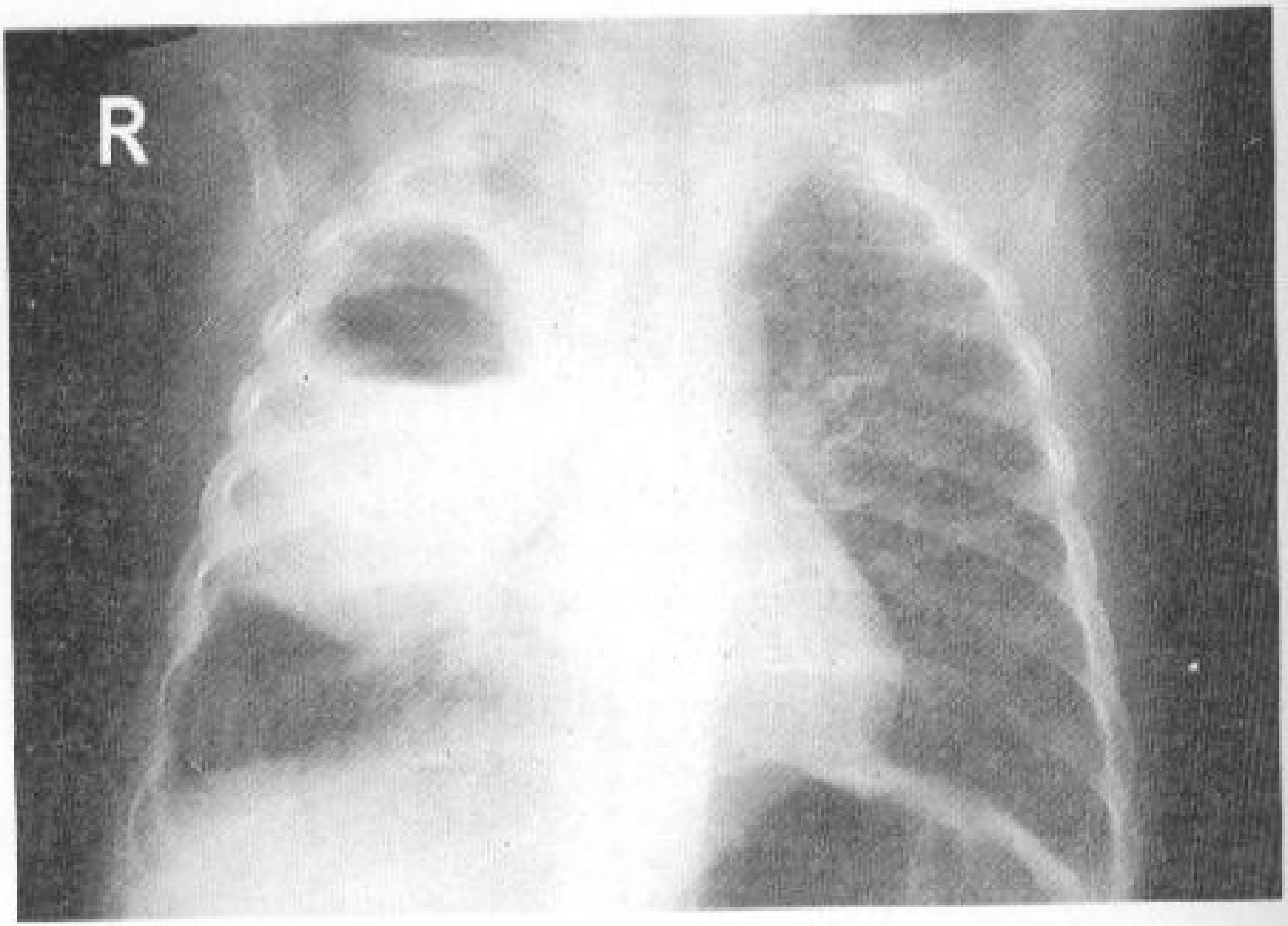

- Plain X ray chest and heart
- Postero-anterior view
- The patient is centralized
- Costophrenic angles are free on both sides
- The upper and middle zone of the right lung show a lesion with well-defined outline (abscess wall). The lower part of the lesion is homogenous with transverse upper border (fluid) while the upper part of the lesion is jet black (air).
- The mediastnum is central

Right side lung abscess

WhiteKnightLove

'It is more blessed to give than to receive.

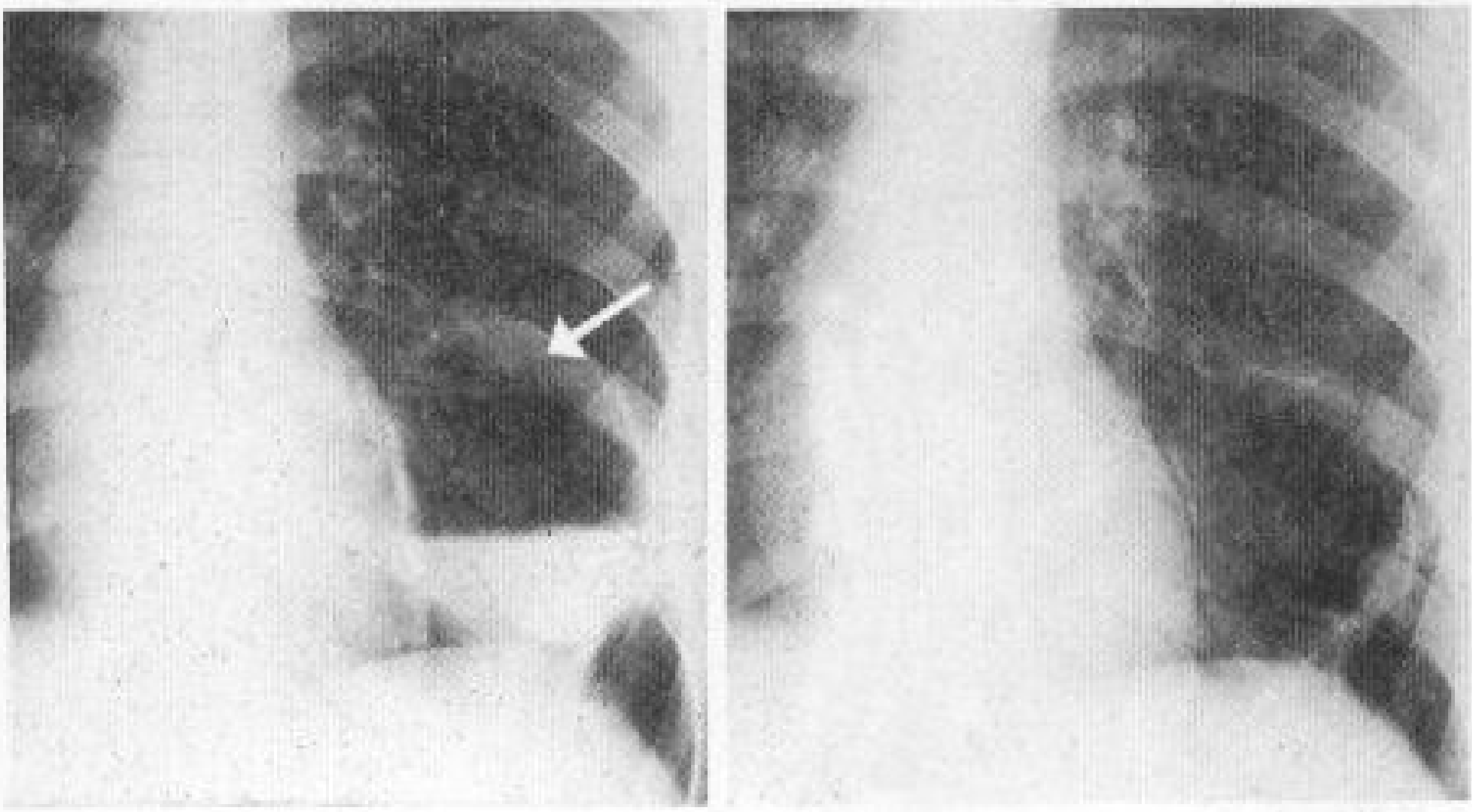

- Plain X ray chest and heart
- Postero-anterior view
- The patient is centralized
- Costophrenic angles are free on both sides
- The lower zone of the left lung shows a lesion with well-defined outline (abscess wall). The lower part of the lesion is homogenous with transverse upper border (fluid) while the upper part of the lesion is jet black (air).
- The mediastinum is central
- The other X- ray shows the effect of antibiotic treatment where the lung field starts to clear

<u>Left side lung abscess</u>

WhiteKnightLove

Freely you have received; freely give.

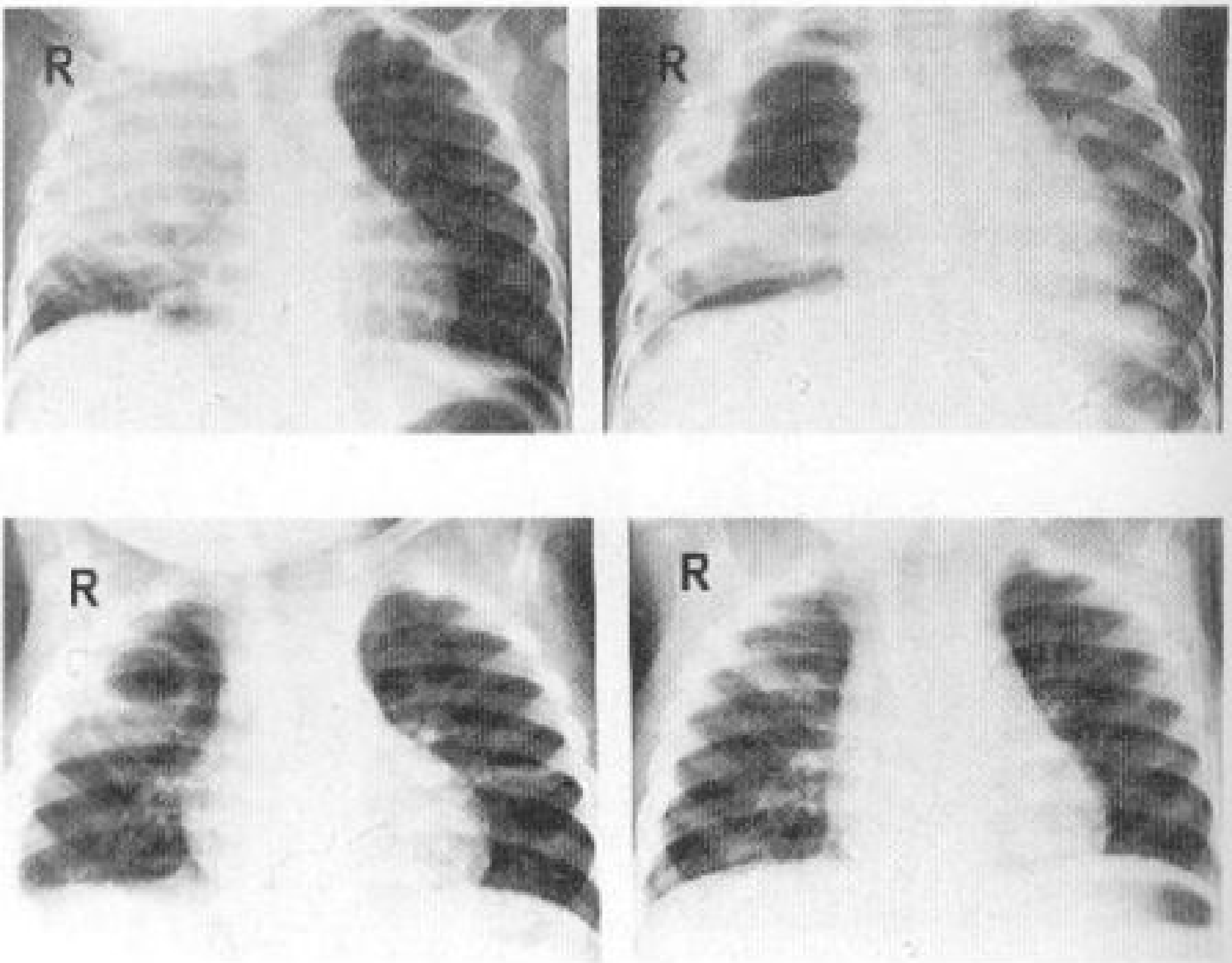

1- The right lung shows homogenous opacity occupying the upper and middle lung zones (pneumonia)
2- One week later ,there is breakdown within the consolidated area with abscess formation (air fluid level)
3- Two weeks after treatment where there is decrease on the size of the abscess
4- Another 2 weeks of treatment ,where the lung field became more or less clear

Lung abscess most probably due to staphylococcal pneumonia

WhiteKnightLove

'It is more blessed to give than to receive.

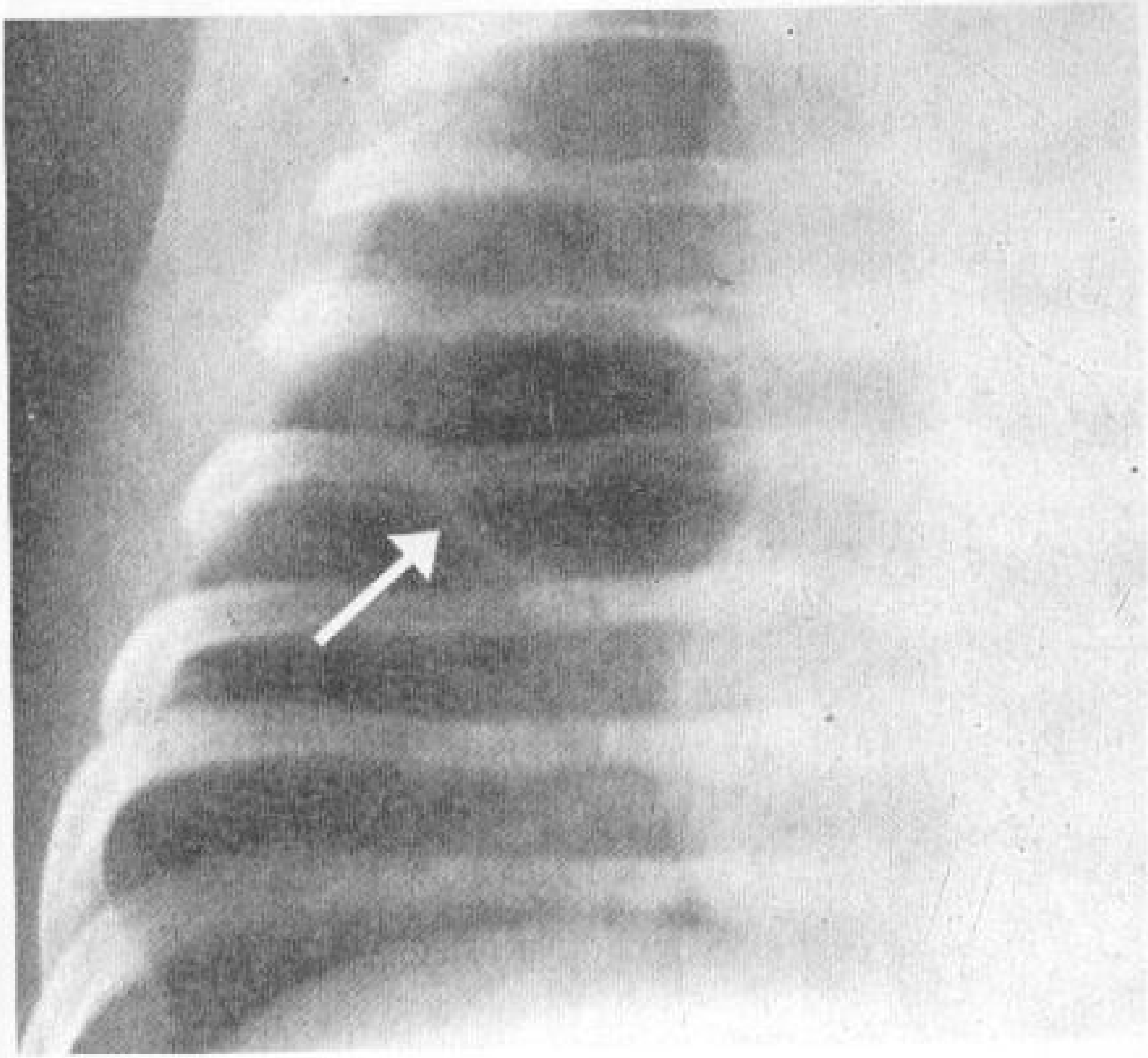

- Plain X ray chest and heart
- Postero-anterior view
- The patient is centralized
- Costophrenic angle on the left side is free
- The middle lung zone shows a pneumatocele (airspace surrounded by thin wall)

<u>The cause is most probably staphylococcal pneumonia</u>

WhiteKnightLove

Freely you have received; freely give.

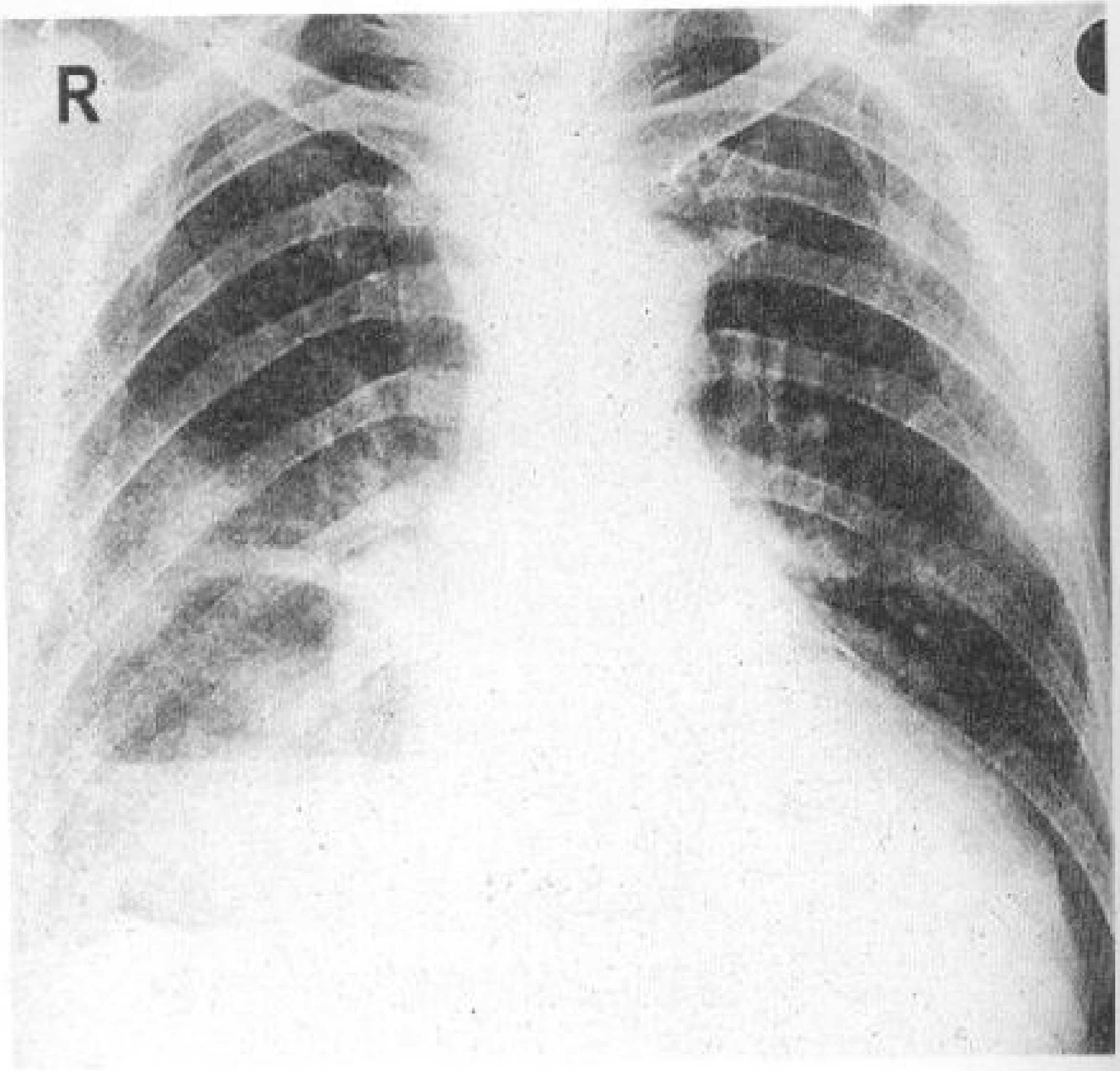

- Plain X ray chest and heart
- Postero-anterior view
- The patient is centralized
- Costophrenic angle on the right side is obliterated
- The lower zone of the right lung shows a lesion with well-defined outline (abscess wall). The lower part of the lesion is homogenous with transverse upper border (fluid) while the upper part of the lesion is jet black (air).
- The mediastinum is central

<u>Right side lung abscess</u>

WhiteKnightLove

'It is more blessed to give than to receive.

2- Pyopneumothorax

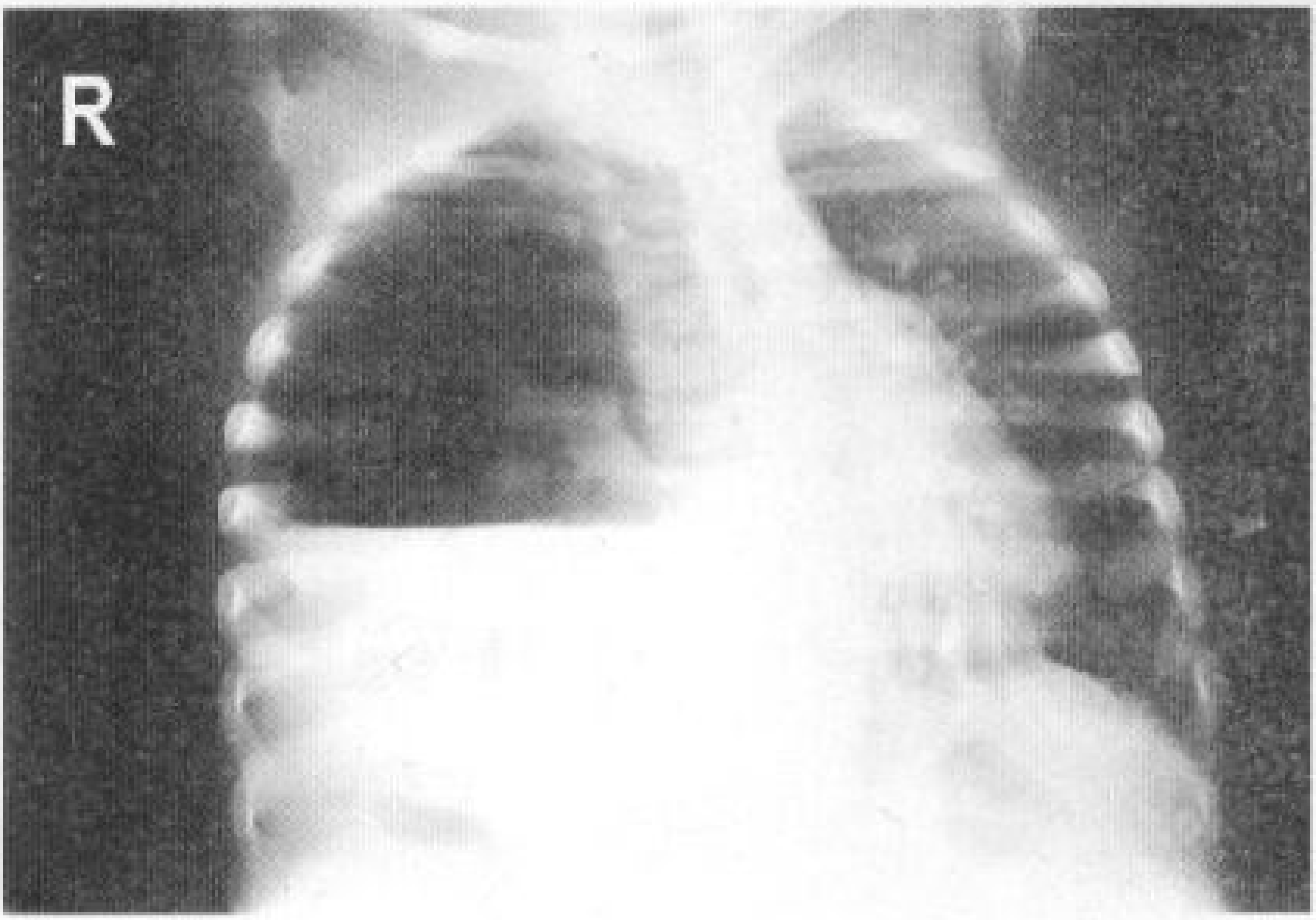

- Plain X ray chest and heart
- Postero-anterior view
- The patient is not centralized
- Costophrenic angle on the left side is free while on the right side is obliterated by homogenous opacity with transverse upper border (fluid). The remaining part of the right hemithorax is jet black (air)
- The mediastinum is shifted to the opposite side the lesion

Right side pyopneumothorx(or hydropneumothorax)

WhiteKnightLove

Freely you have received; freely give.

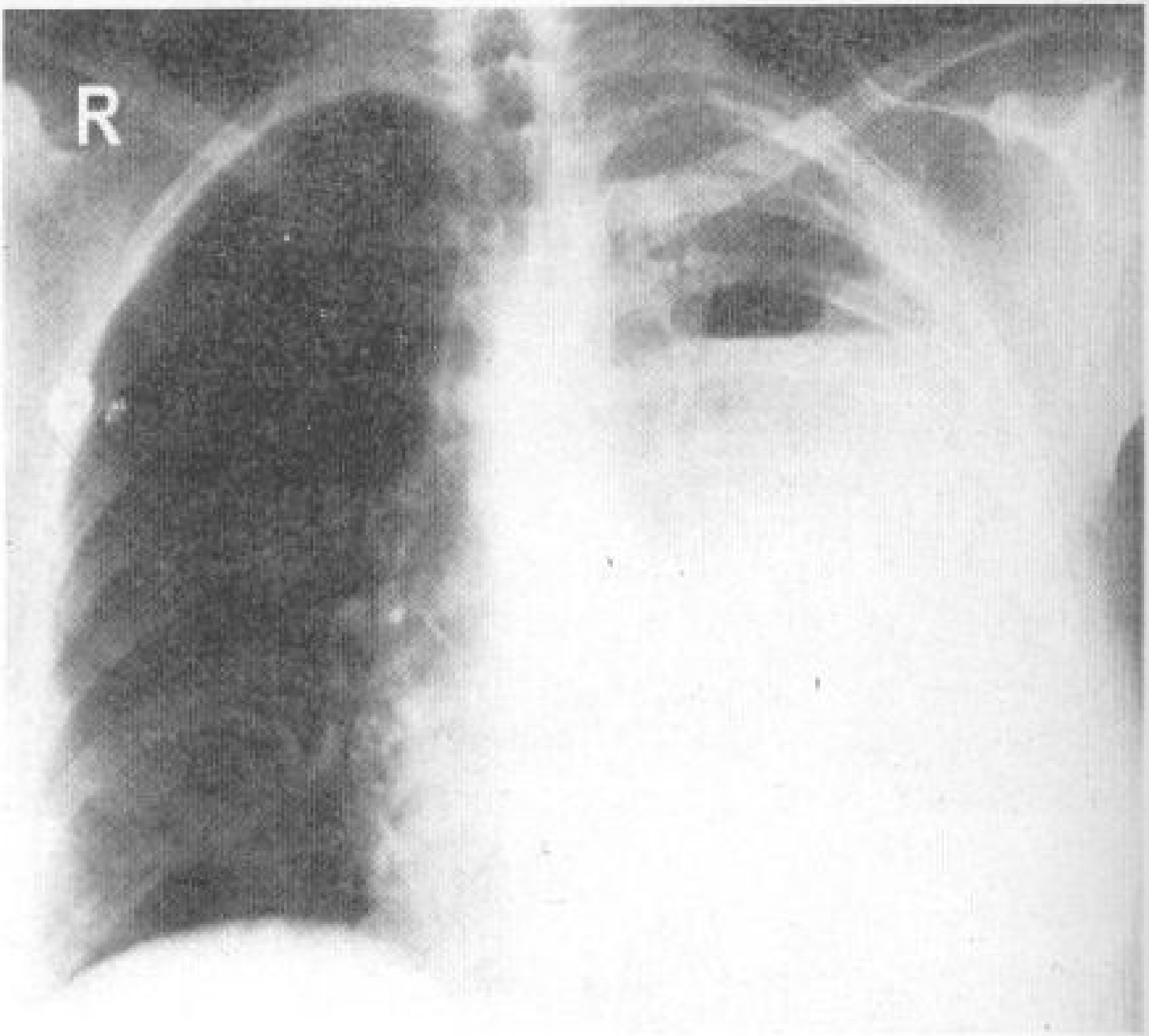

- Plain X ray chest and heart
- Postero-anterior view
- The patient is centralized
- Costophrenic angle on the right side is free while on the left side is obliterated by homogenous opacity with transverse upper border (fluid). The remaining part of the left hemithorax is jet black (air)
- The mediastinum is shifted to the opposite side the lesion

Left side pyopneumothorx (or hydropneumothorax)

WhiteKnightLove

1- Pneumothorax

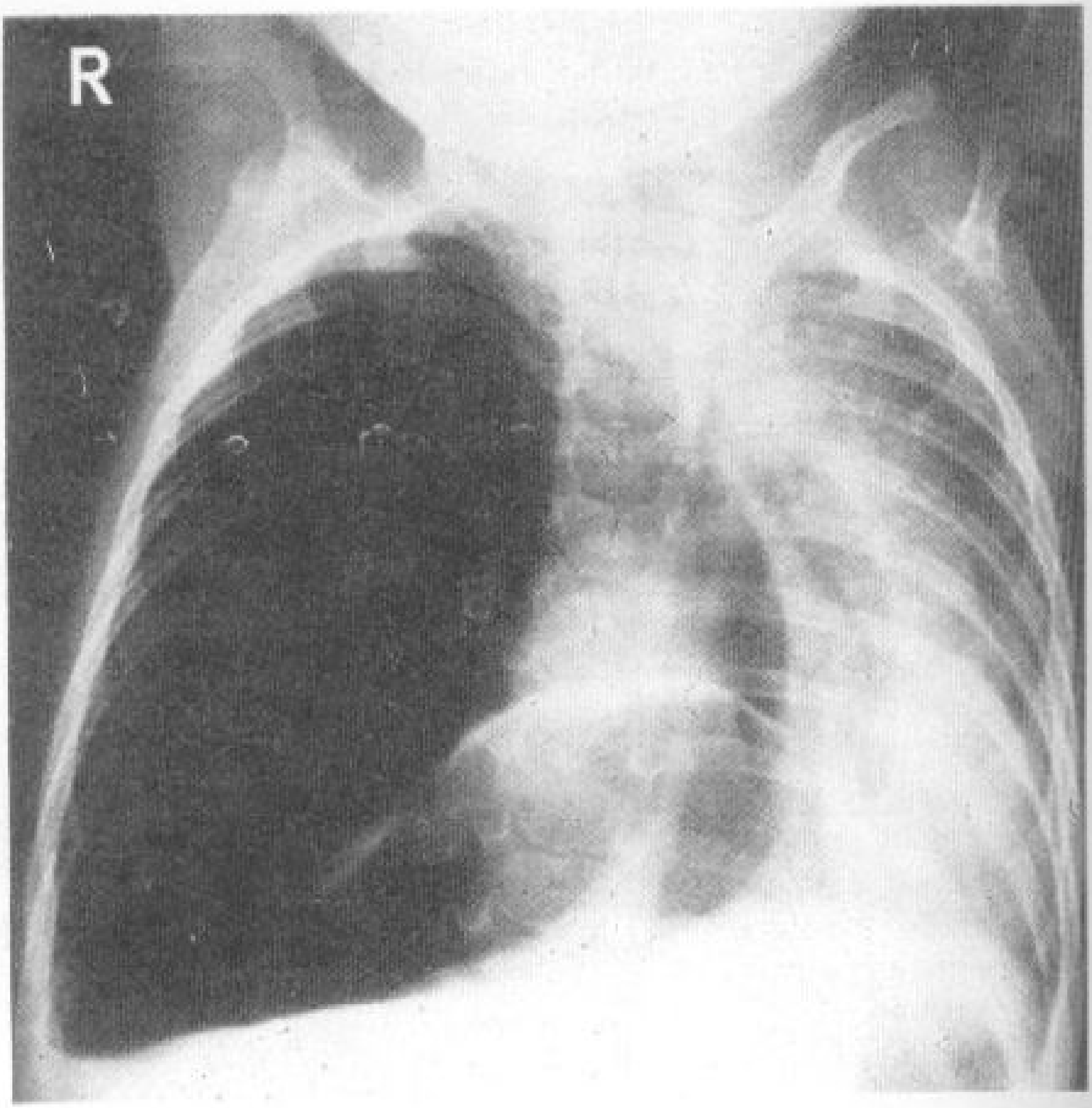

- Plain X ray chest and heart
- Postero-anterior view
- The patient is centralized
- Costophrenic angles are free on both sides
- The right hemithorax is hypertranslucent with absent bronchovascular markings (jet-black) .The right copula of the diaphragm is compressed downwards
- Marked shift of the mediastinum to the opposite side of the lesion

Right side pneumothorax

WhiteKnightLove

Freely you have received; freely give.

2- Emphysema

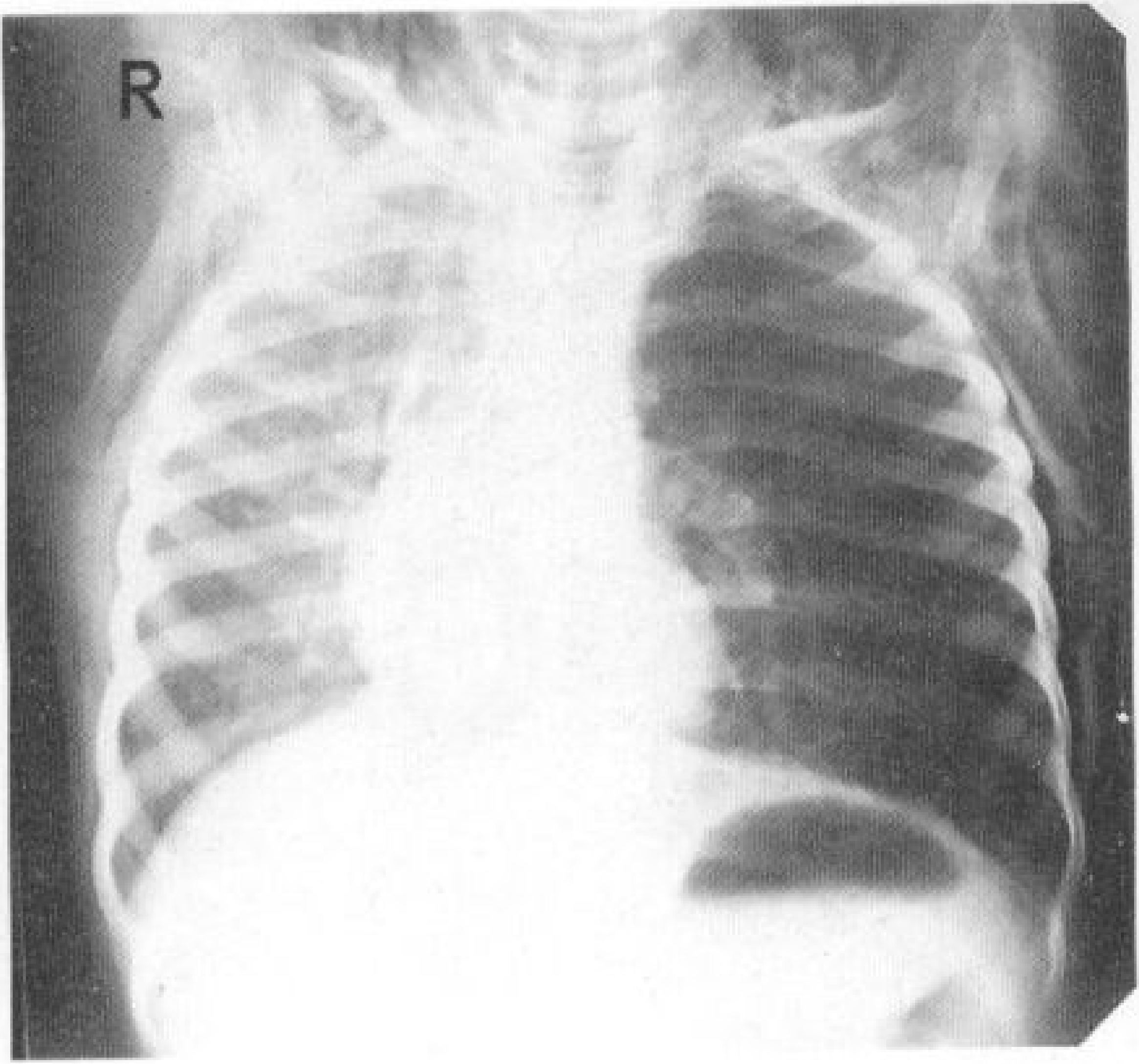

- Plain X ray chest and heart
- Postero-anterior view
- The patient is centralized
- Costophrenic angles are free on both sides
- The left lung is hypertranslucent with intact bronchovascular markings
- Shift of the mediastinum to the opposite side of the lesion

Left side obstructive emphysema

WhiteKnightLove

'It is more blessed to give than to receive.

Hilar shadows

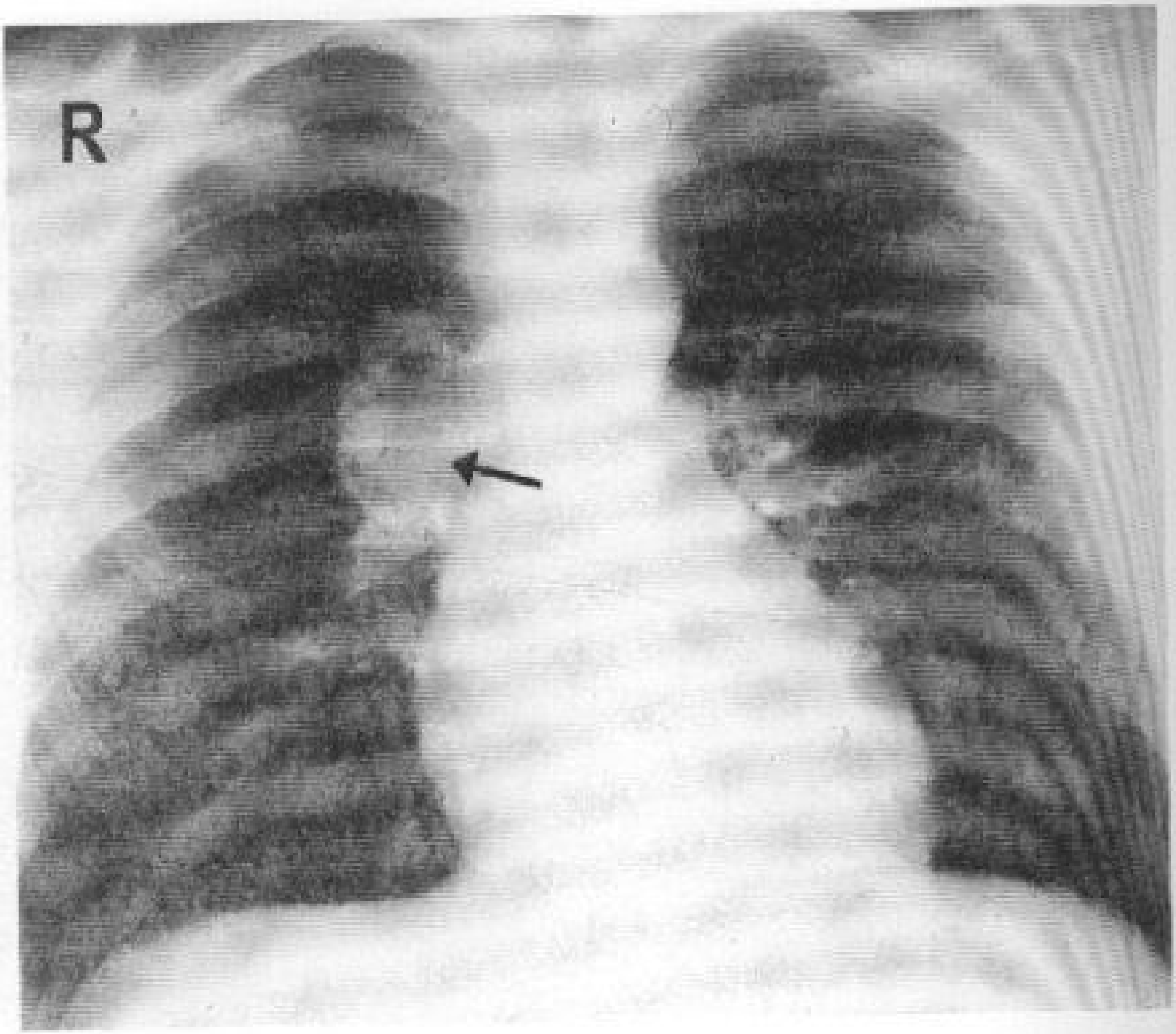

- Plain X ray chest and heart
- Postero-anterior view
- The patient is centralized
- Costophrenic angles are free on both sides
- Bilateral hilar shadow

Hilar lymphadenopathy for differential diagnosis

- TB is the (commonest)
- Lymphoma
- Leukemia

WhiteKnightLove

Freely you have received; freely give.

Radiology of long bones

Normal bone

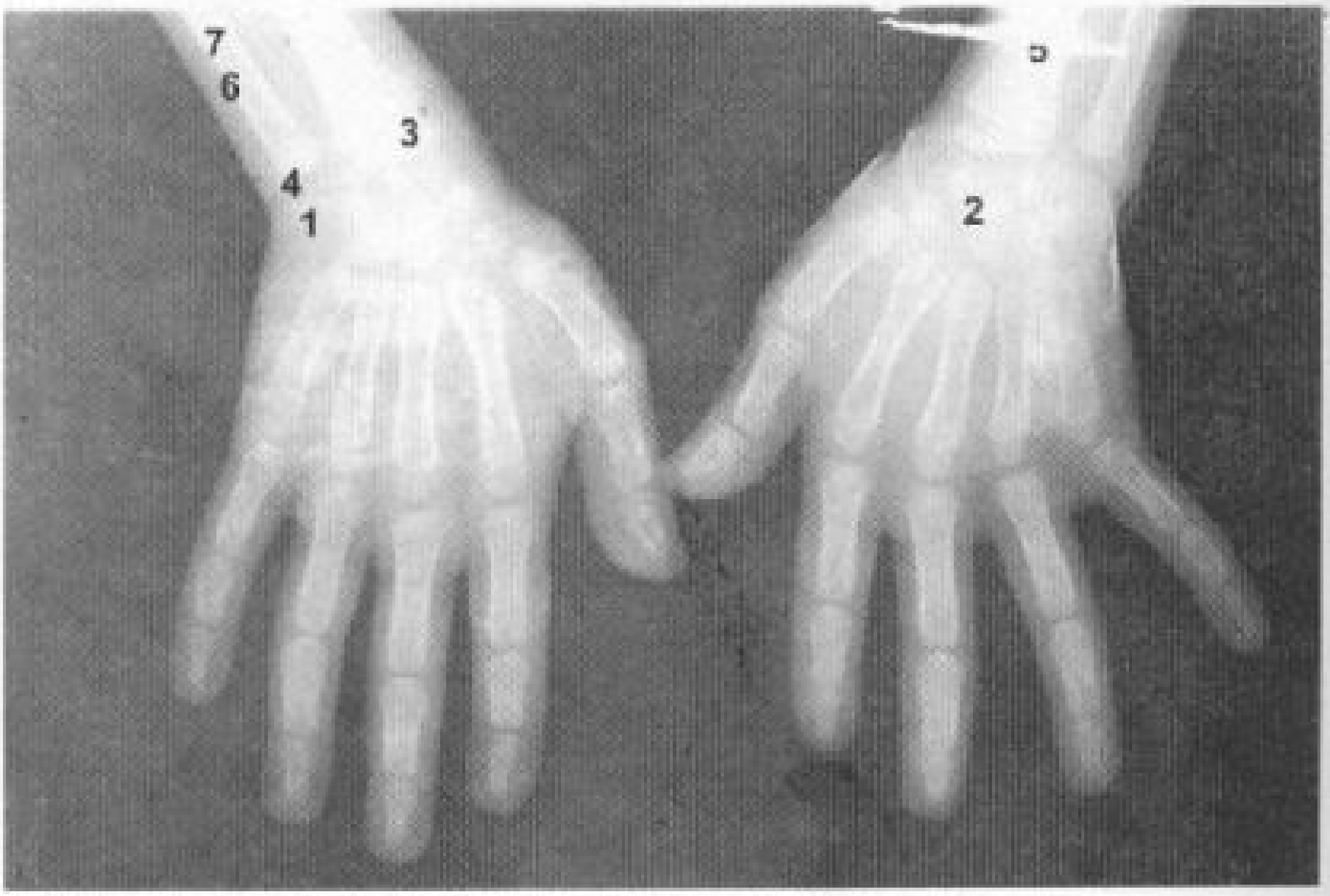

Plain X-ray wrist joints showing

1- Joint space
2- Ossific centers of carpal bones
   Bone age is determined roughly by calculating the number of carpal ossific centers minus one
3- Epiphyseal ossific center (radius)
4- Epiphyseal line(line of provisional calcification)
5- Diaphysis
6- Cortex
7- Medulla

WhiteKnightLove

1- C ·ronic hemolytic anemia

- Plain X ray wrist joint
- Metacarpal bones show: -
  . Loss of waist (rectangular)
  . Thin cortex
  . Wide medulla with mosaic appearance
- Decreased bone density

WhiteKnightLove

Freely you have received; freely give.

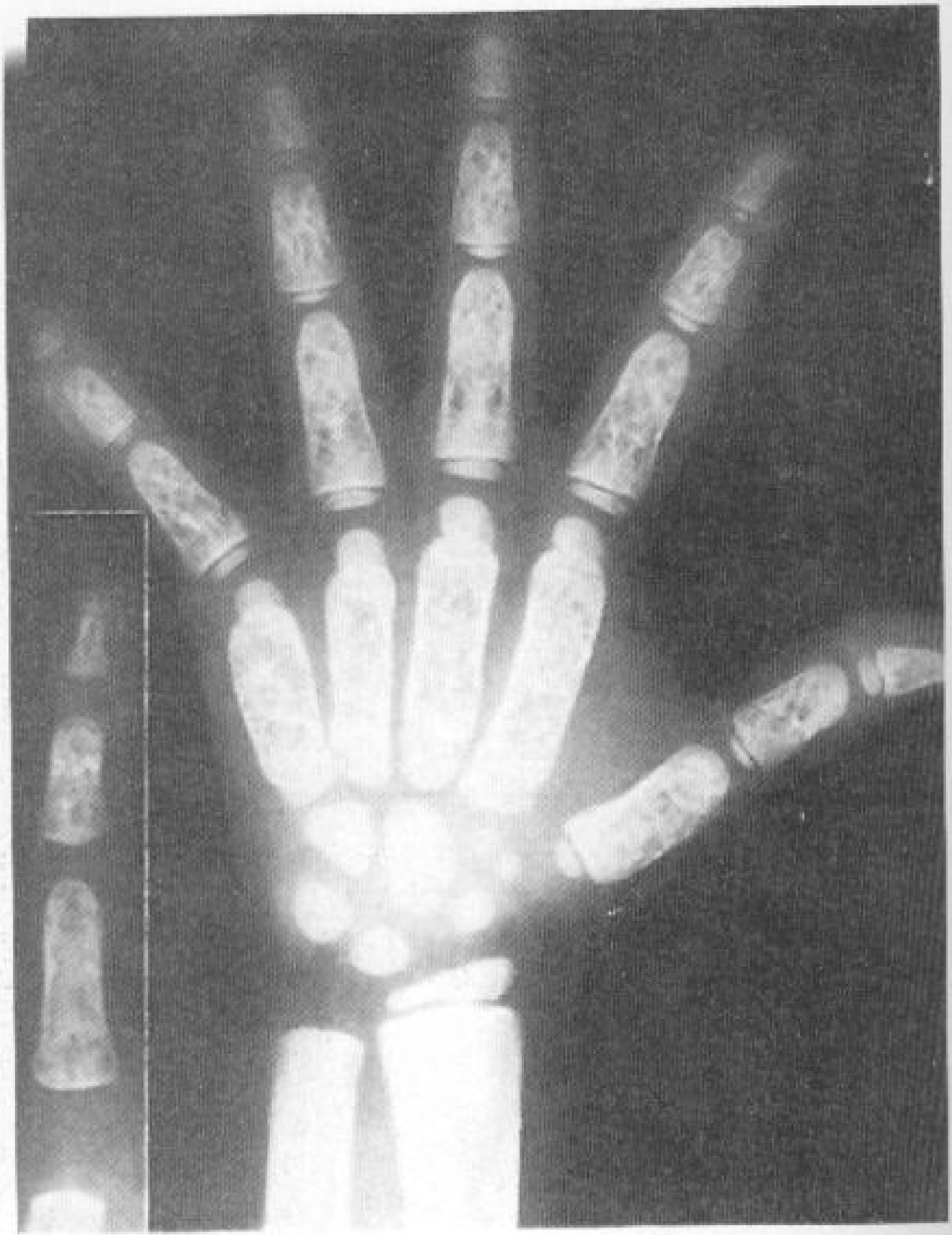

- Plain X ray wrist joint
- Metacarpal bones show: -
  . Loss of waist
  . Thin cortex
  . Wide medulla with mosaic appearance
- Decreased bone density

Chronic hemolytic anemia

WhiteKnightLove

'It is more blessed to give than to receive.

2- Rickets

- Plain X ray wrist joint
- Wide joint space
- Cupping of the metaphyseal area with frayed epiphyseal line
- Decreased bone density
- Bone deformity

Active rickets

WhiteKnightLove

Freely you have received; freely give.

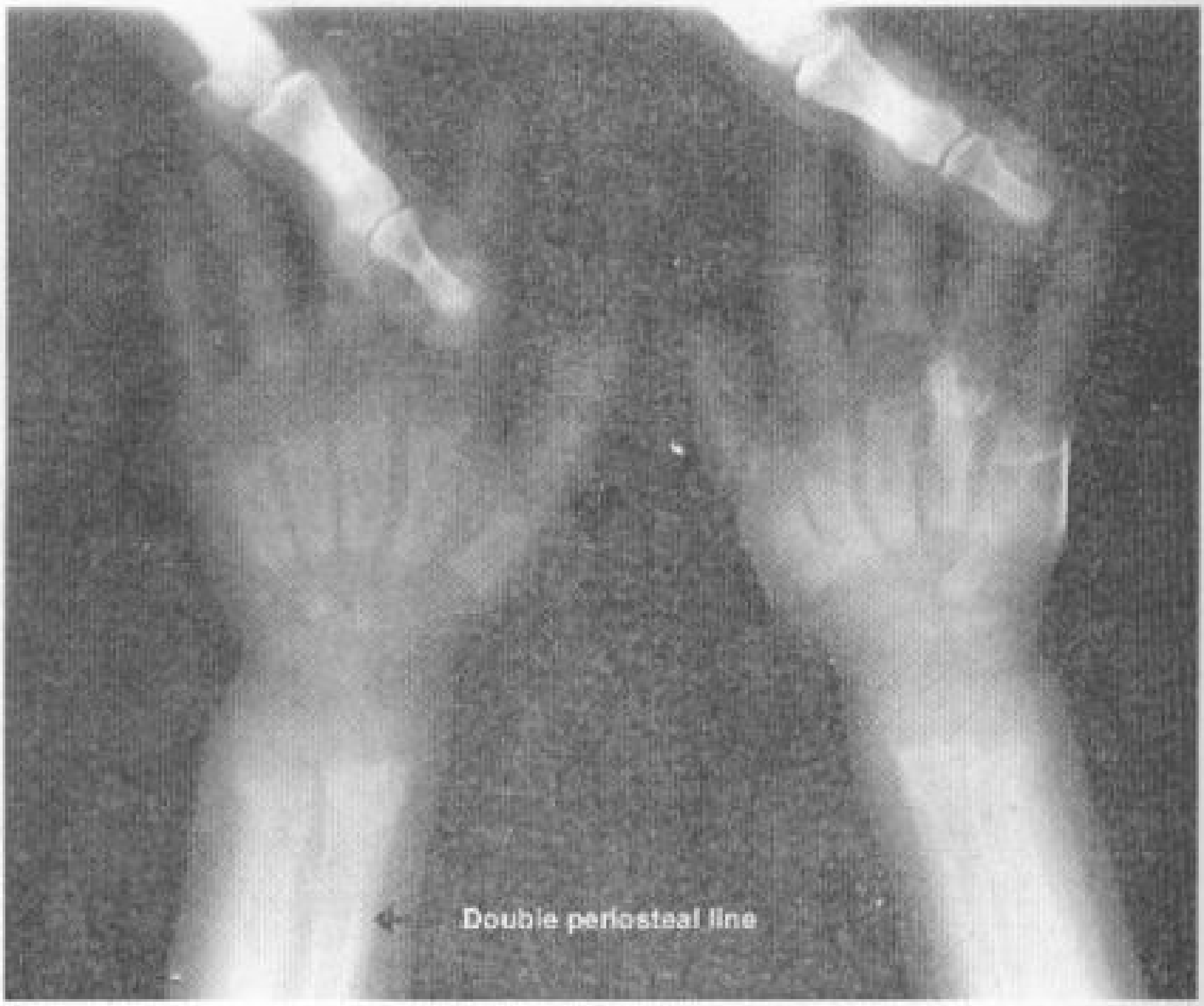

X-ray wrist joint showing: -

- Wide joint space
- Cupping of the metaphyseal area with frayed epiphyseal line
- Decreased bone density
- Double periosteal line

Active rickets

WhiteKnightLove

'It is more blessed to give than to receive.

- <u>Healing rickets</u>

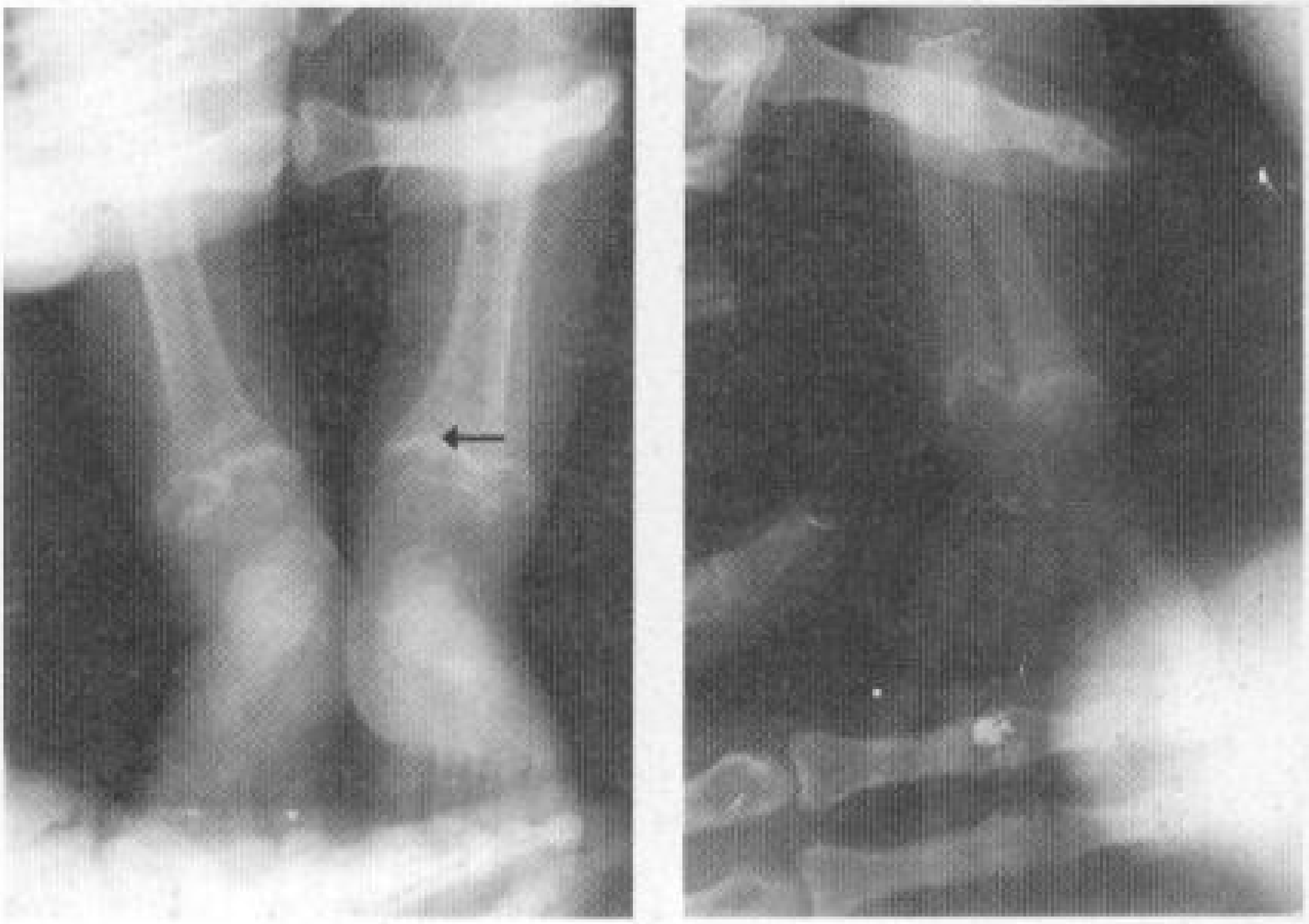

X ray wrist and ankle joints showing

- Wide joint space
- Cupping of the metaphyseal area
- White concave line at the lower ends of radius and ulna (line of provisional calcification)- similar changes are present of the bones of the lower limbs
- Decreased bone density

WhiteKnightLove

Freely you have received; freely give.

- Active and healing rickets

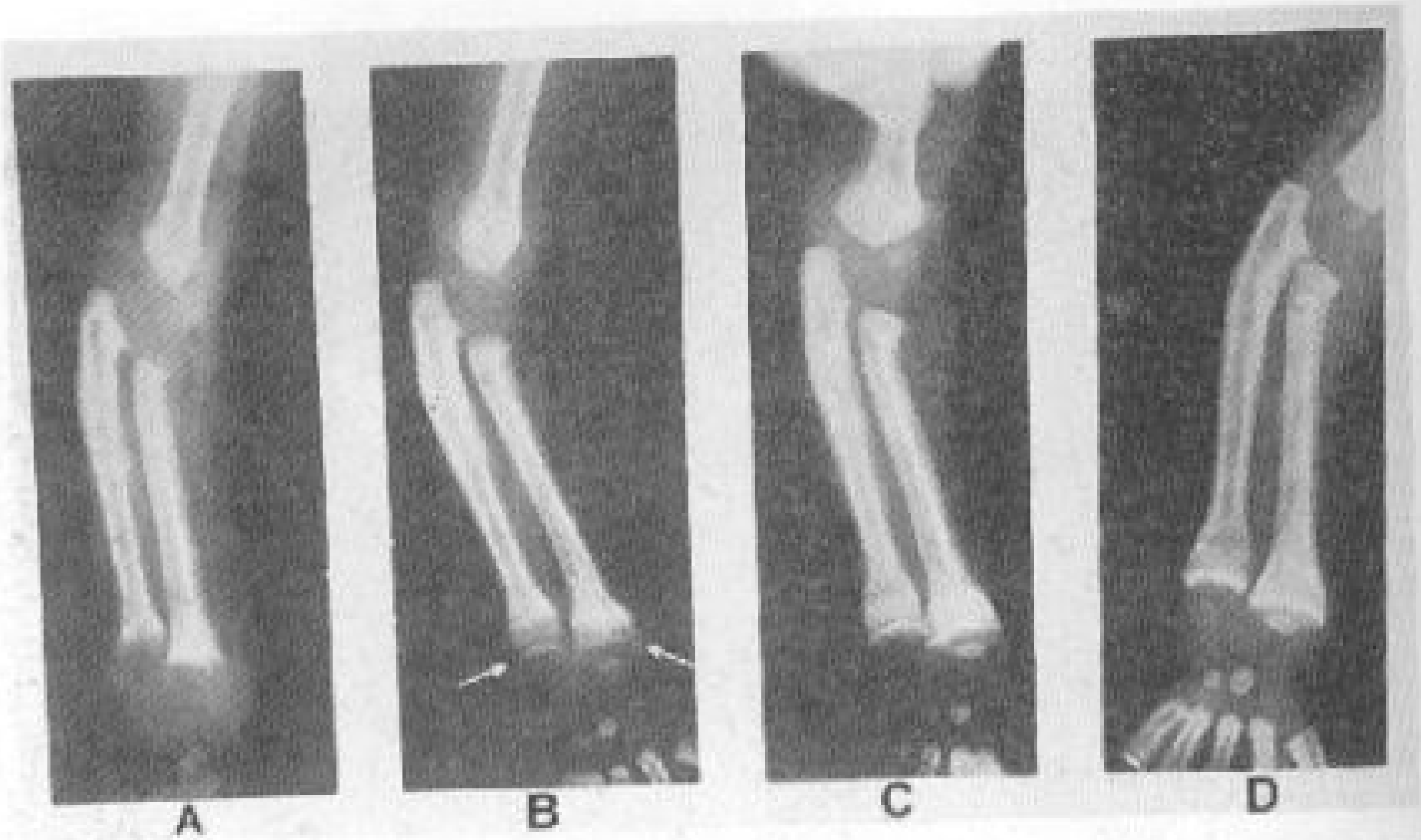

X-ray wrist joint showing: -

1- Active rickets
- Wide joint space
- Cupping of the metaphyseal area with frayed epiphyseal line
- Decreased bone density

2- Healing rickets
- Start of healing proc
appear as thin line separate from the shaft

3- Healing rickets
- Line of provisional calcification became more prominent

3- Healing rickets
- Line of provisional calcification is more dense and continuos with shaft

WhiteKnightLove

'It is more blessed to give than to receive.

Healed rickets

X-ray wrist joint showing: -
- Normal joint space
- Metaphyseal are is normal (no cupping)- but the epiphyseal line is more dense than the rest of the bone
- More or less normal bone density

WhiteKnightLove

Freely you have received; freely give.

3- Osteogenesis imperfecta

Skeletal survey showing: -

- Marked decrease in the one density
- Loss of differentiation between medulla and cortex
- Multiple fractures with malunion
- Marked bone deformities

WhiteKnightLove

'It is more blessed to give than to receive.

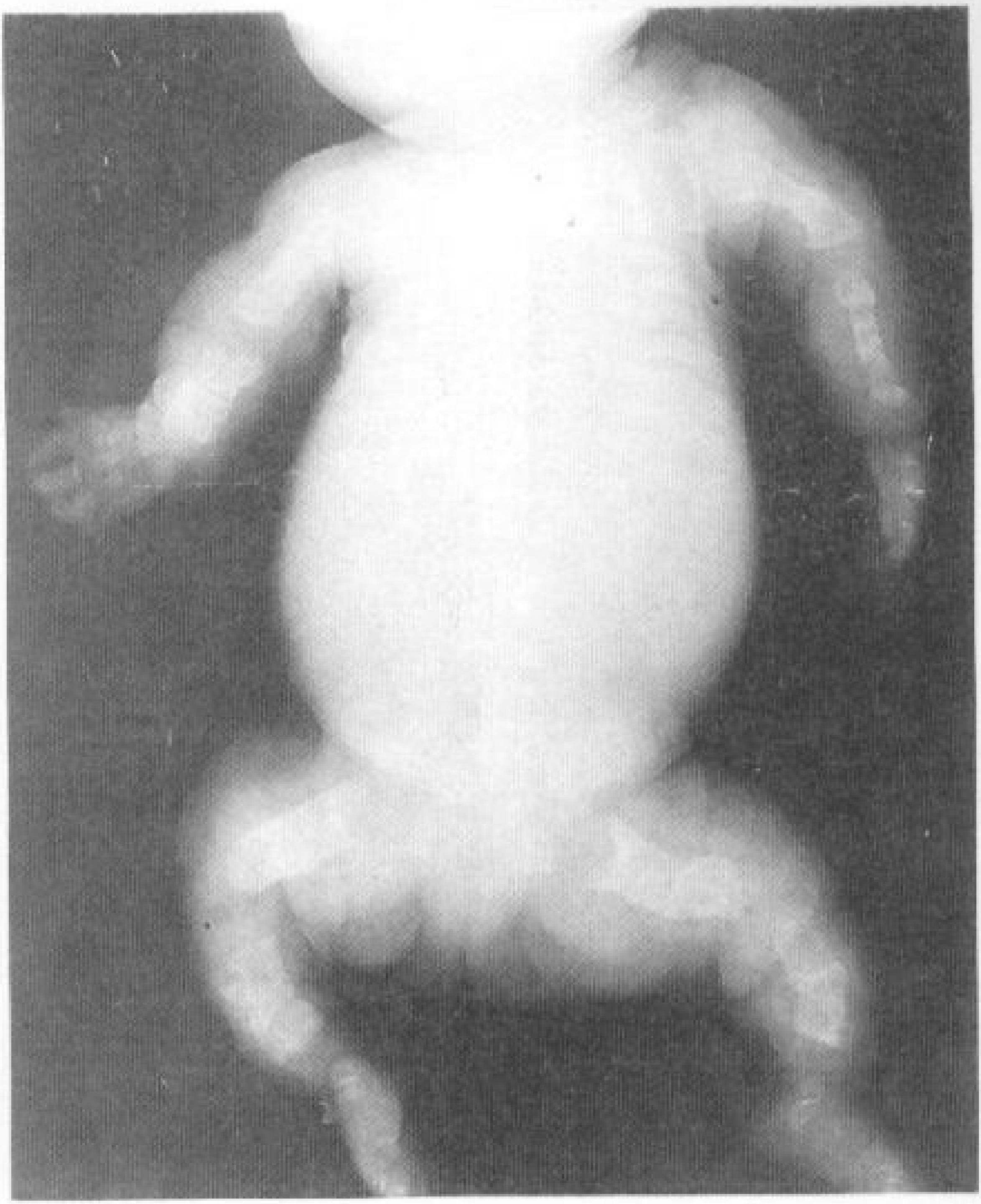

Skeletal survey showing: -

- Marked decrease in the one density
- Loss of differentiation between medulla and cortex
- Multiple fractures with malunion
- Marked bone deformities

Osteogenesis imperfecta

WhiteKnightLove

Freely you have received; freely give.

4- Osteopetrosis (marble bone disease)

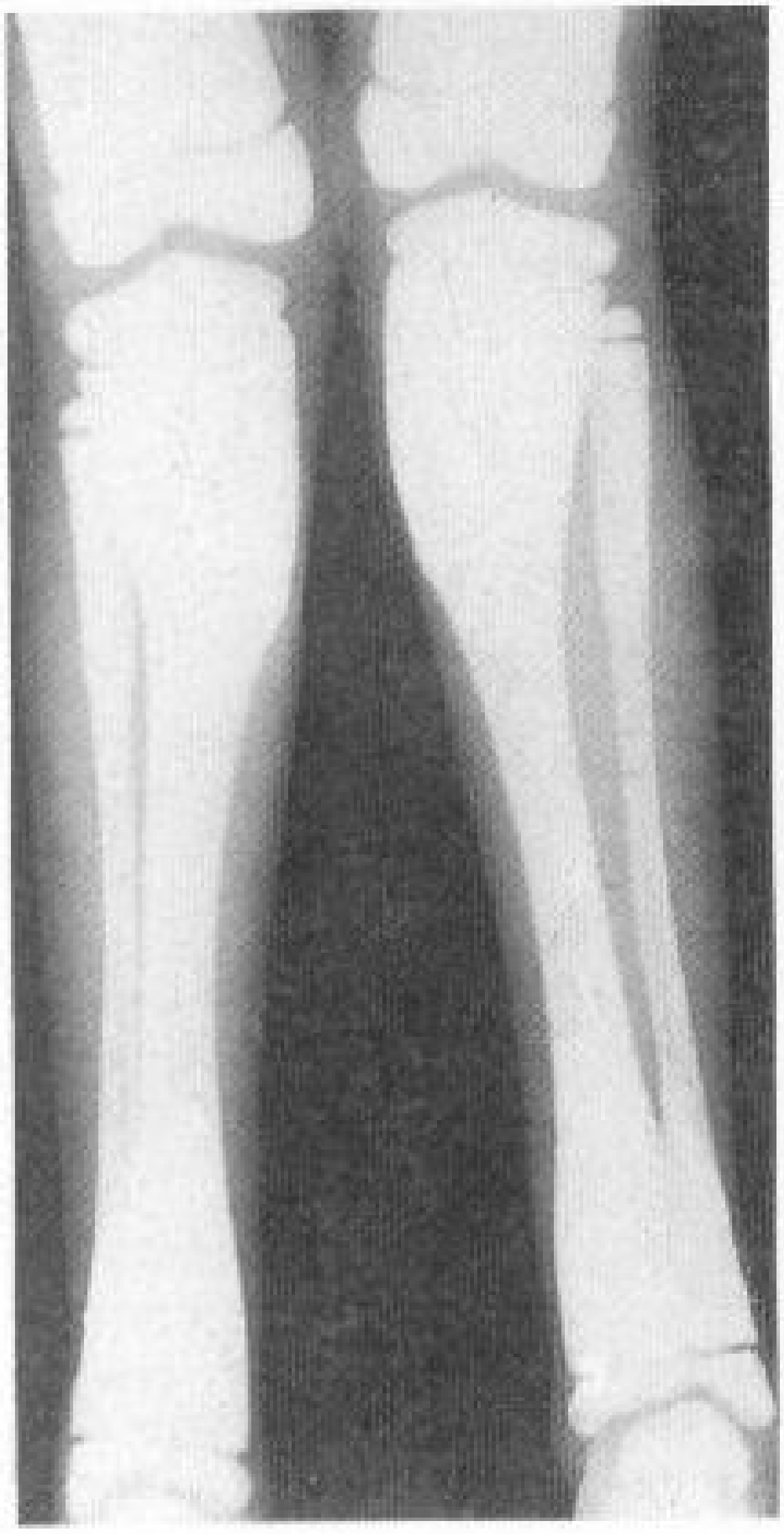

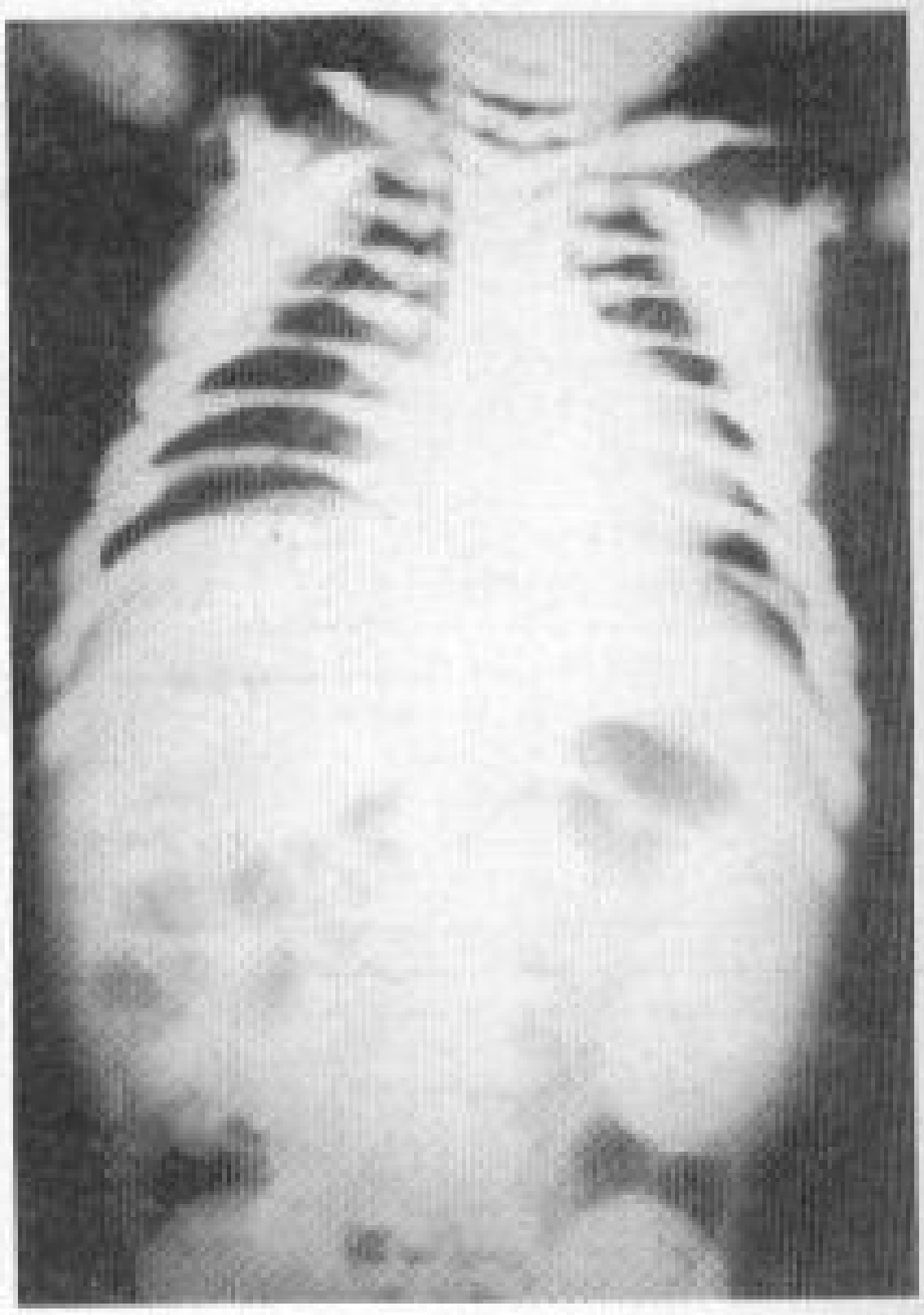

Skeletal survey showing: -

- Marked increase in bone density (marble like bone)
- Loss of differentiation between medulla and cortex

WhiteKnightLove

'It is more blessed to give than to receive.

Normal skull

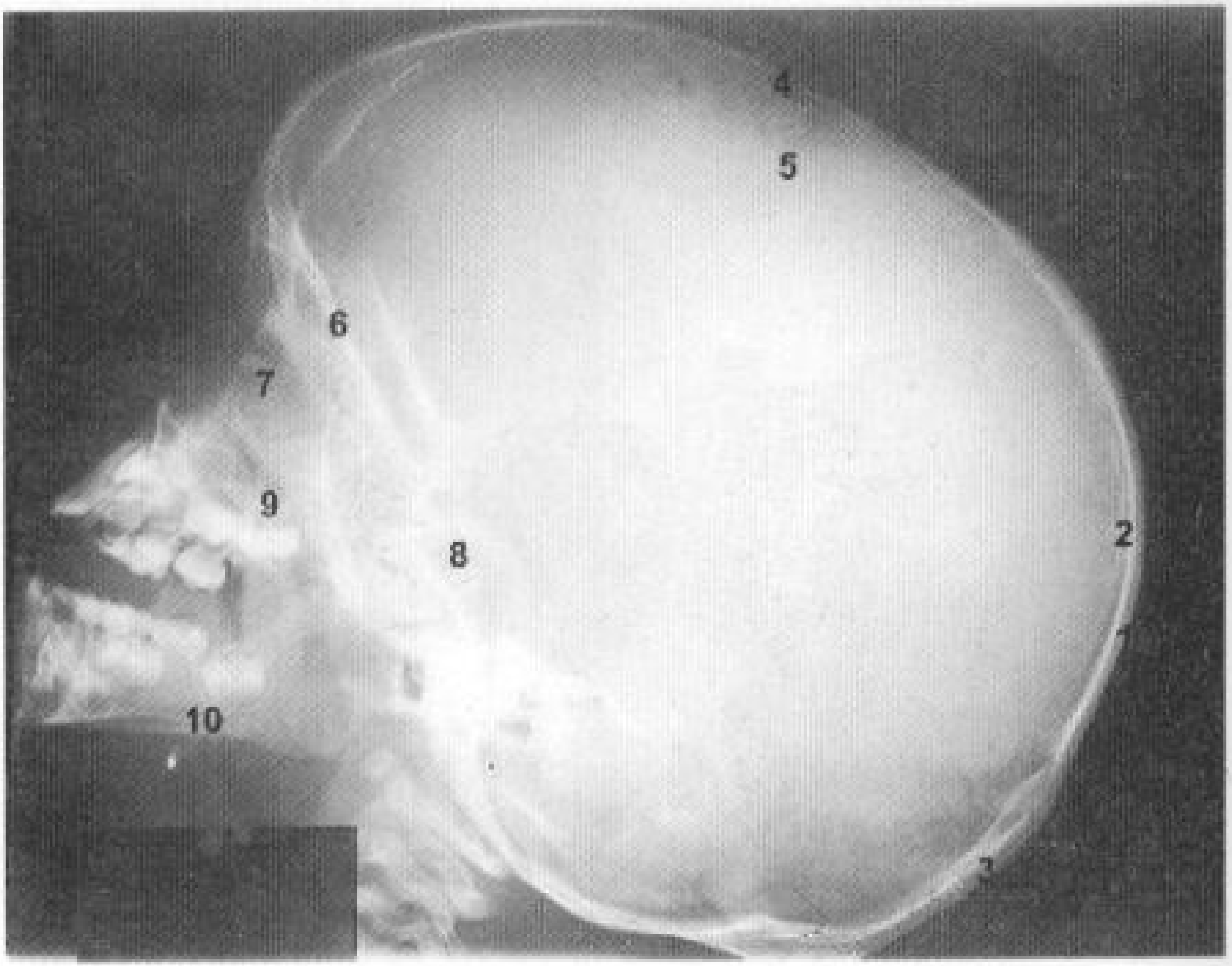

1- Outer table
2- Inner table
3- Diploic space
4- Anterior fontanelle
5- Coronal suture
6- Roof of the orbit
7- Orbit
8- Sella turcica
9- Maxilla
10-Mandibule

WhiteKnightLove

Freely you have received; freely give.

1- Microcephaly

- Skull X ray postero-anterior view
- Marked decrease in the size of the cranial bone

Causes

I- Primary (genetic)
- 1-Familial (autosomal recessive)
- 2-Autosomal dominant
- 3-Syndromes (Down - Edward- Cri du chat)

II- Secondary (non genetic)
- 1-Prenatal causes
  - -Intrauterine infections (cytomeglovirus- Rubella)
  - -Irradiation
  - -Toxins e.g. → fetal alcohol syndrome or fetal hydantoin syndrome
- 2-Natal causes
  - -Hypoxic ischemic injury
  - -Intracranial hemorrhage
- 3-Post- natal causes
  - -Kernicterus
  - -CNS infections
  - -Intracranial hemorrhage

WhiteKnightLove

'It is more blessed to give than to receive.

2- Increased intracranial tension before closure of sutures

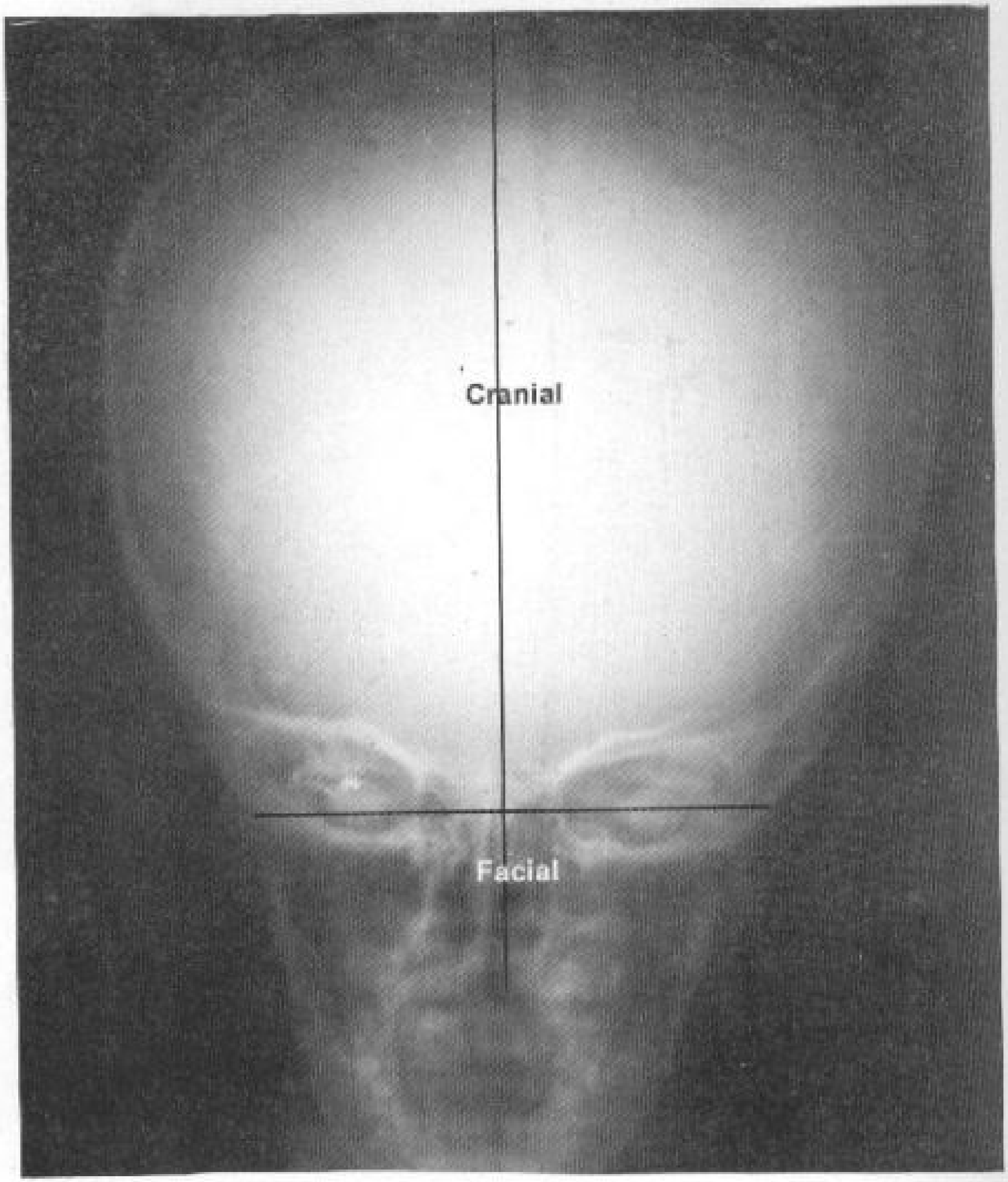

Skull X ray postero-anterior view

- Marked cranio-facial disproportion with marked increase in the size of the cranial bone with ratio: 5 (cranial bone) to 1 (facial bone) normal ratio is 3 to 1
- Separated sutures

WhiteKnightLove

Freely you have received; freely give.

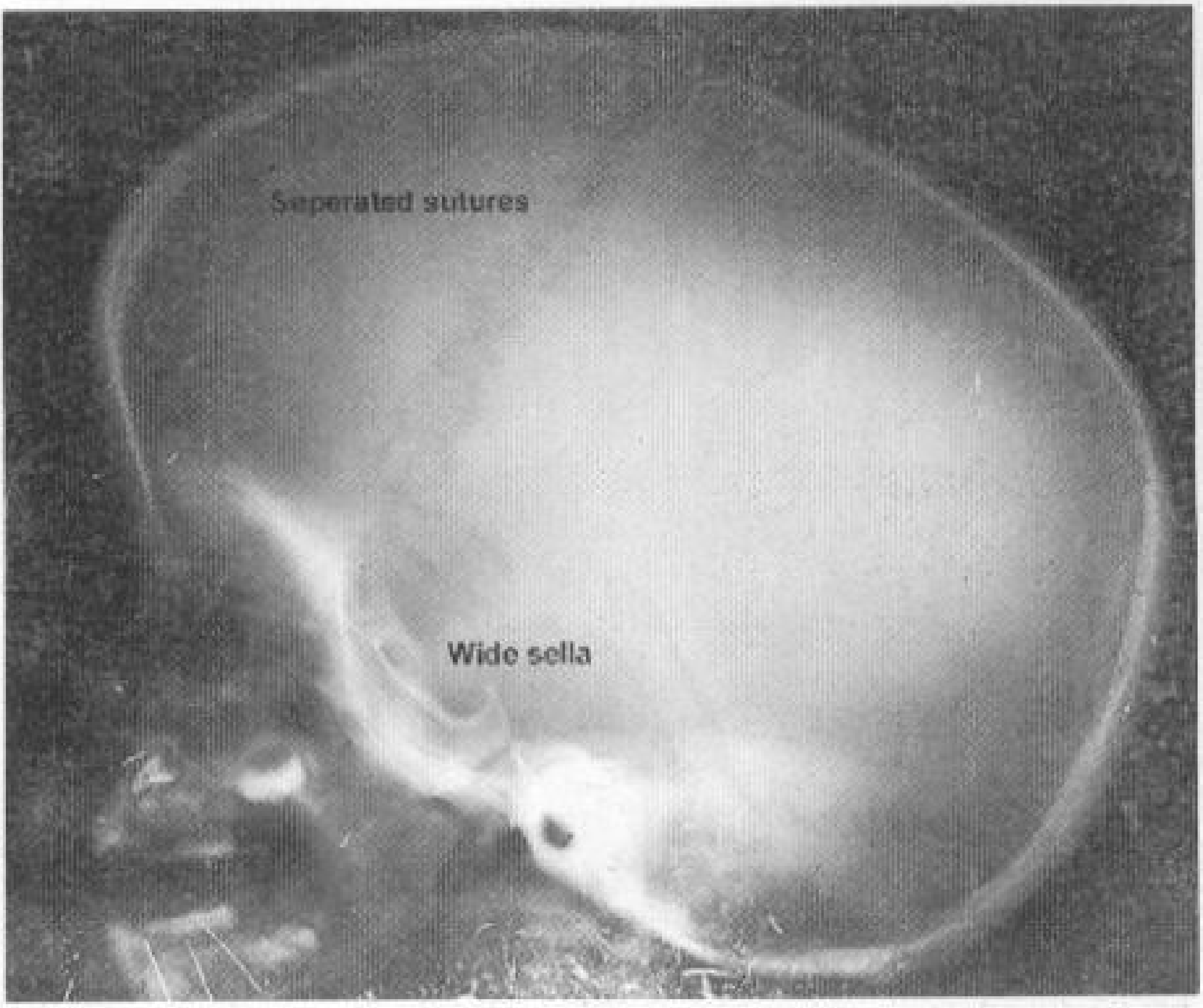

X ray skull lateral view

- Increase in the size of cranial bone
- Separated sutures
- Wide sella

Increased intracranial tension for differential diagnosis

Causes of increased intracranial tension

Increase tension without a mass lesion:

- Hydrocephalus.
- Subdural hematoma.
- Subdural effusion.

Increase tension with a mass lesion:

- Brain tumors.
- Tuberculoma.
- Chronic abscess

WhiteKnightLove

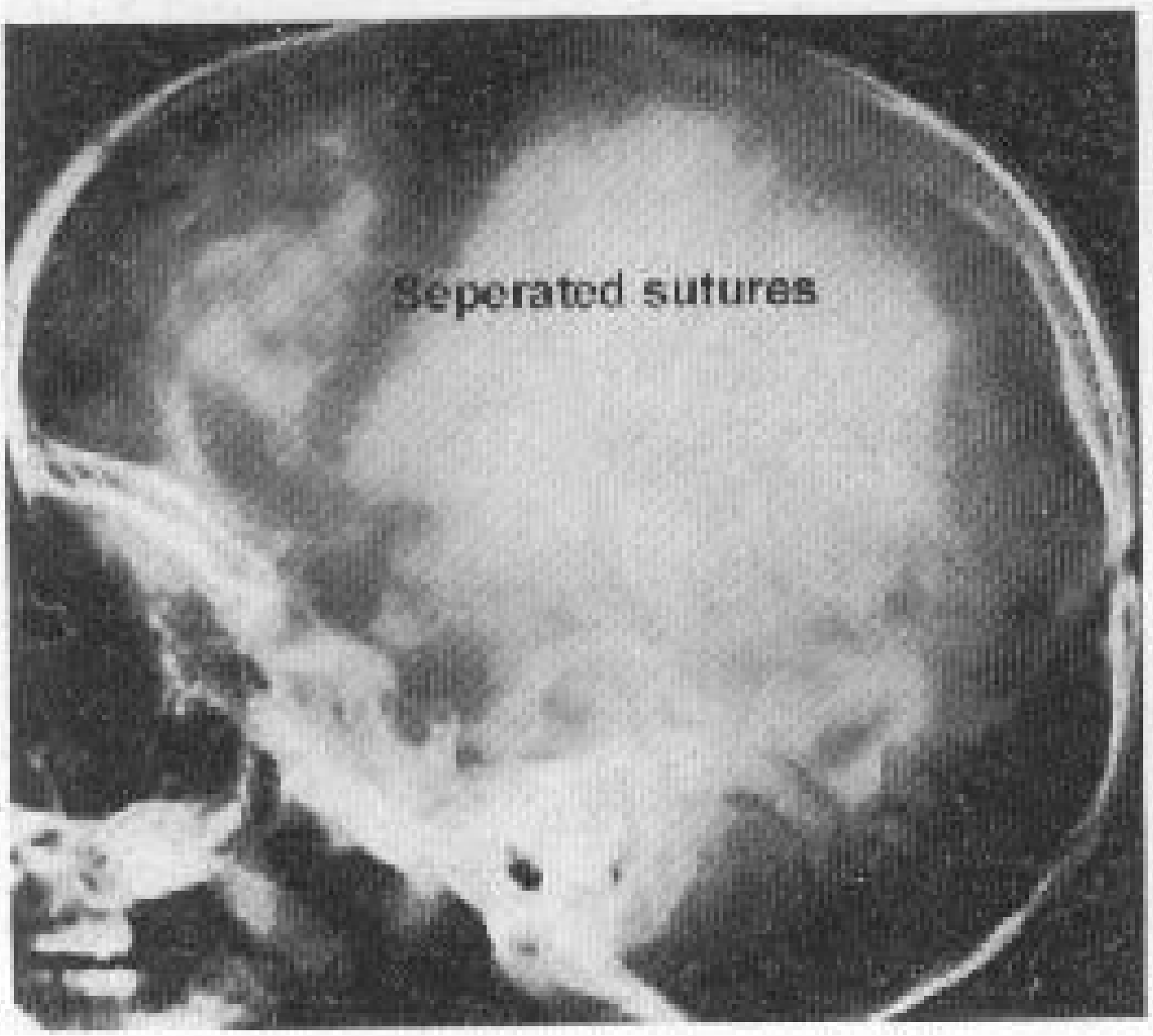

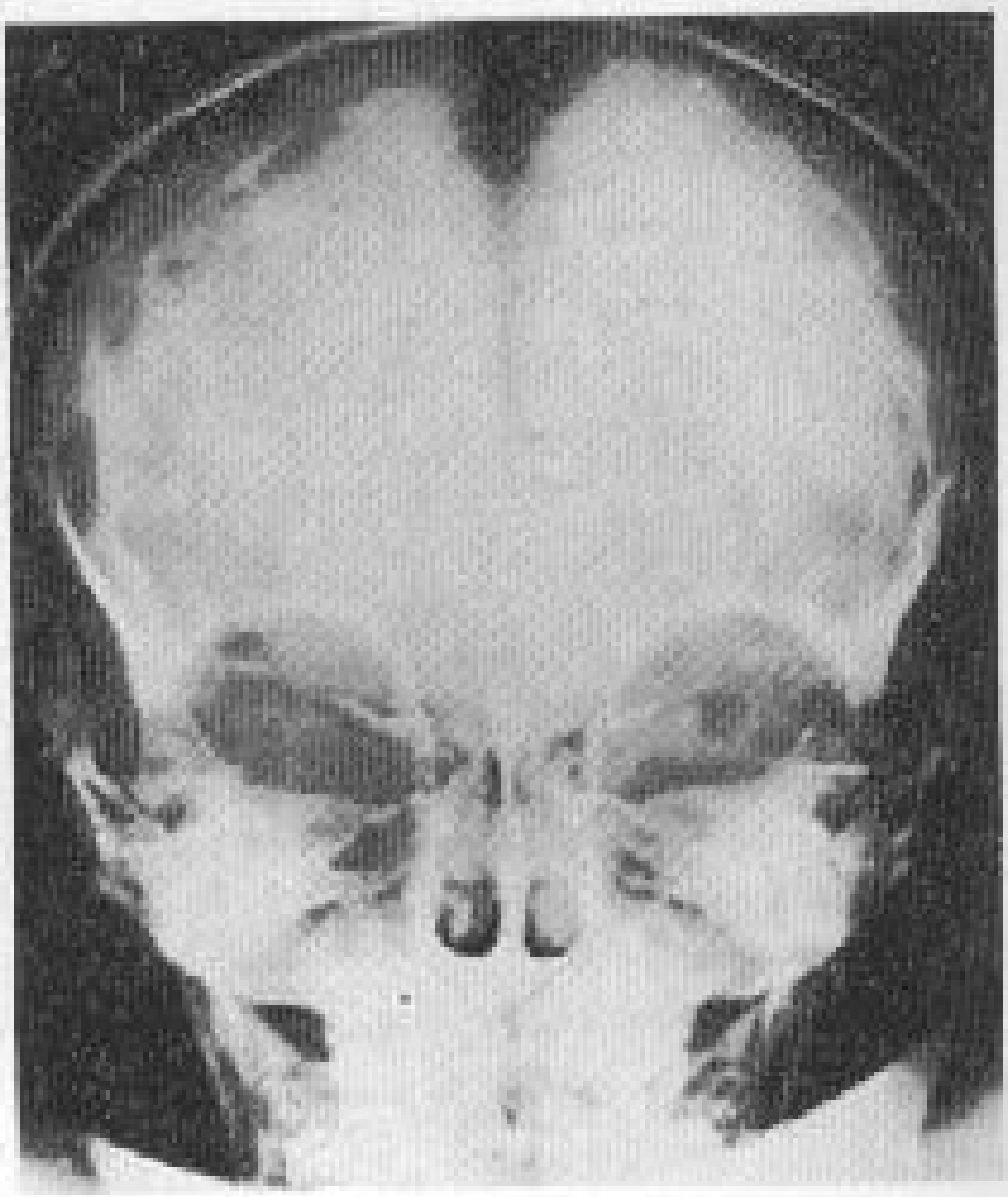

X ray skull postero-anterior and lateral view

- Cranio-facial disproportion (increased size of cranial bone)
- Separated sutures (cronal suture)

Increased intracranial tension

WhiteKnightLove

Freely you have received; freely give.

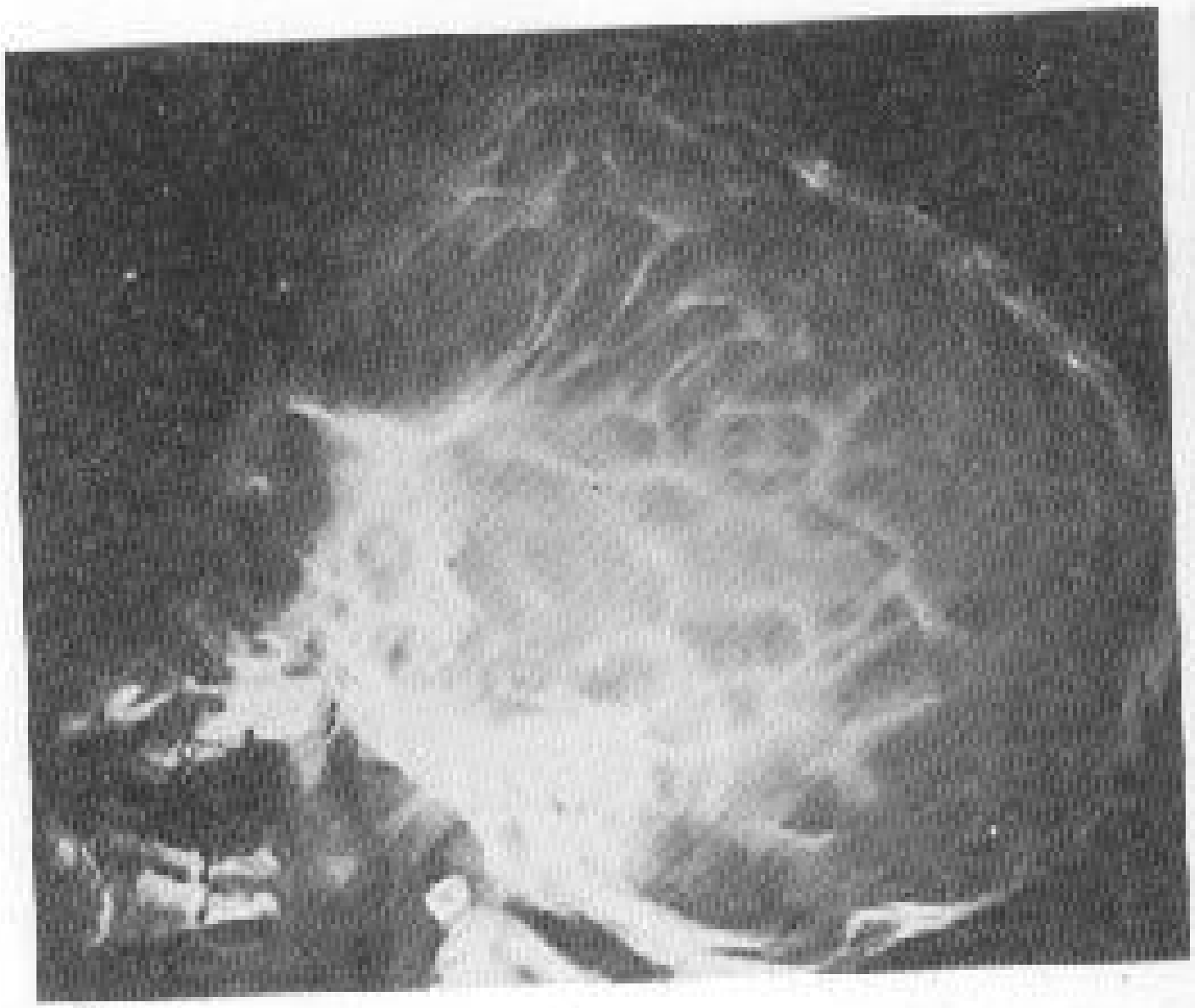

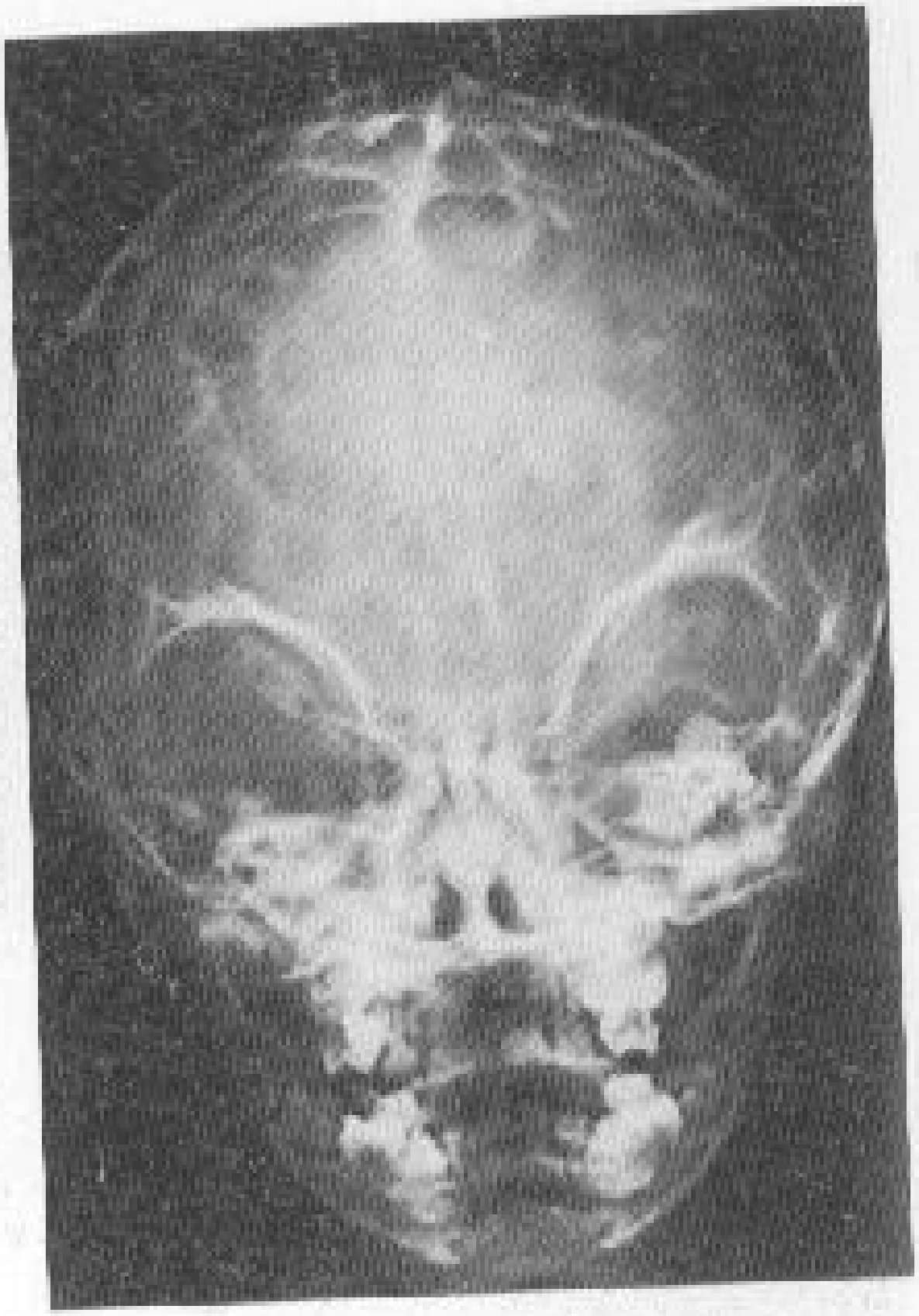

X ray skull postero-anterior and lateral view

- **Increase in the skull convolutional markings with beaten silver appearance (finger prints) of the skull bone**
- **The skull appears also deformed**

Craniostenosis

Causes of craniostenosis

- Isolated congenital deformity
- As a component of certain inherited syndromes
- Metabolic disorders e.g. idiopathic hypercalcaemia, hypophosphatasia
- After excessive thyroxin therapy

WhiteKnightLove

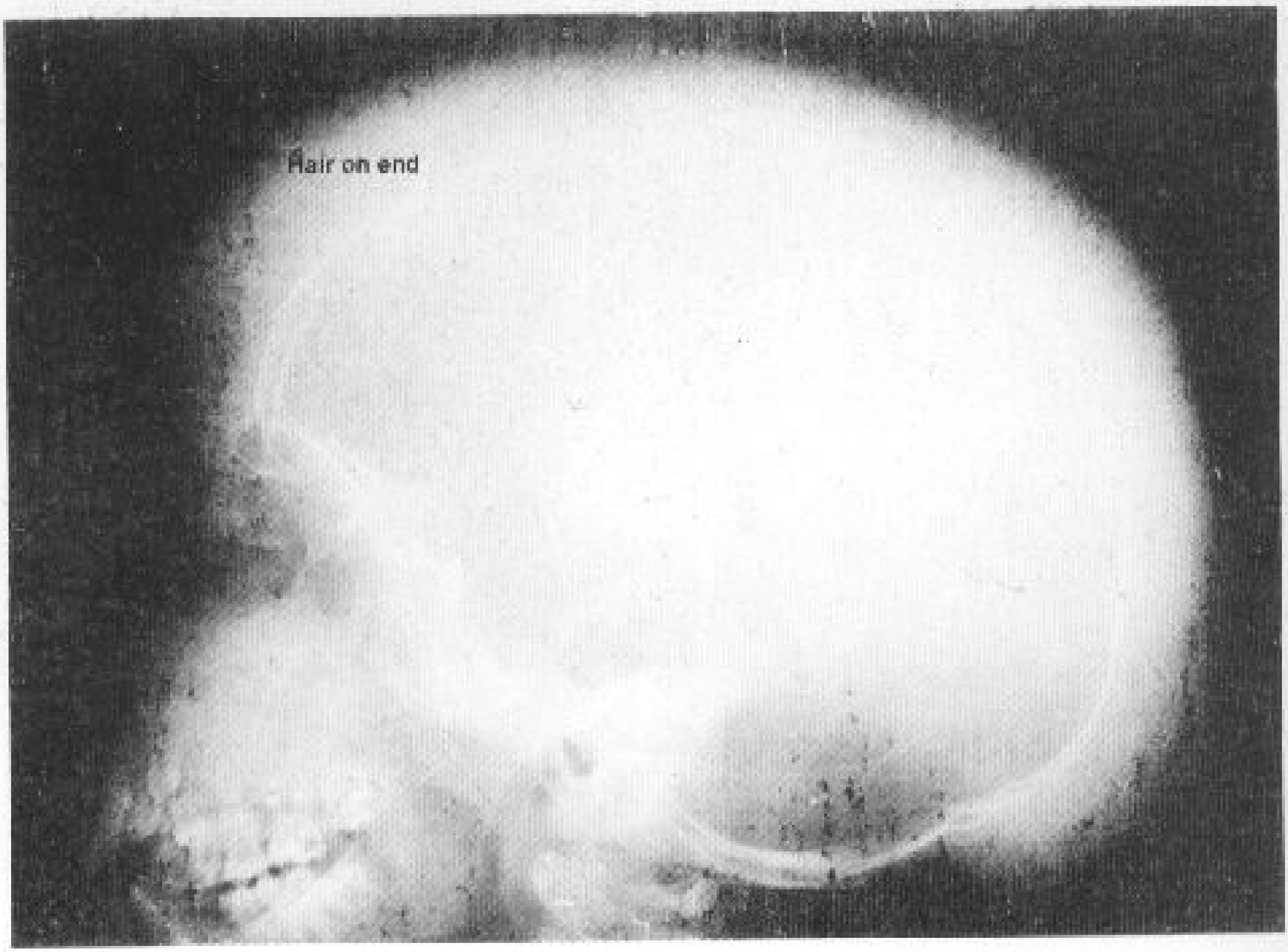

X ray skull lateral view

- Wide diploic space
- Characteristic hair on end appearance

WhiteKnightLove

Freely you have received; freely give.

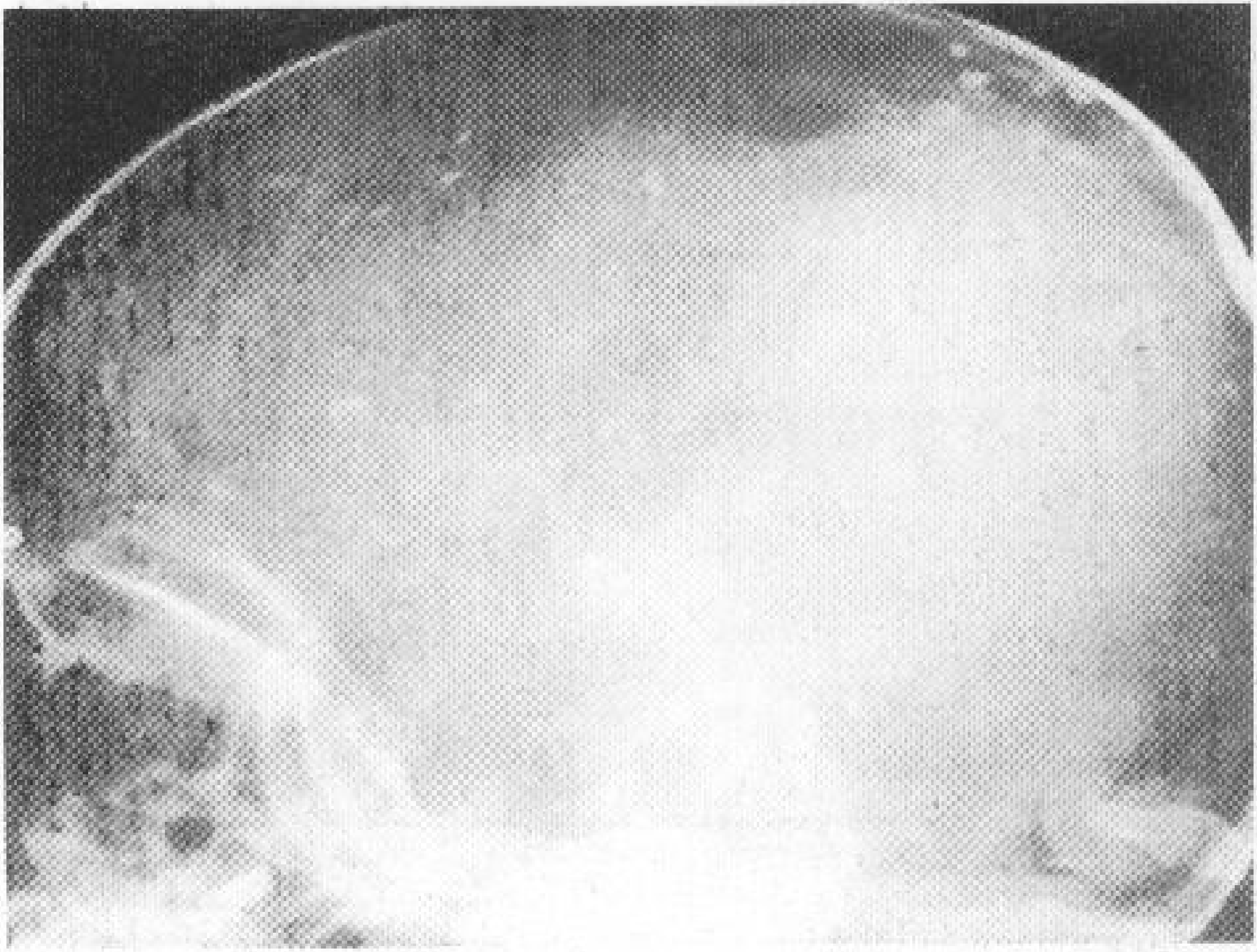

X ray skull lateral view

- Scattered calcification that appear as white dots

Causes of intracranial calcification

. Congenital infections (toxoplasmosis)

. Other infections

 - Meningitis- TB

. Intracranial hemorrhage- subdural hematoma

. Hyperparathyroidism

. Craniopharngioma

WhiteKnightLove

'It is more blessed to give than to receive.

- Congenital hypertrophic pyloric stenosis

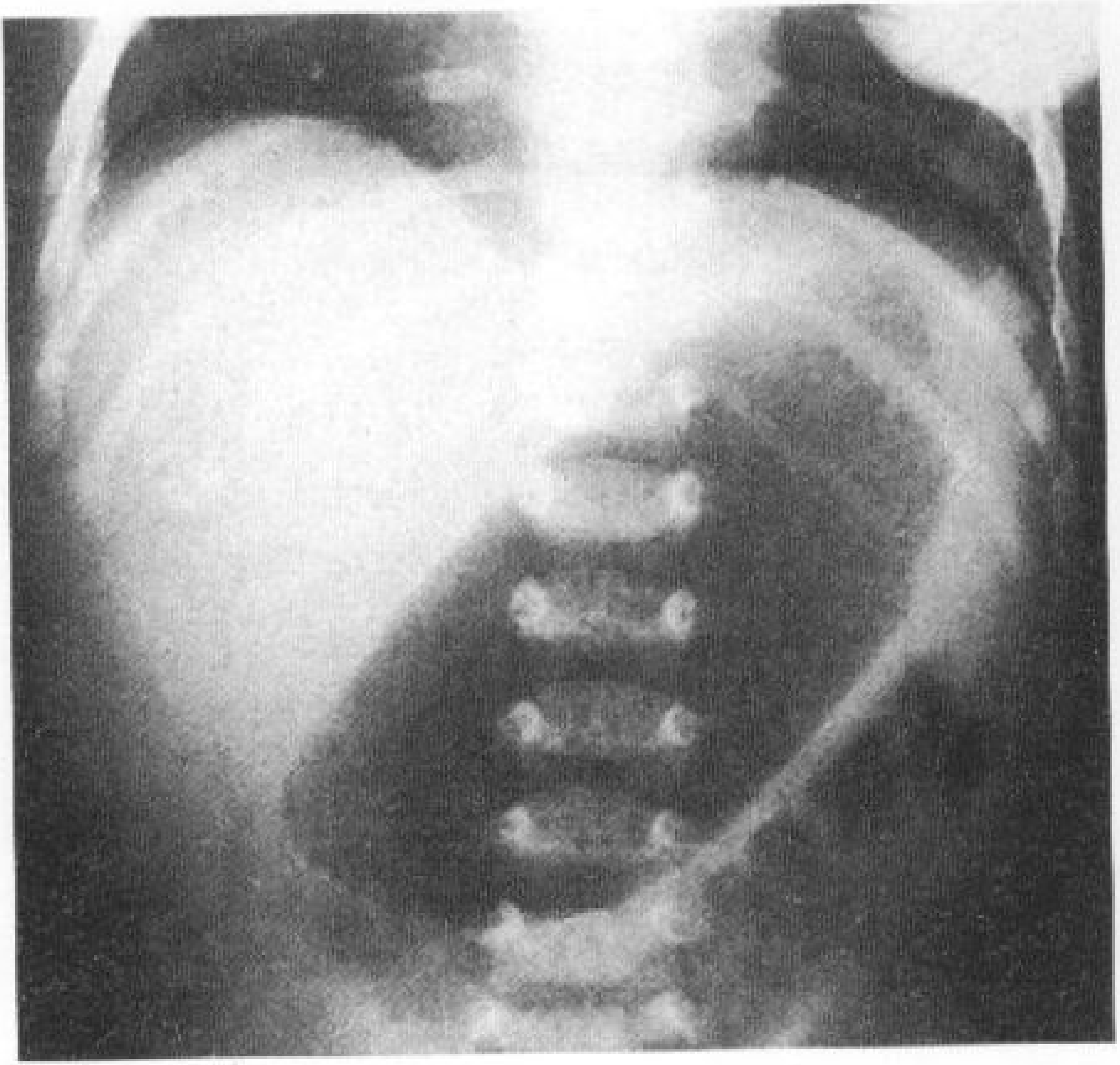

- Plain X ray of the abdomen upright position
- Large gastric air bubble due to pyloric stenosis
- Dilated stomach

WhiteKnightLove

Freely you have received; freely give.

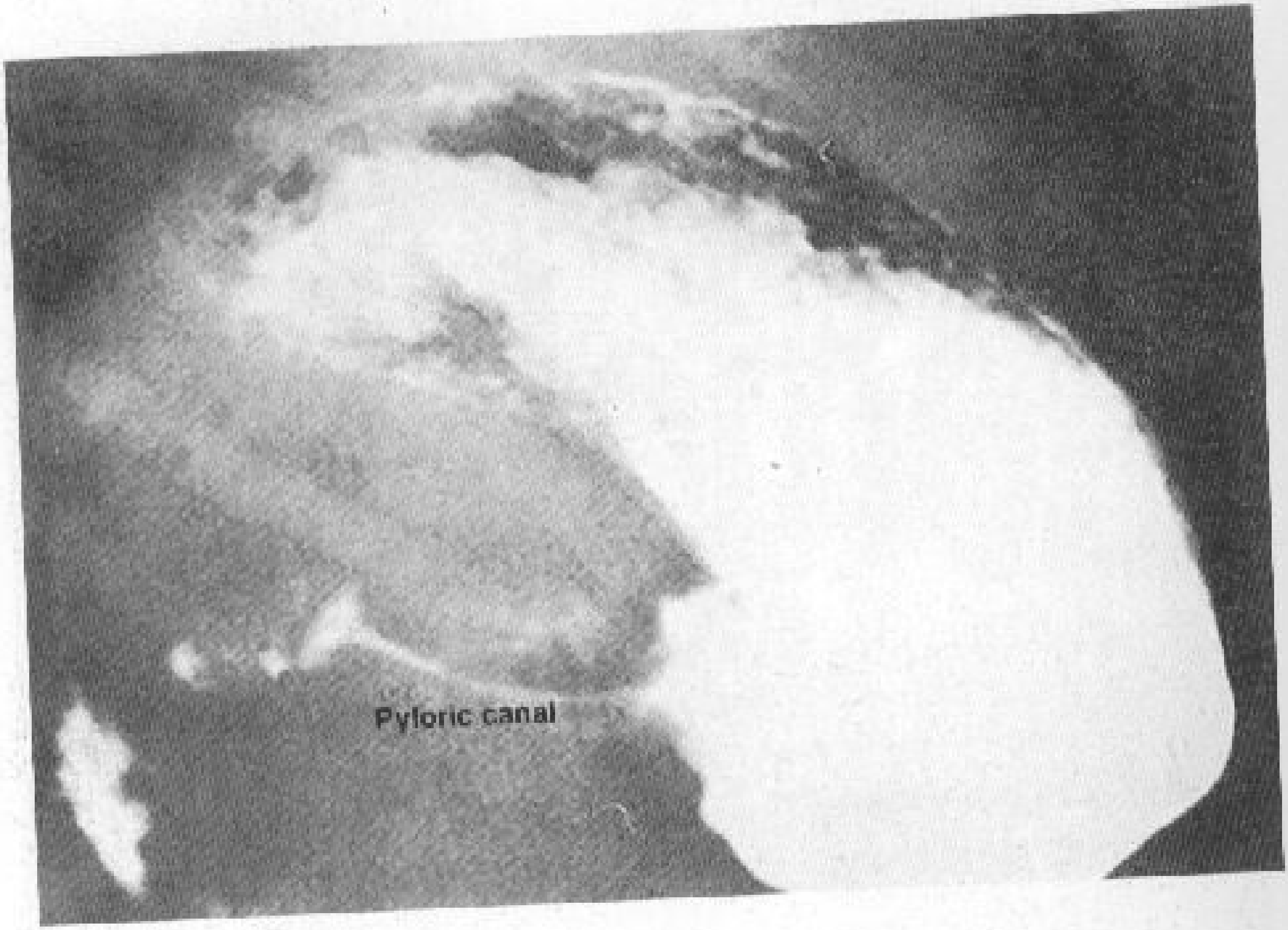

- Barium meal study of the stomach
- Markedly dilated stomach, which is distended by barium
- The pyloric canal is very thin, prolonged (string sign)
- The duodenal cap is umbrella - shaped
- Usually there is delayed gastric emptying

<u>Congenital hypertrophic pyloric stenosis</u>

WhiteKnightLove

'It is more blessed to give than to receive.

- Duodenal atresia (high obstruction)

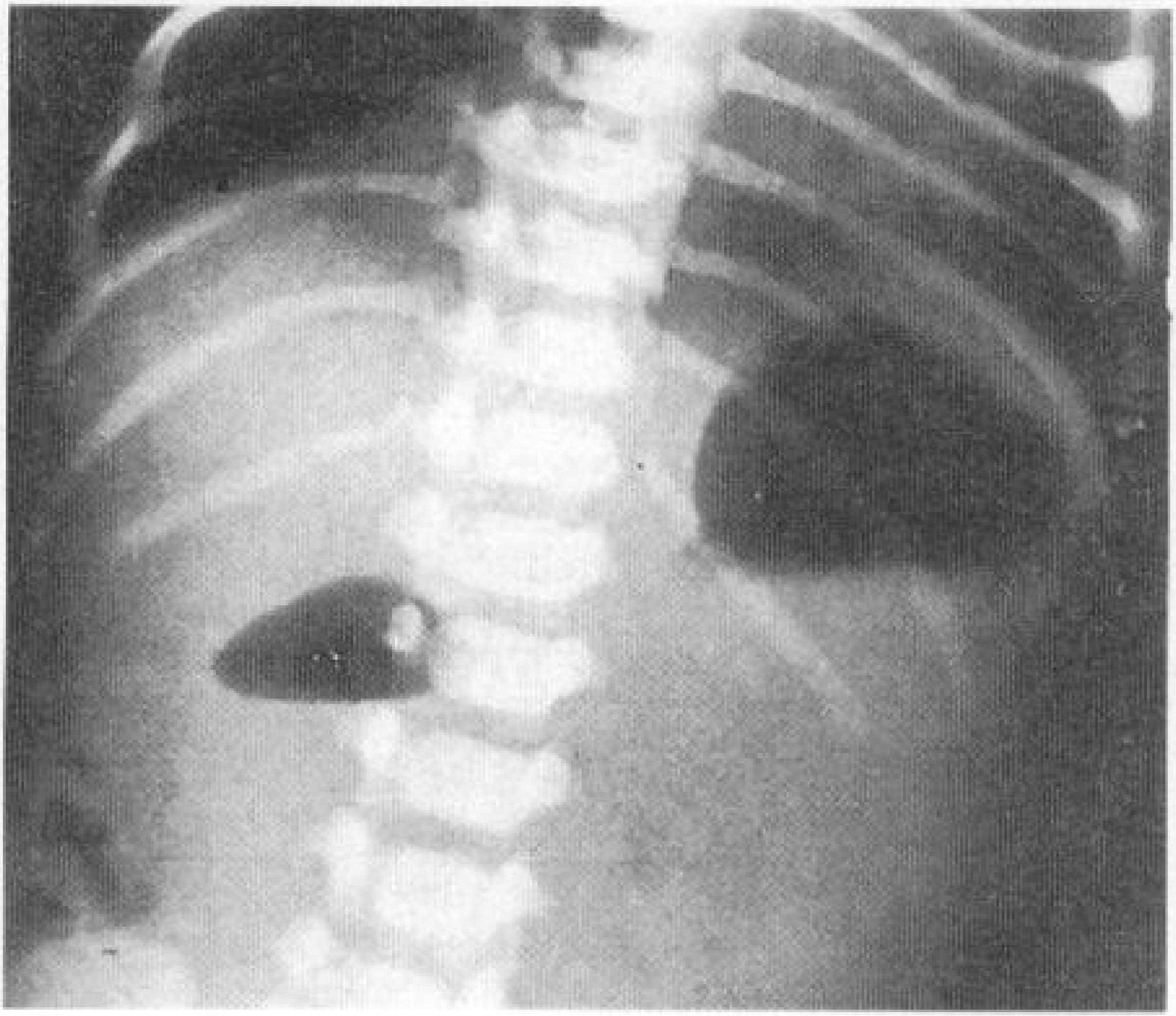

- Plain X ray of the abdomen upright position
- The abdomen is distended by two air and fluid levels (double bubble sign)
- No other gases are seen on the abdomen

WhiteKnightLove

Freely you have received; freely give.

- Intestinal obstruction (low obstruction)

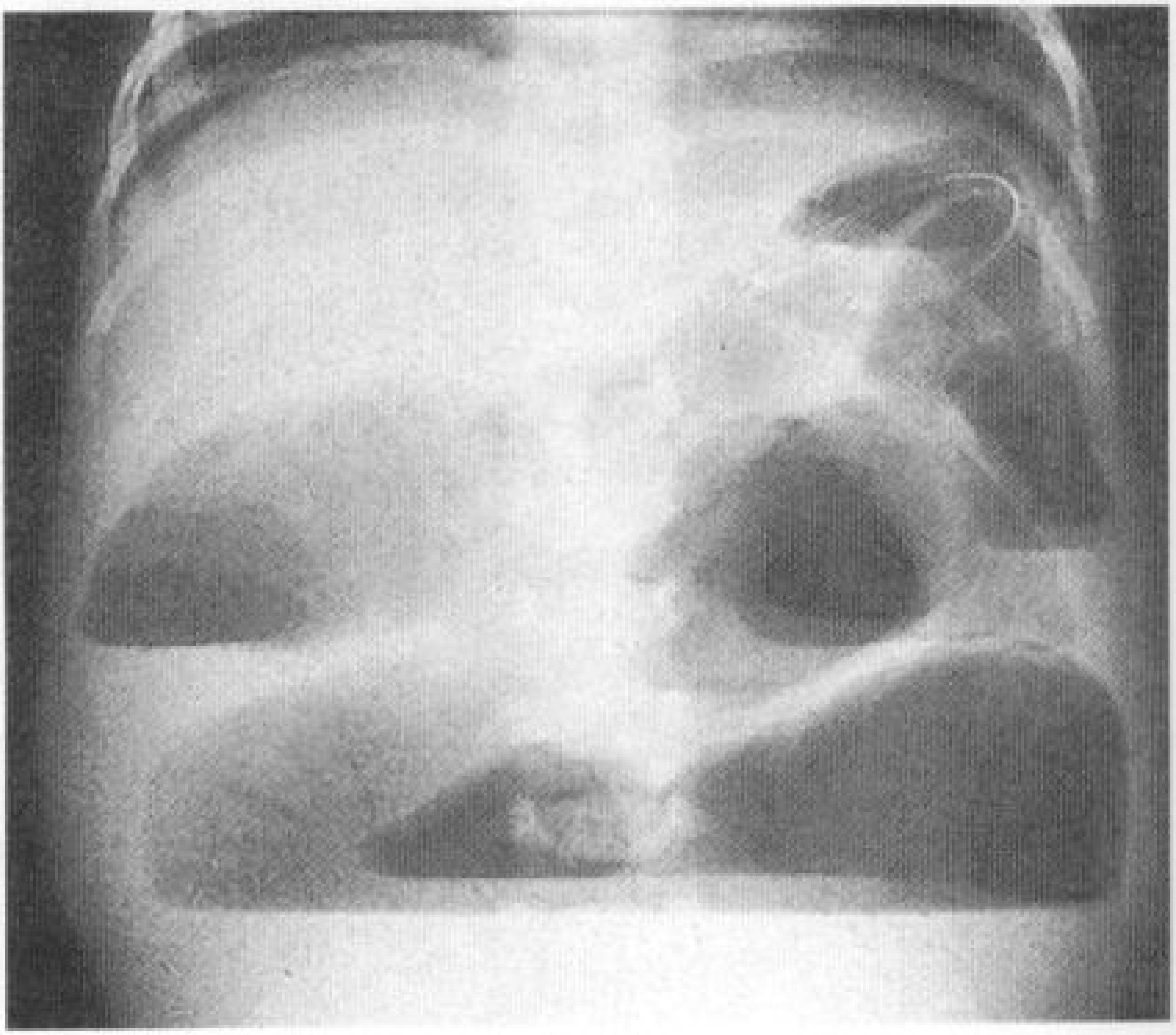

- Plain X ray of the abdomen upright position
- Multiple gas and fluid levels
- Distended intestinal loops

Causes of intestinal obstruction
- Imperforate anus
- Hirschsprung disease

WhiteKnightLove

'It is more blessed to give than to receive.

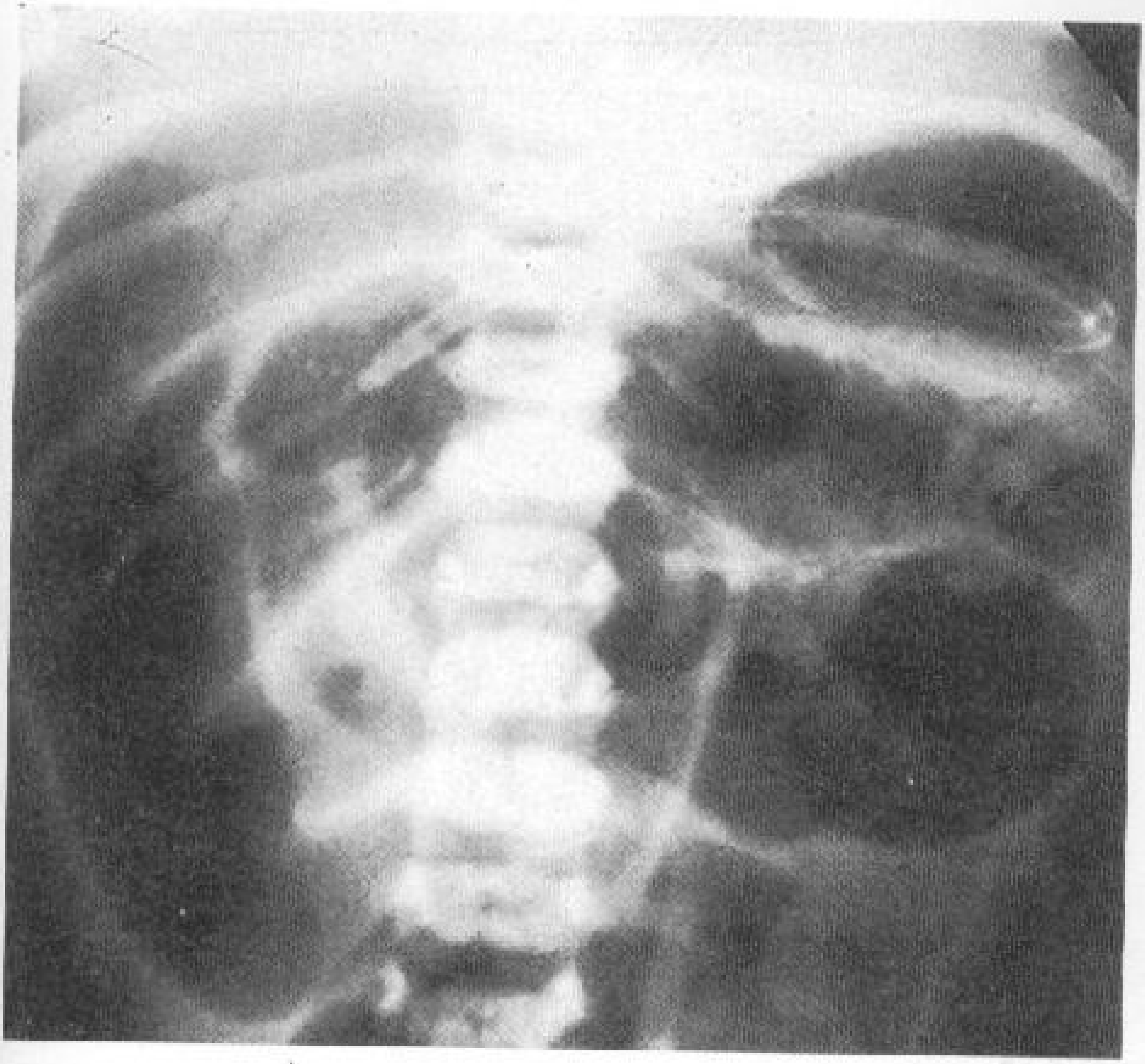

- Plain X ray of the abdomen upright position
- Multiple gas and fluid levels
- Distended intestinal loops

Intestinal obstruction (low obstruction)

WhiteKnightLove

Subtle right pneumothorax.

WhiteKnightLove

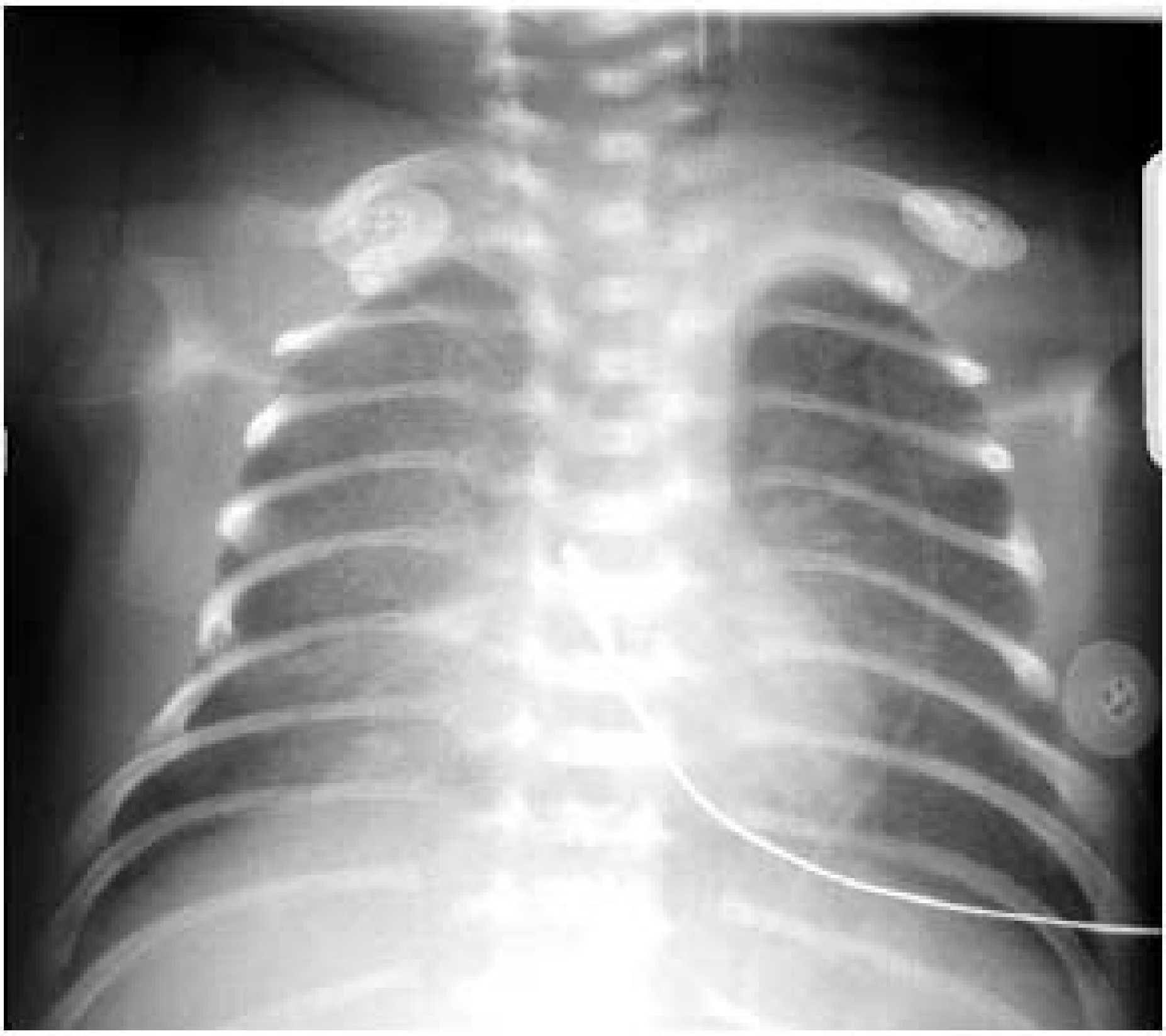

Respiratory distress syndrome. ETT is too high. You must always note the ETT position and reposition it if necessary.

WhiteKnightLove

Freely you have received; freely give.

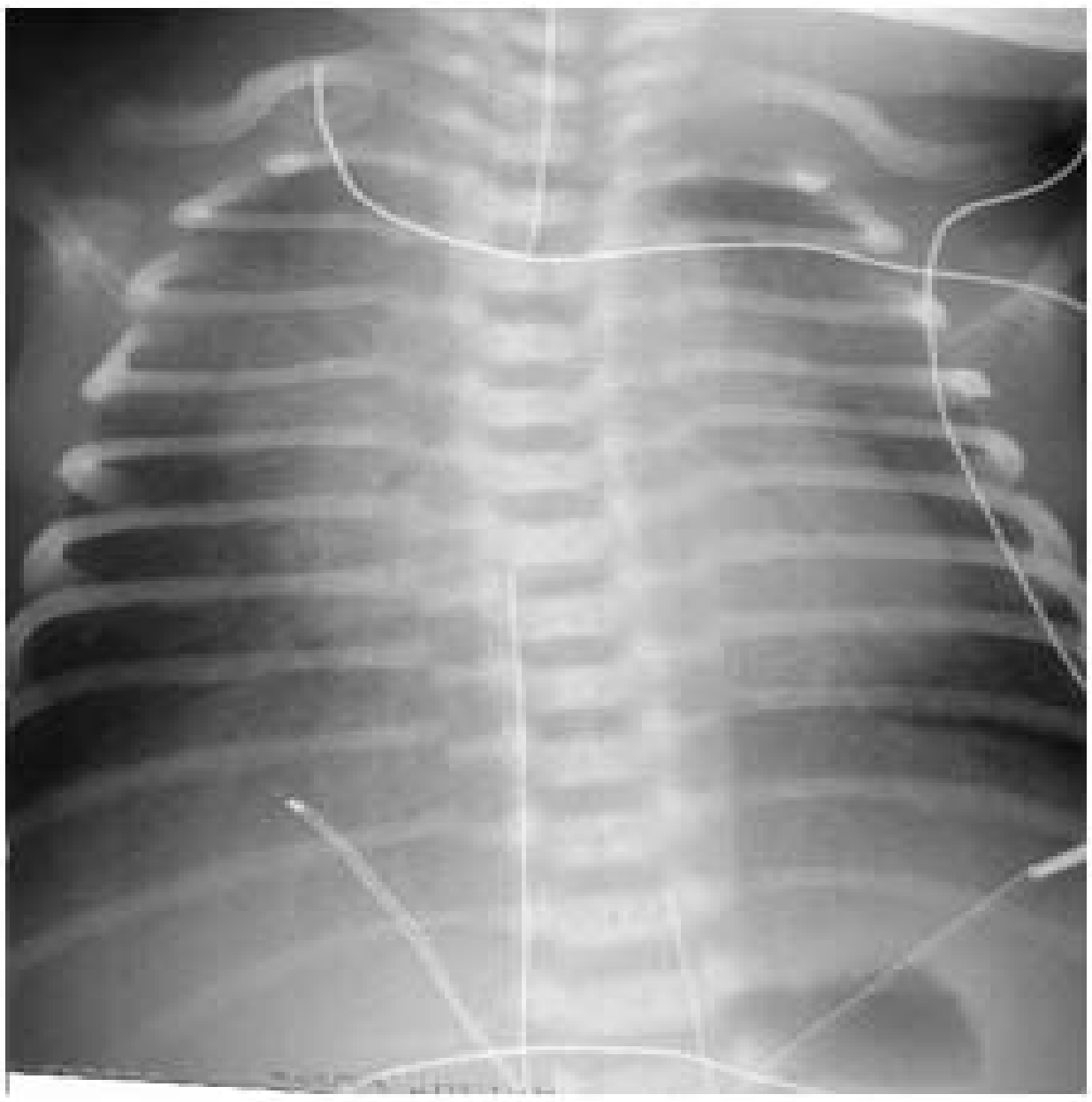

UAC at T11. UVC above diaphragm. How can you distinguish UAC from UVC. You really need to see the umbilicus portion of this radiograph to follow the lines up. Without this information, one can't be certain, but most likely, the line on the patient's left more closely follows the path of the aorta so this is probably the UAC. The line on the patient's right more closely follows the hepatic vein so this is probably the UVC.

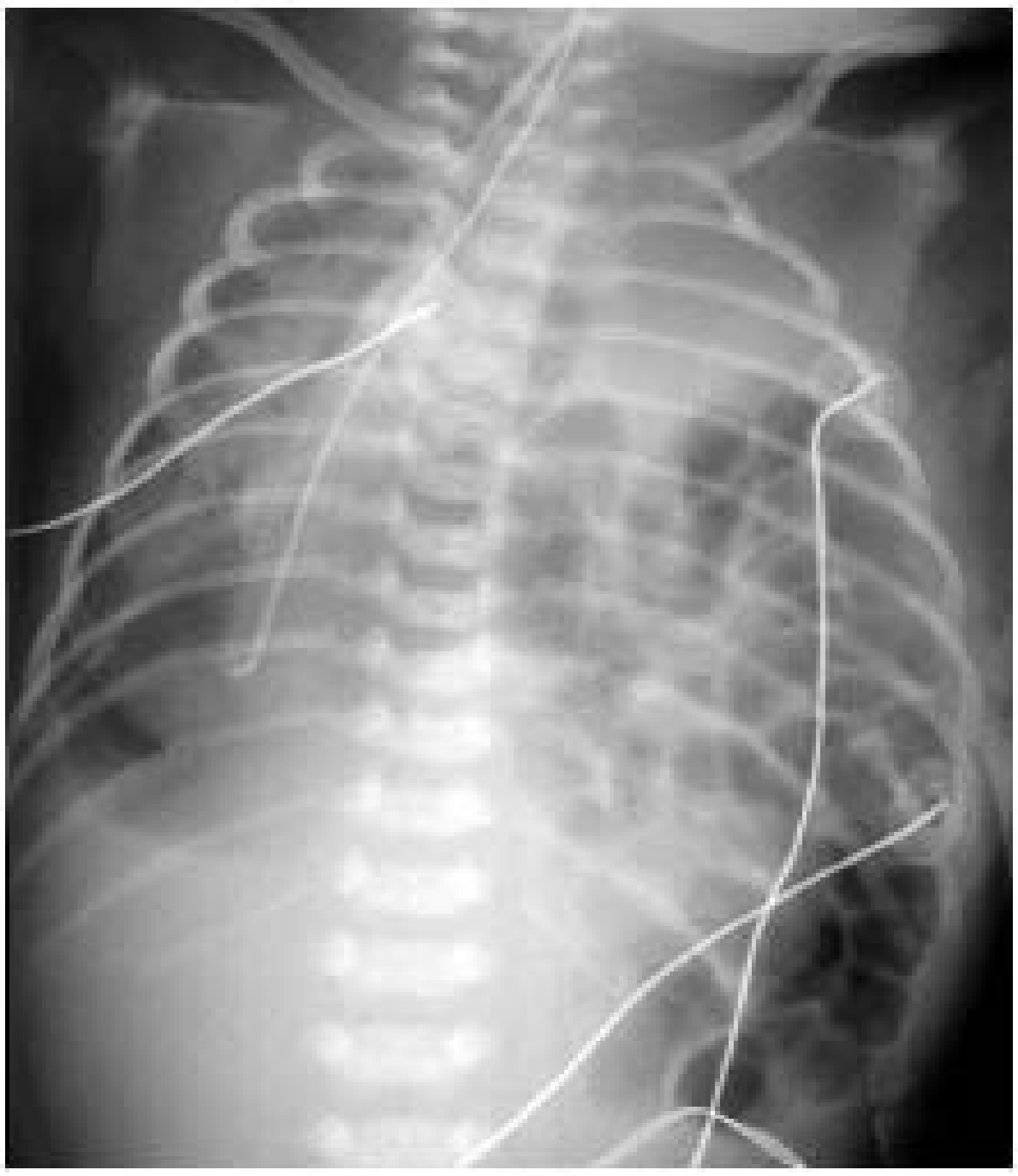

Left diaphragmatic hernia. There is also a small right pneumothorax, but this is difficult to see since bowel gas overlies it.

WhiteKnightLove

ETT too low. It should be repositioned.

Pneumatosis intestinalis. Note the air visible in the bowel wall. The air dissects the bowel wall giving it a double lined appearance (ie., railroad tracks without the ties). Necrotizing enterocolitis.

WhiteKnightLove

Freely you have received; freely give.

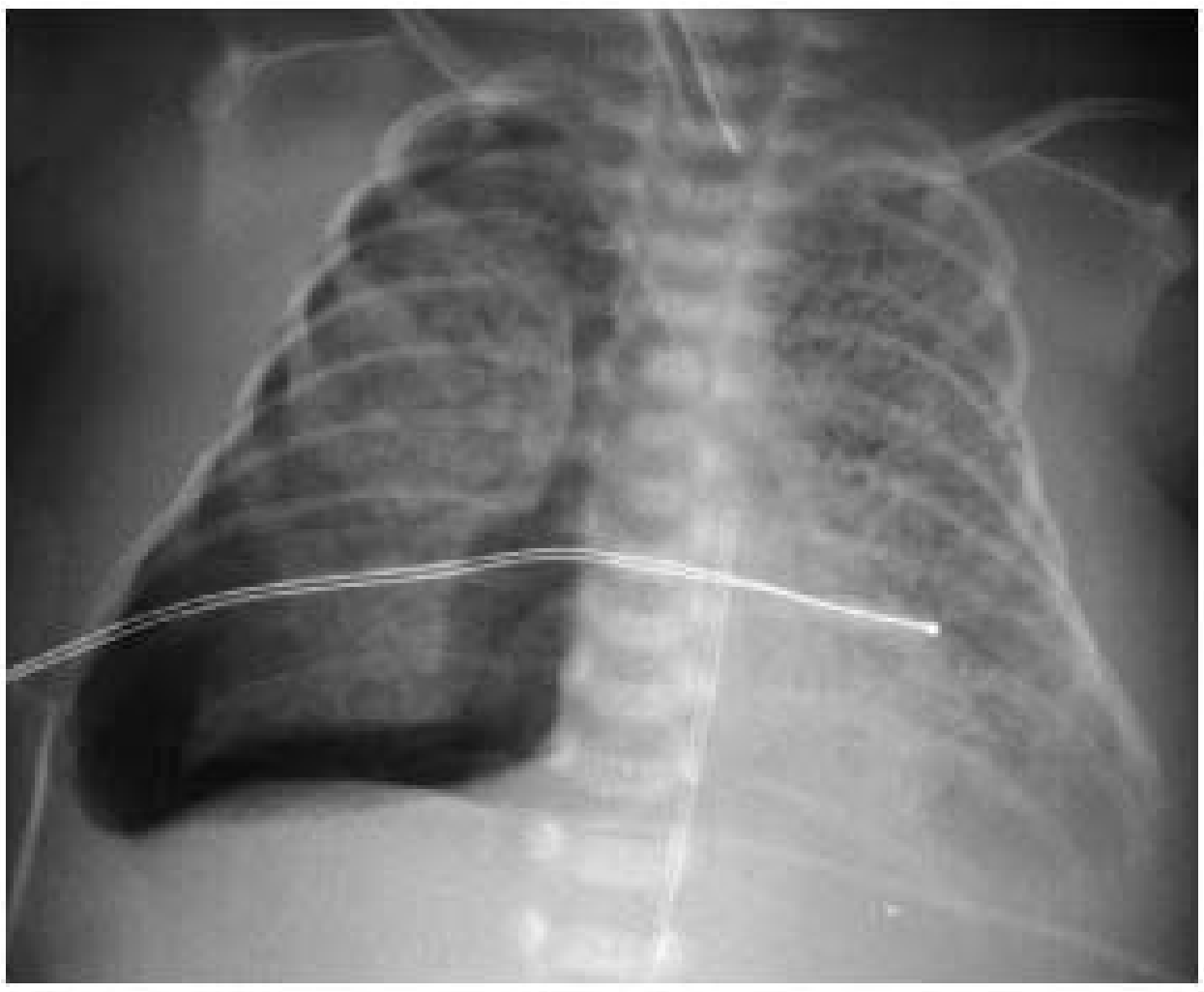

Right pneumothorax. Pulmonary interstitial emphysema. UAC OK at T7.

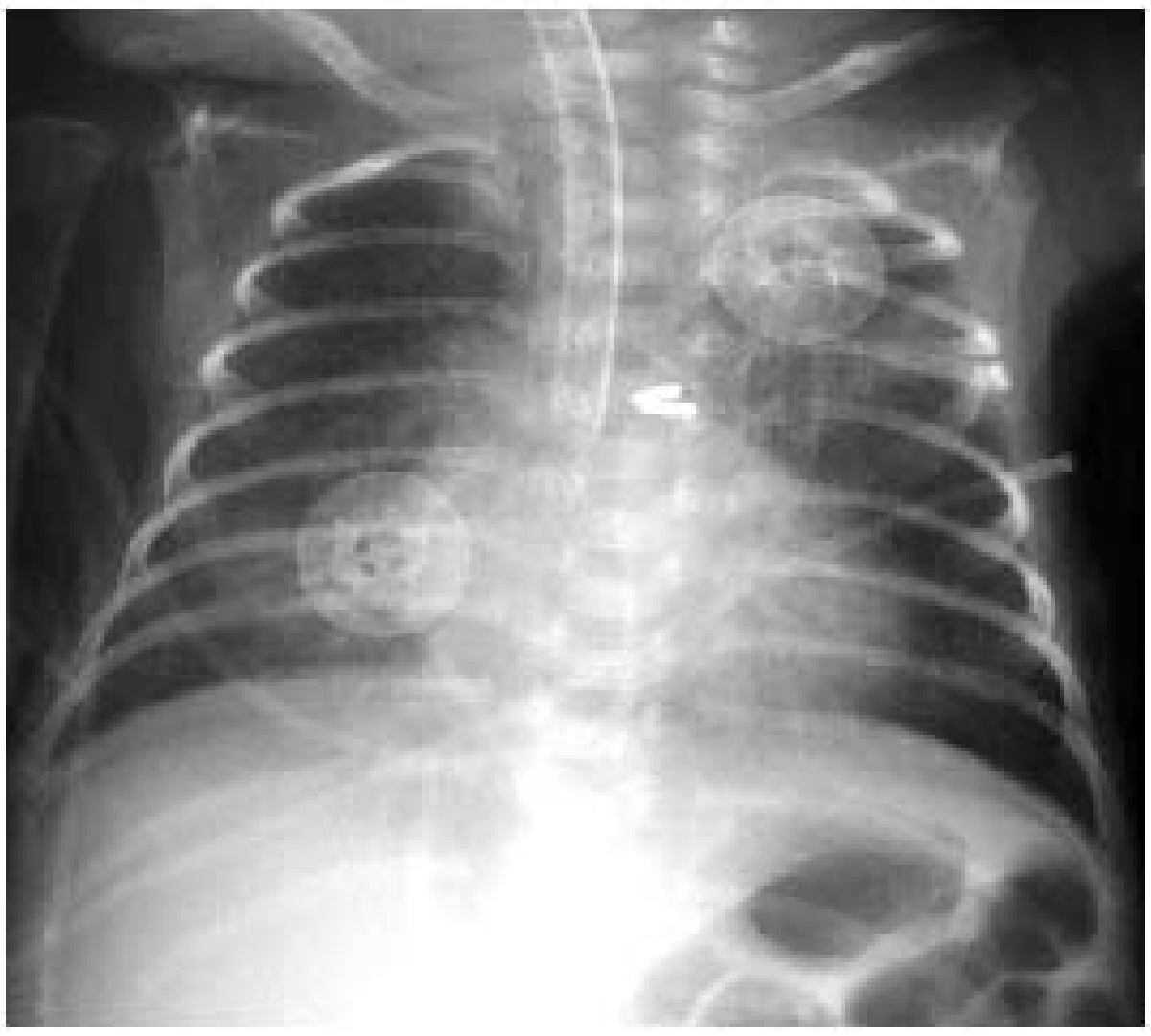

ETT in right mainstem. Too low. Reposition it.

WhiteKnightLove

Pneumomediastinum. Note how the thymus is elevated (pushed up by mediastinal air), most visible on the right. There is also a small right pneumothorax.

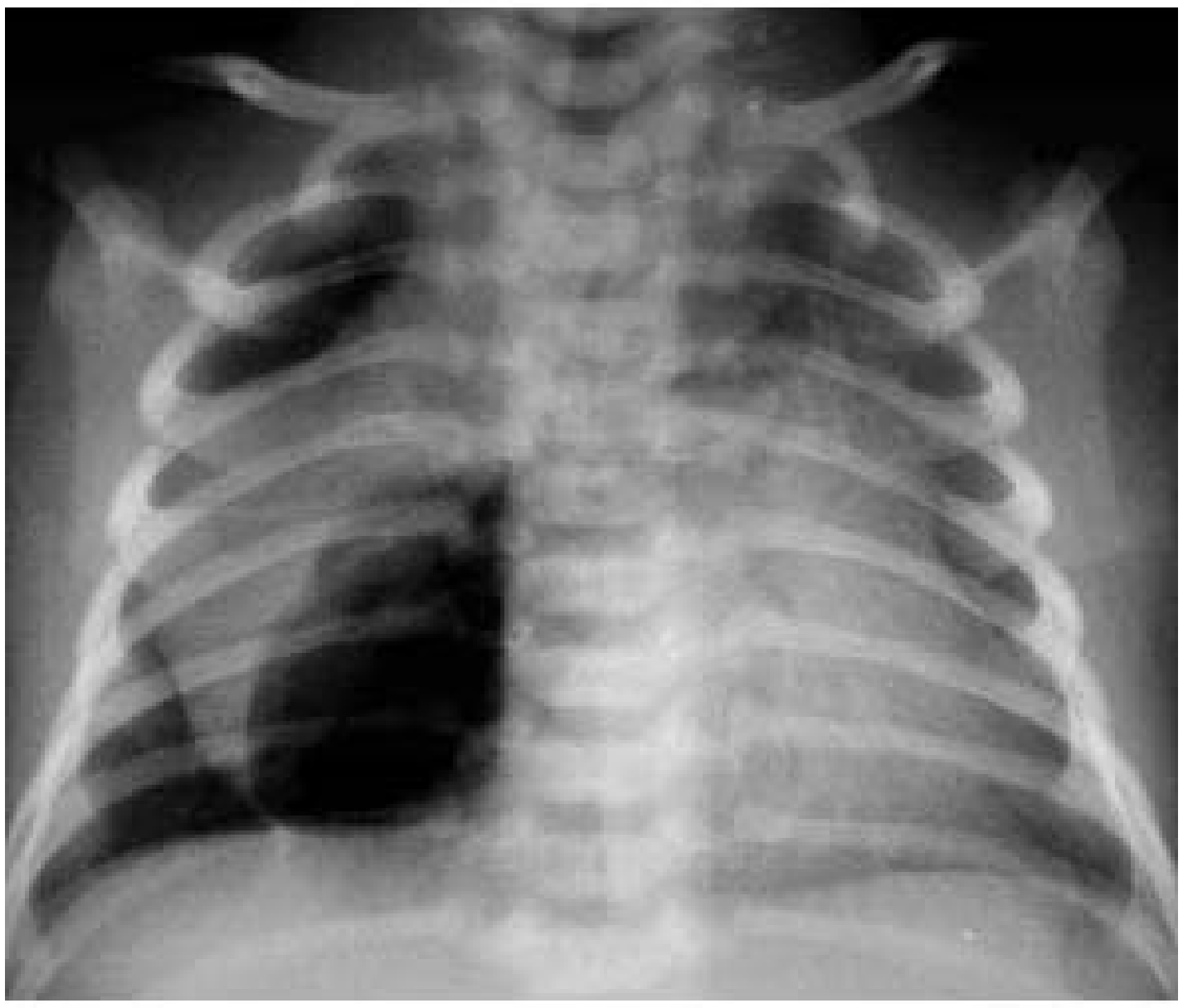

Right pneumothorax.

WhiteKnightLove

Freely you have received; freely give.

Pneumatosis intestinalis. Note the double linear density of the bowel wall indicative of air within the bowel wall (intramural air). There are also subtle air densities over the liver. This suggests that there is air in the portal circulation (intraportal air). Both findings indicate necrotizing enterocolitis.

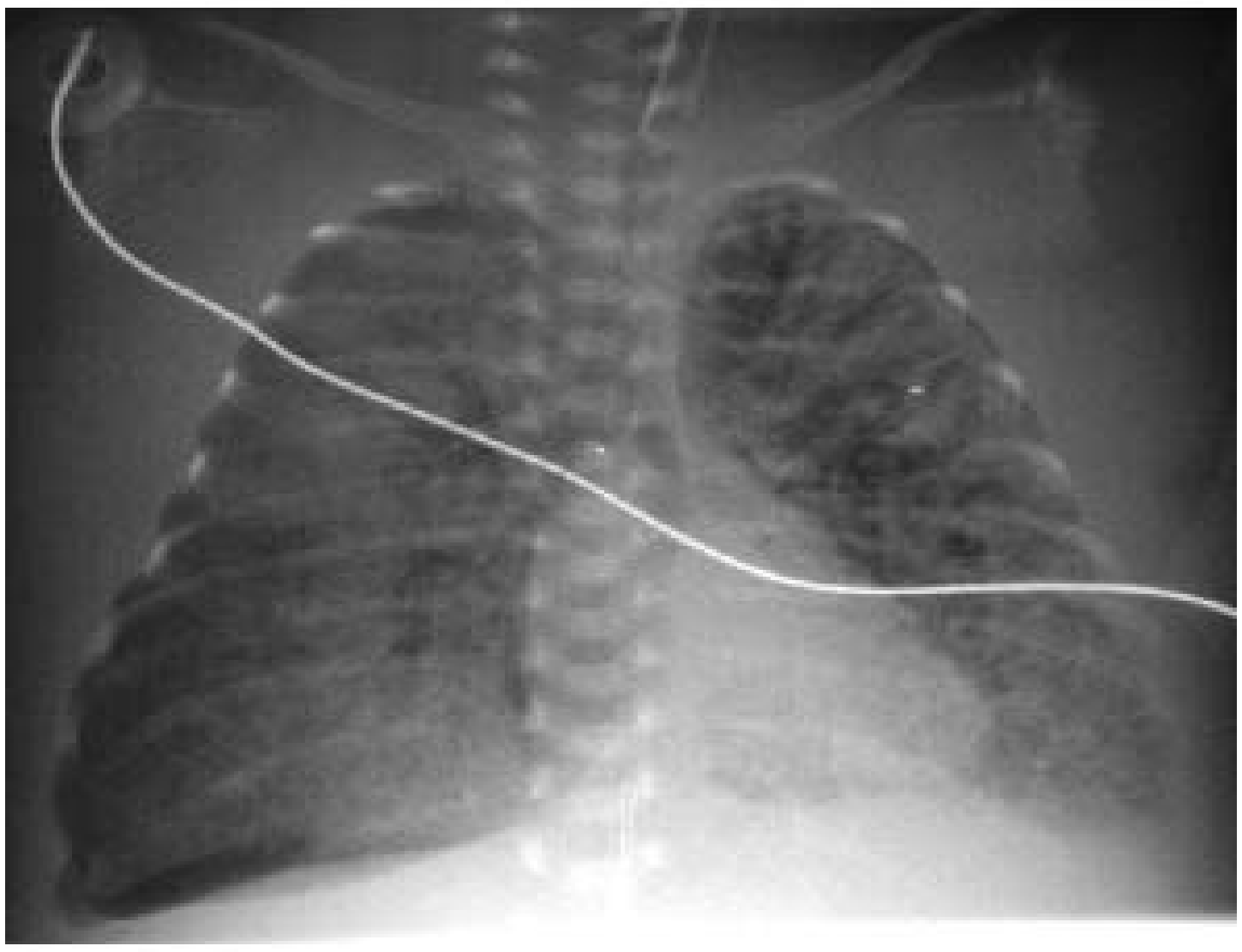

Pulmonary interstitial emphysema. ETT too high. UAC just above diaphragm.

WhiteKnightLove

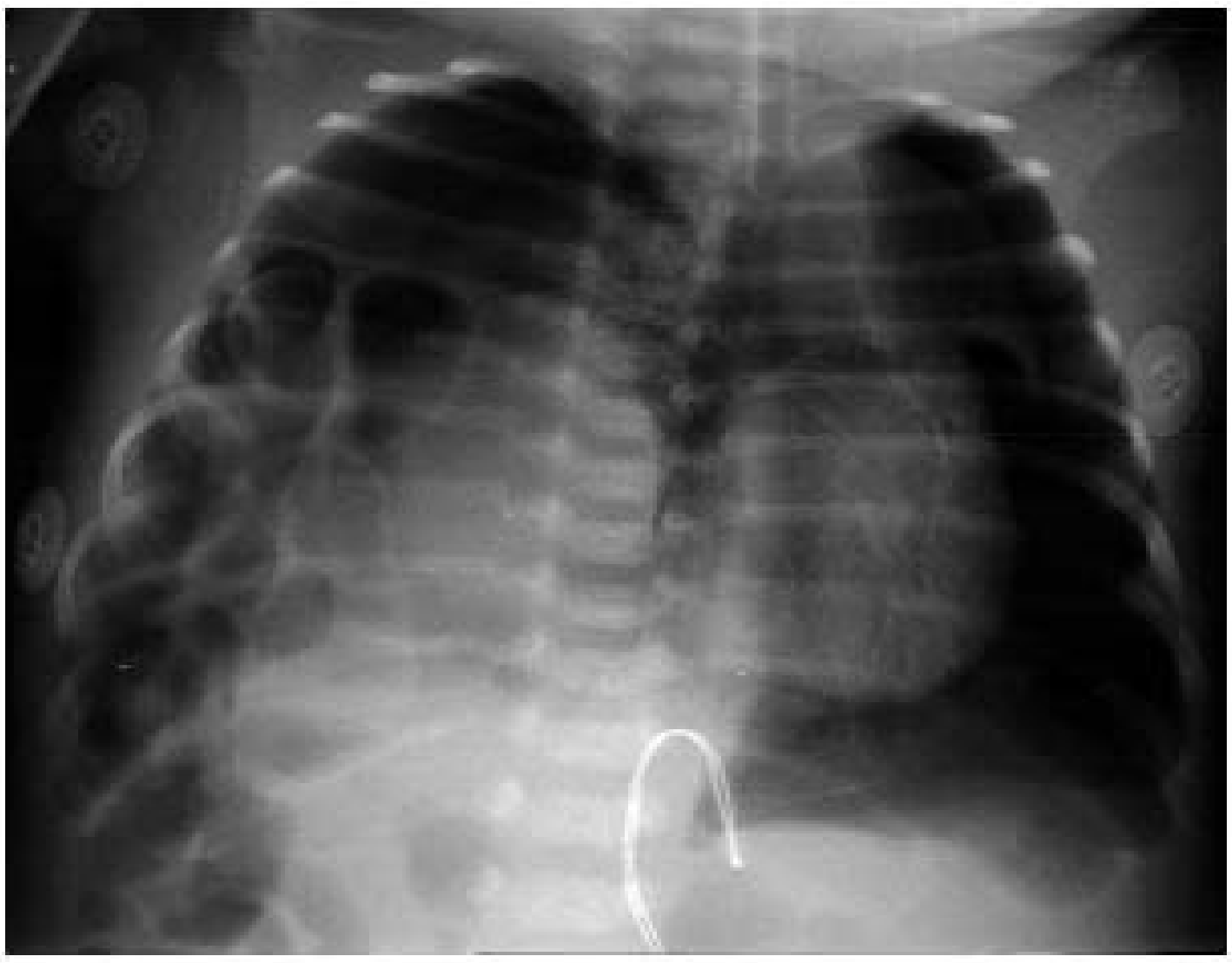

Right diaphragmatic hernia and left pneumothorax.

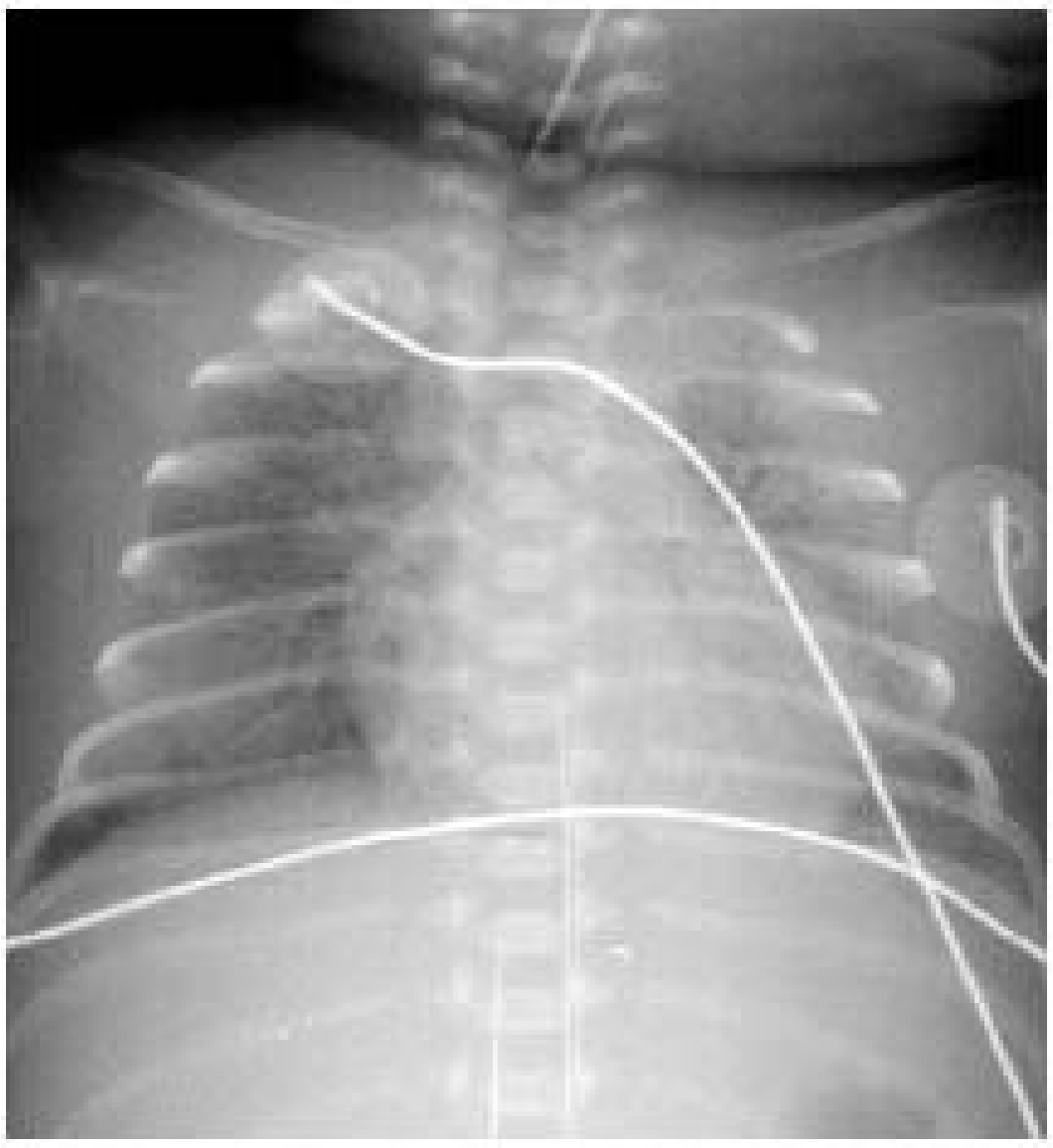

Respiratory distress syndrome. ETT too high. UVC in liver on right.

WhiteKnightLove

Freely you have received; freely give.

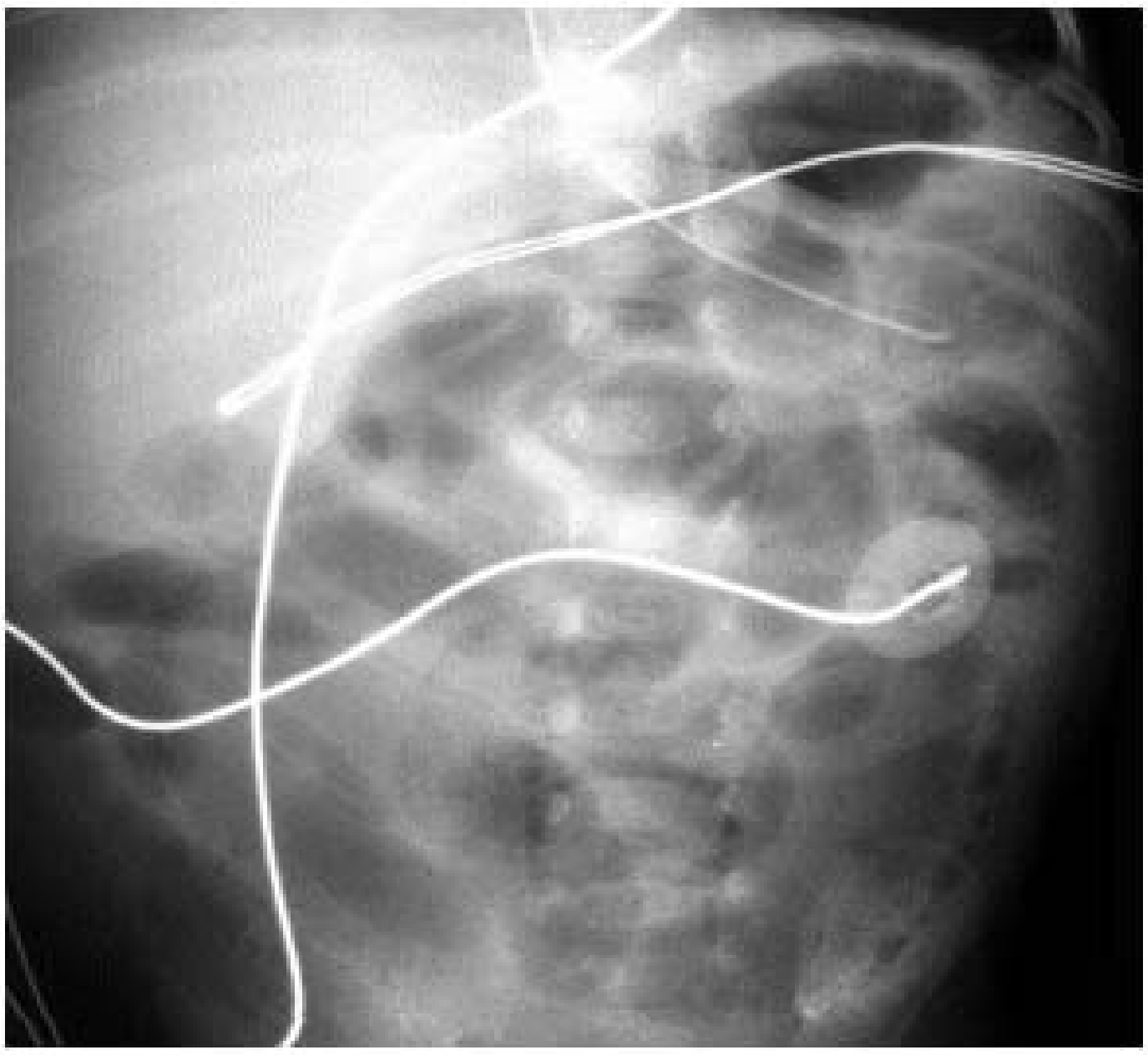

Pneumatosis intestinalis. Very obvious case. Tremendous amount of air in bowel walls.

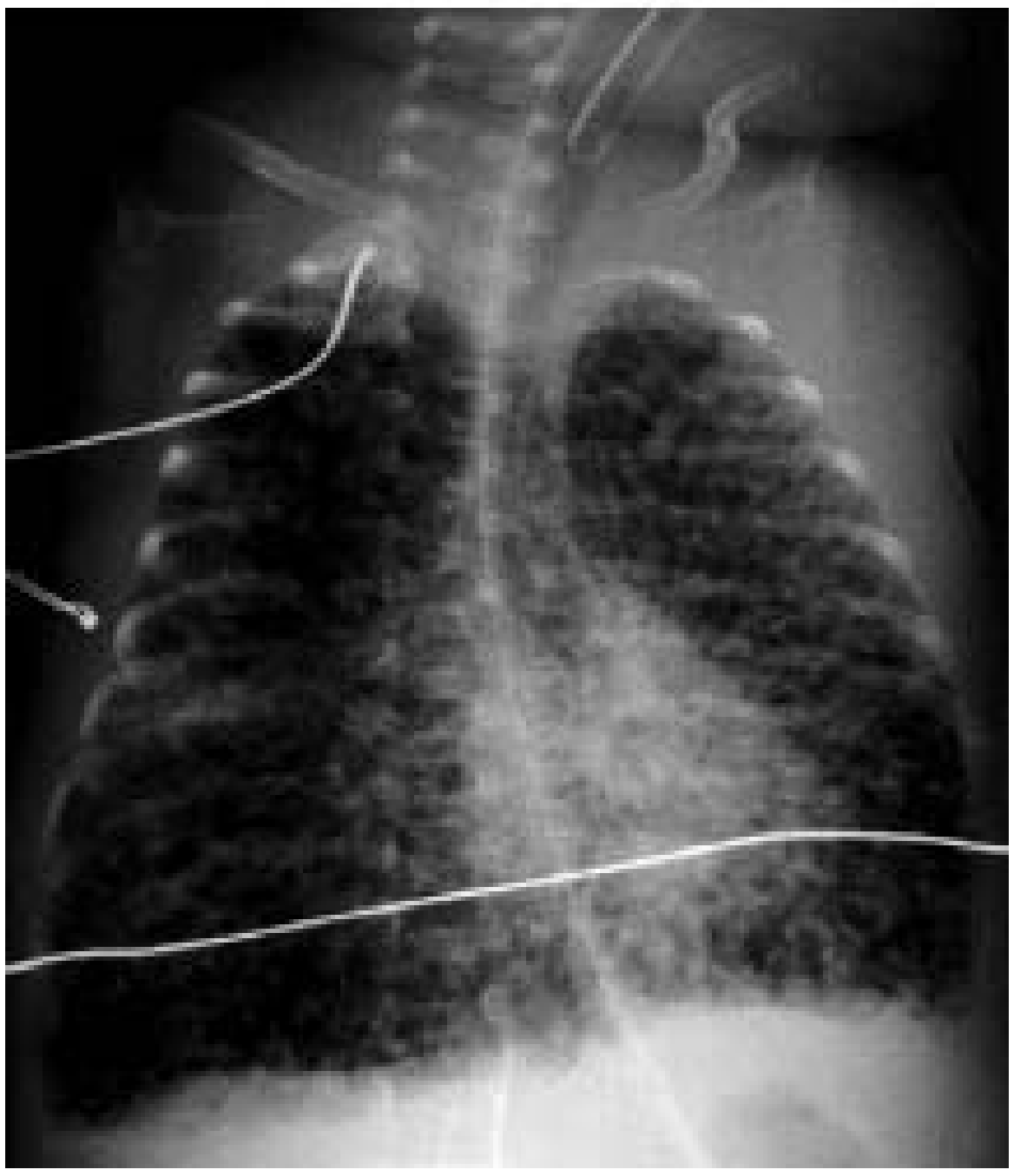

Name three things wrong with this x-ray? 1) Severe pulmonary interstitial emphysema. 2) ETT too high. 3) UAC too low.

WhiteKnightLove

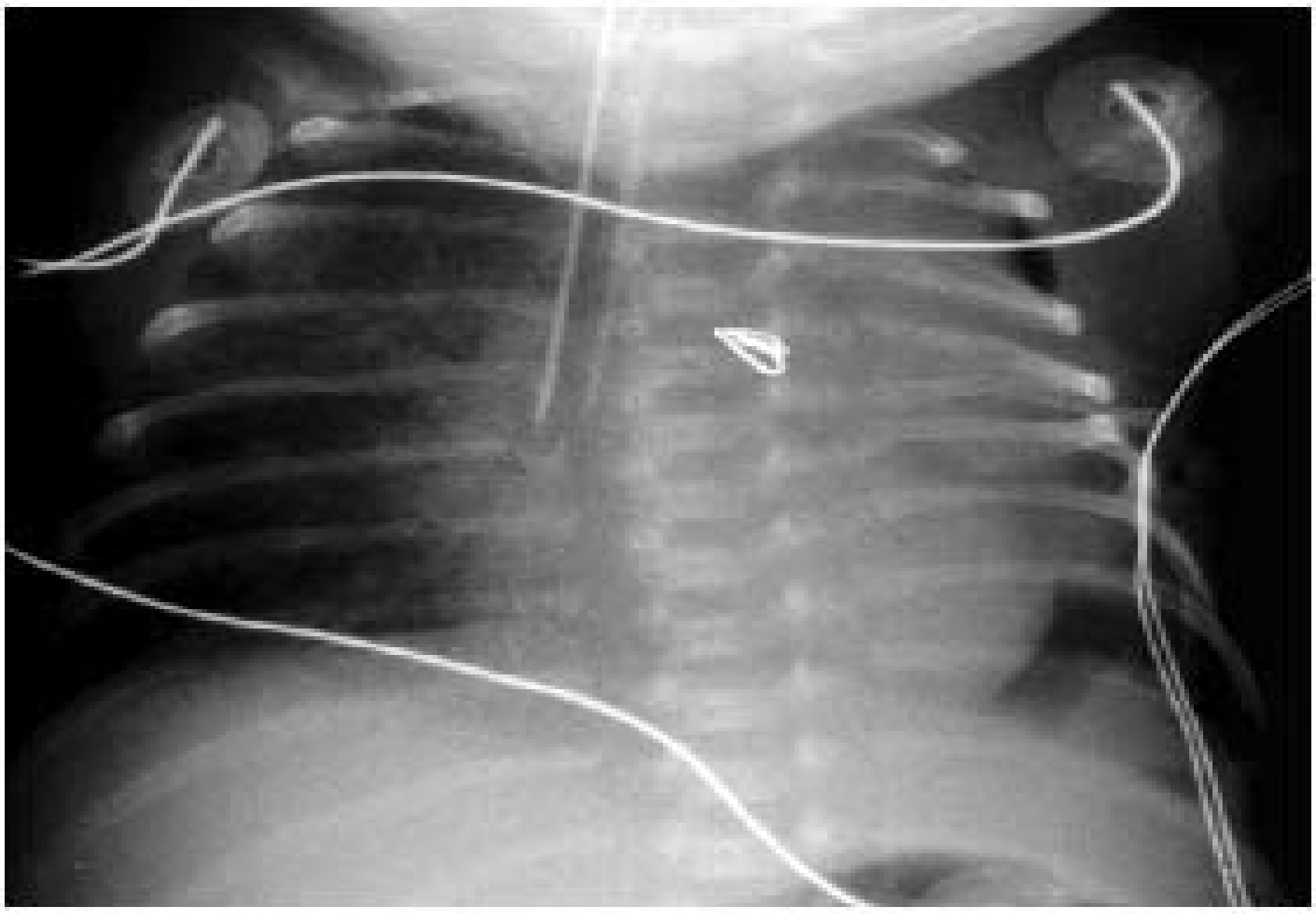

ETT too low. Left pneumothorax.

Written questions

1. What are the causes of noisy Respiration?
2. What are the causes of croup ?
3. What are the DD of croup ?
4. What are the causes of recurrent wheezes in infants& childhood?
5. What are the causes of acute wheezes in infants& childhood?
6. What are the DD wheezy infants ?
7. What are the causes slowly resolved pneumonia ?
8. What are the complications of pneumonia ?
9. What are the Differential Diagnosis of Childhood Asthma ?
10. What are the *classification of asthma*?
11. What is the meaning of DOTS ?
12. What is the fade of pulmonary TB ?
13. Diagnosis pulmonary TB?
14. What is the clinical value of Tuberculin skin test?
15. Interpretation of Tuberculin skin test?

Freely you have received; freely give.

16.. Treatment of tuberculosis ?

- **Oral questions**

1. What is the definition of croup ?
2. Causes of hepatomegaly in chest diseases ?
3. Differentiation between bronchiolitis & bronchial asthma ?
4. What are the causes cyanosis ?
5. Differentiation between hemoptysis & hematemesis ?
6. What are the criteria of respiratory distress ?
7. What are the types & causes of clubbing ?
8. What is cutoff point of fast breathing?
9. What is the surface anatomy of the RT lung ?
10. What is the character of normal and abnormal breath sounds ?
11. What is the definition of -chest indrawing
    - " retraction
    - Severe pneumonia

WhiteKnightLove

Problems:-

1) A 1 year- old infant presented with an acute onset of cough , choking , and respiratory distress . O/E :- RR 45 and wheezes . No family history of asthma ,and no one at home ill .The older sister stated that they were both playing and had eaten sunflower seed .

A) What is the most likely diagnosis ?

B) What are the differential diagnoses of this case ?

C) How you cam mangled the case ?

2) A3years old child presented by stridor and barking cough .O/E –there is mild respiratory distress ,tachypnea respiratory stridor (croup), temperature 38.5 ^{o} c . Chest reveals scattered rhonchi .

A) What is the most likely diagnosis ?

B) What is the most likely pathogen responsible for this disease ?

C) How you can managed the case ?

3) A3years old child ,in whose mother tuberculosis was just diagnosed , has positive PPD skin test result. A chest X ray shows a localized , non specific infiltrate in the peripheral segments of the Rt lobe .

A) What is the most appropriate test to confirm the diagnosis ?

B) How you can managed the case ?

C)What is the fade of this pulmonary lesion ?

4) Seven month old Mariam was bought to the clinic because she is coughing and seems very sick. She has no general danger signs , no diarrhea , no fever , no throat or ear problems. RR 55 , no chest indrawing and no stridor or wheeze

A) How you can assess the case ?

B) How you can classify the case ?

C) How you can mange the case ?

5) Basem is 18 months . He weights 9kg, temperature 37^{0}c . His mother says he has had a cough for 3 days . The mother said that he is able to drink and has not vomited anything . He has not had convulsions and is not convulsing now .O/E :- He was not lethargic or unconscious .RR 38 . No chest indrawing .Neither stridor nor wheezes were heard .

A) How you can assess & classify the case ?

B) How you can managed the case ?

6) Ahmed is 25 months. His mother says he has had a cough for 3 days . The mother said that he is unable to drink and has not vomited anything . He has not had convulsions and is not convulsing now .O/E :- He weights 9kg, temperature 38 ^{0}c He was lethargic .RR 55 . There is chest indrawing .Neither stridor nor wheezes were heard .

A) How you can assess & classify the case ?

B) How you can mange the case ?

7) A 3 month old girl with history of episodes of paroxysms of cough one month ago . Her mother said that this paroxysms of cough were followed by vomiting and accompanied by intense congestion of the face and sometimes bluish coloration of the face . Cough was associated with inspiratory sound .

HB 10.8 g/dl ESR 5mm in 1st h TLC 22.000 c/cu mm

Neutrophils 16% lymphocytes 82%

A) What is the most likely diagnosis ?

B) What are the differential diagnoses of this case ?

C) How you can managed the case ?

WhiteKnightLove

8) A 6 years old girl presented to emergency room by respiratory distress , cough, and wheezes .O/E :- RR 50 , Temperature 38 ^{o}c , HR 120 .
Chest examination :- Bilateral decrease air entry ,with scattered rhonchi,and coarse crepitations . Heart free. The girl is stunted and under weight . Past history of repeated hospitalization with the same problem .

A) How can you assess the severity of the attack ?

B) What are the treatment of this case ?

C) What are the advices to this case after discharge ?

- X ray chest with contrast of newborn .
- PA view
- The patient is centralized .
- Shifted mediastinum to the opposite side .

- The right side showed coils of air filled small bowel

Congenital diaphragmatic hernia

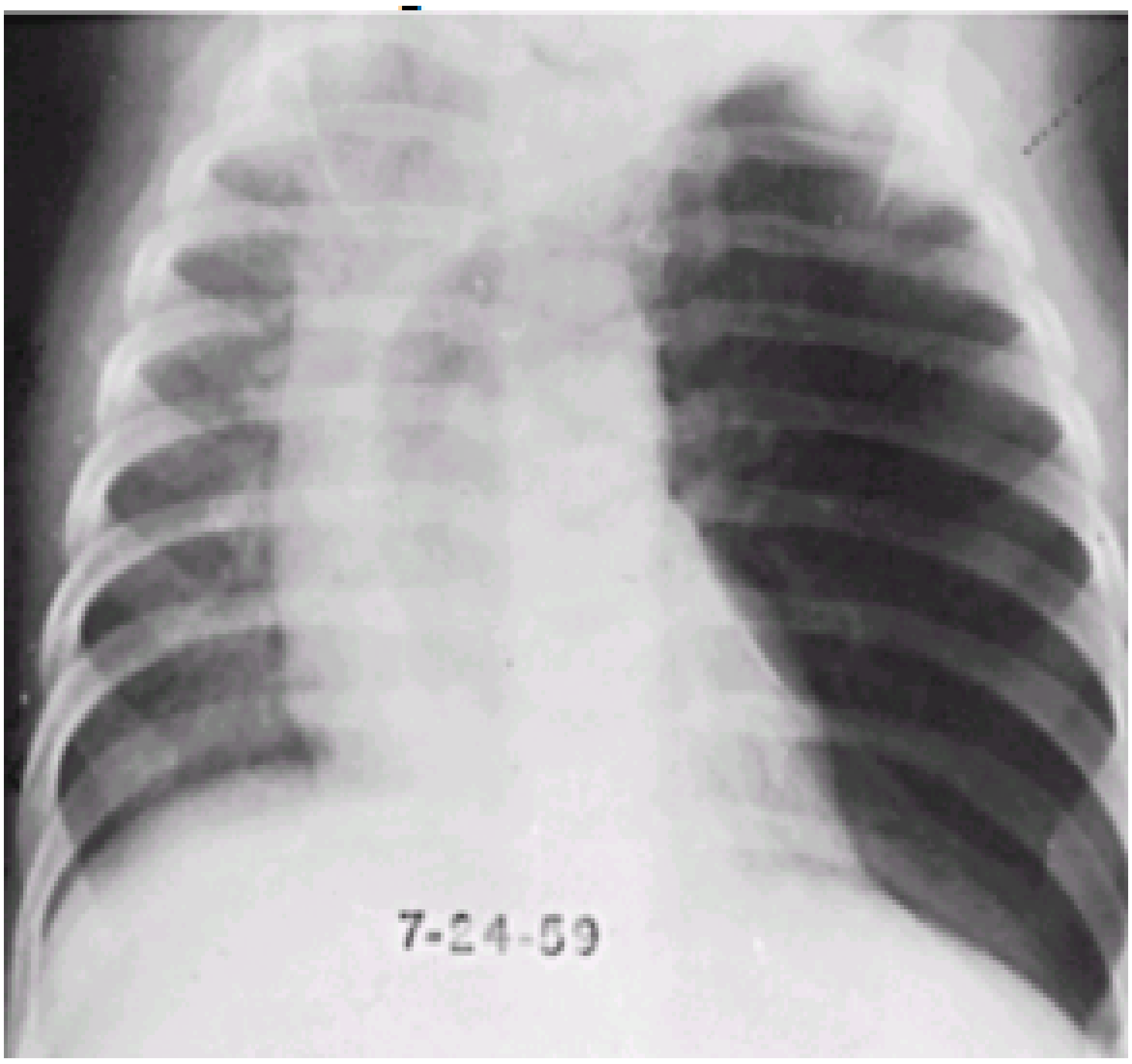

- Plain X ray chest & heart
- PA view
- The patient is not centralized .
- The mediastinum to the opposite side .
- Left upper lobe emphysema with encroachment on lower lobe and mediastinum shifted to the opposite side .

Left upper lobe emphysema.

WhiteKnightLove

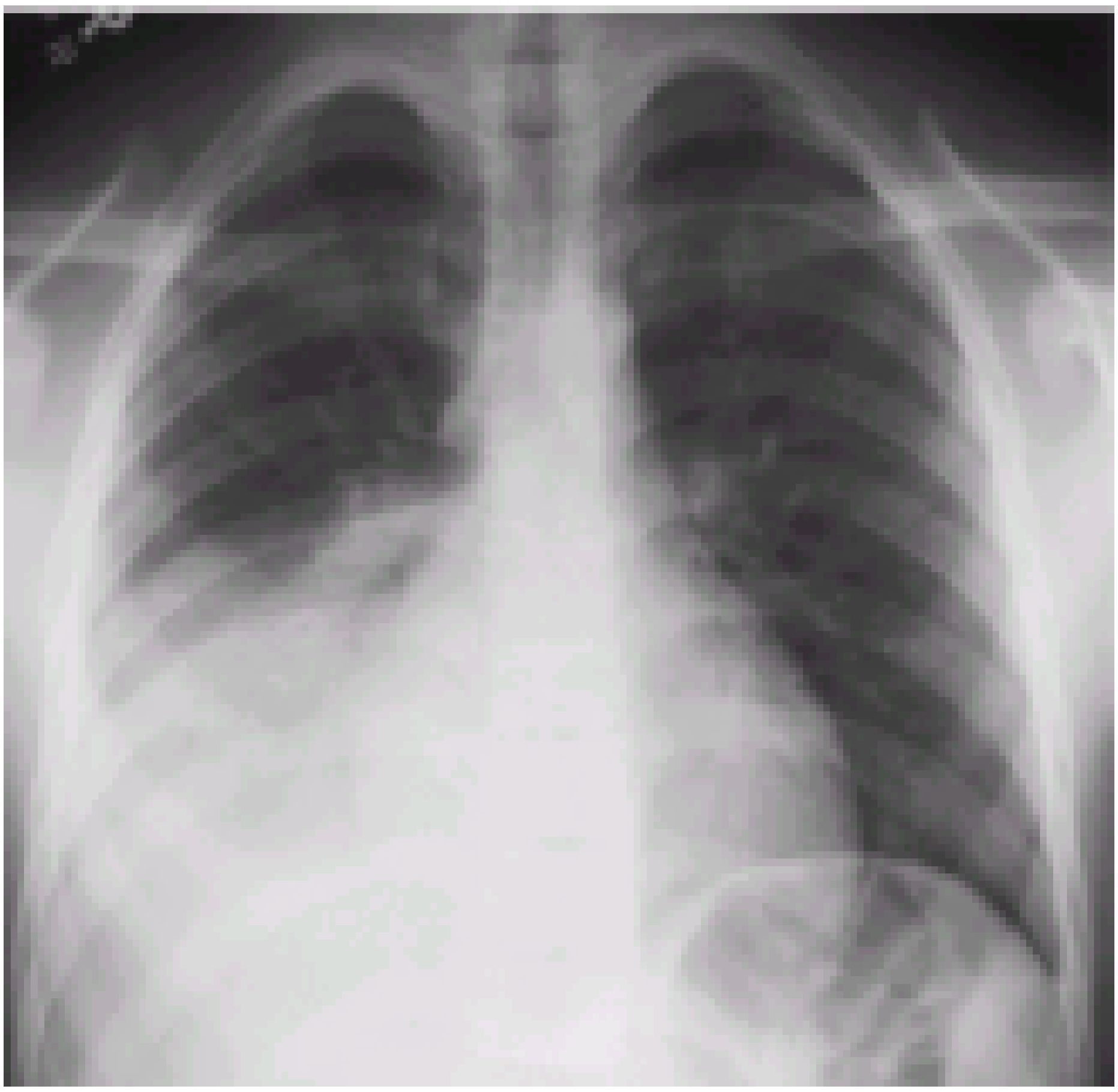

- Plain X ray chest & heart
- PA view
- The patient is not centralized ..
- Costophrenic angle on the left side is free while in the right side is obliterated by heterogonous opacity .

Right lower lobe consolidation .

- Plain X ray chest & heart
- PA view
- The patient is not centralized .
- Shifted mediastinum & trachea to the same side .

- Costophrenic angle on the left side is free .

-The right side of chest is obliterated by homogenous opacity

Right pleural effusion with lung collapse .

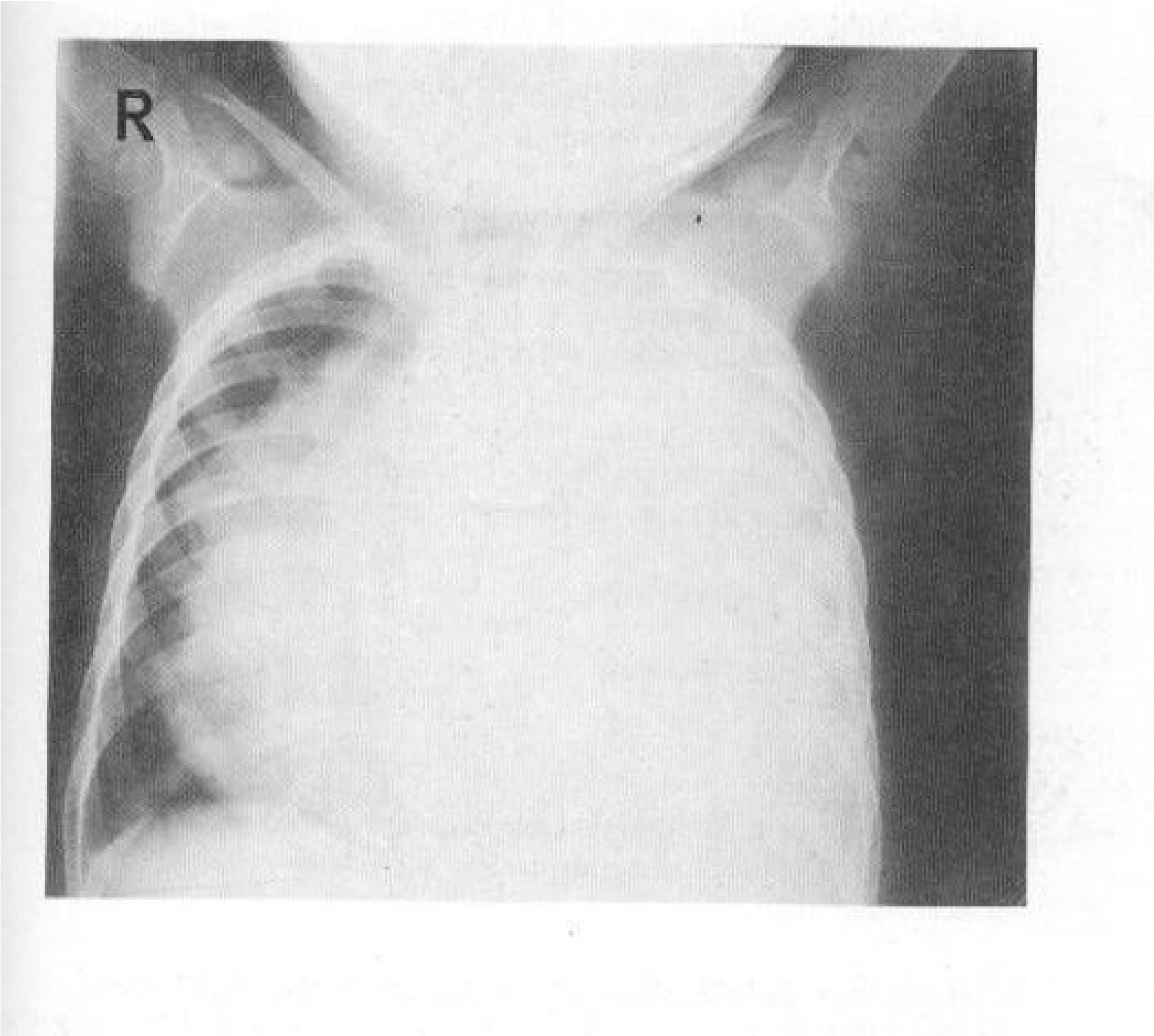

- Plain X ray chest & heart
- PA view
- The patient is centralized .
- Costophrenic angle on the RT side is free
- The LT sideof the chest is obliterated by homogenous opacity .
- Shifted mediastinum & trachea to the opposite side .

Massive left pleural effusion .

Freely you have received; freely give.

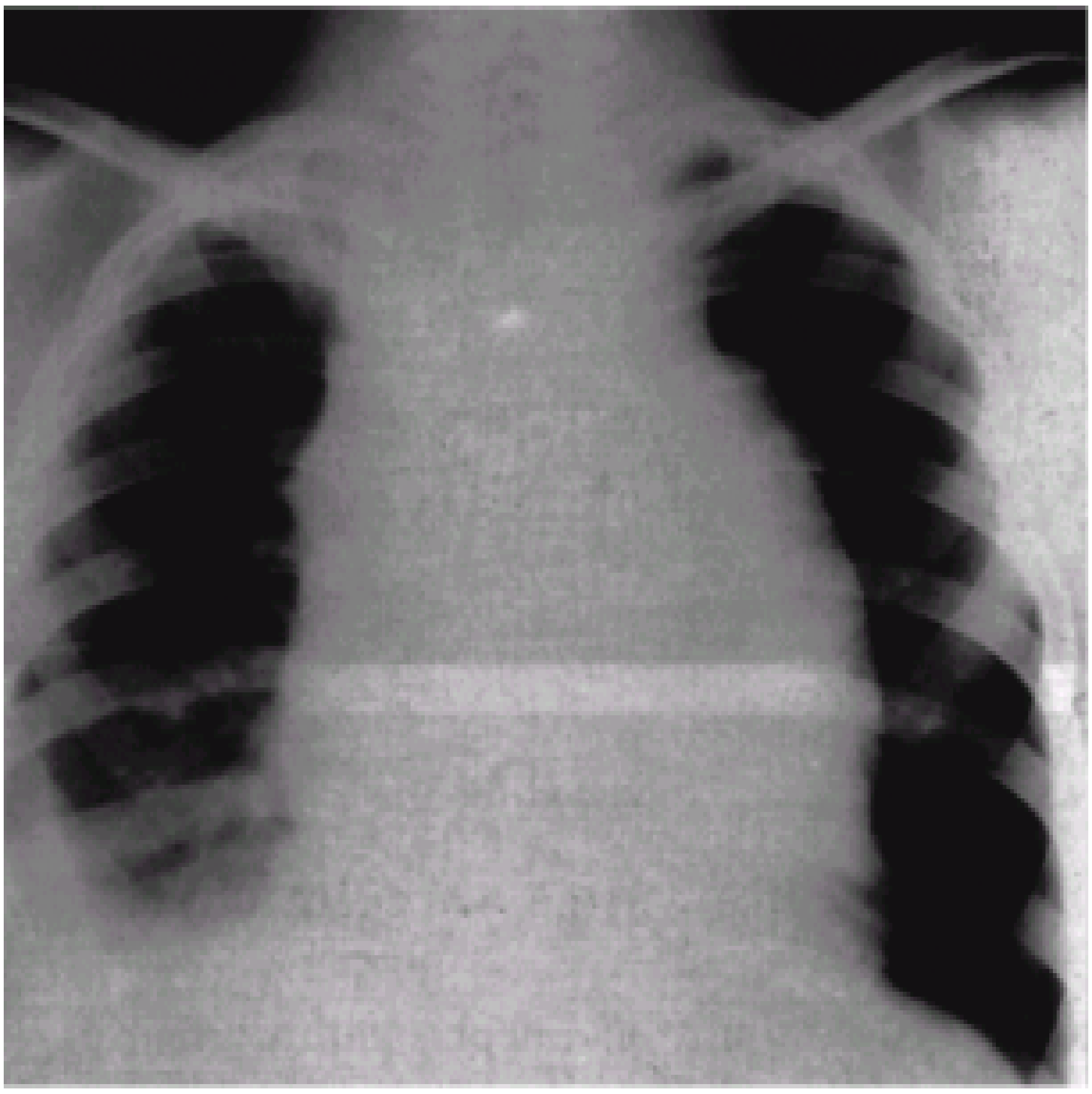

Minimal RT pleural effusion .

WhiteKnightLove

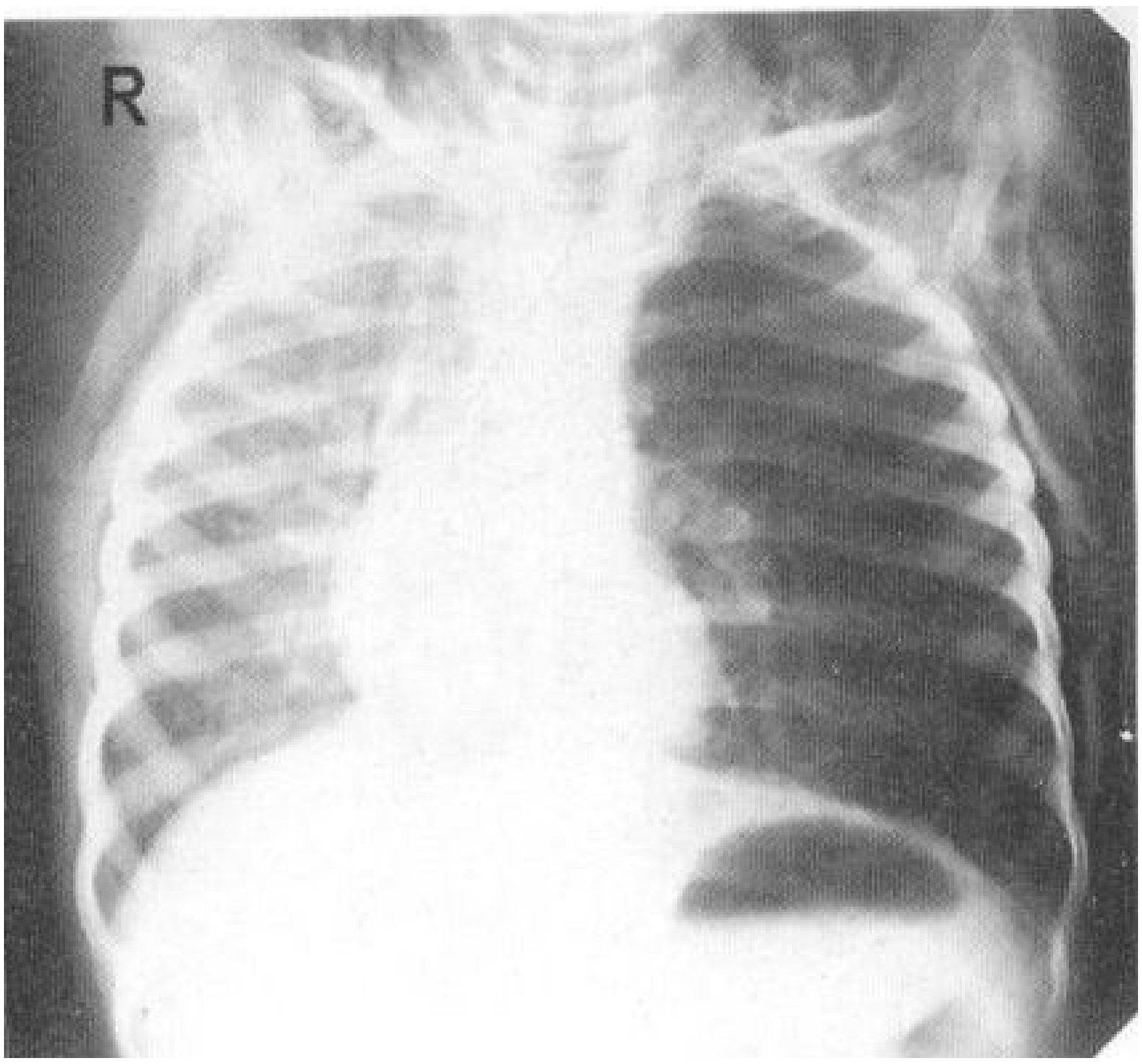

- Plain X ray chest & heart
- PA view
- The patient is not centralized .
- Left side emphysema with mediastinum shifted to the opposite side .

Left side emphysema.

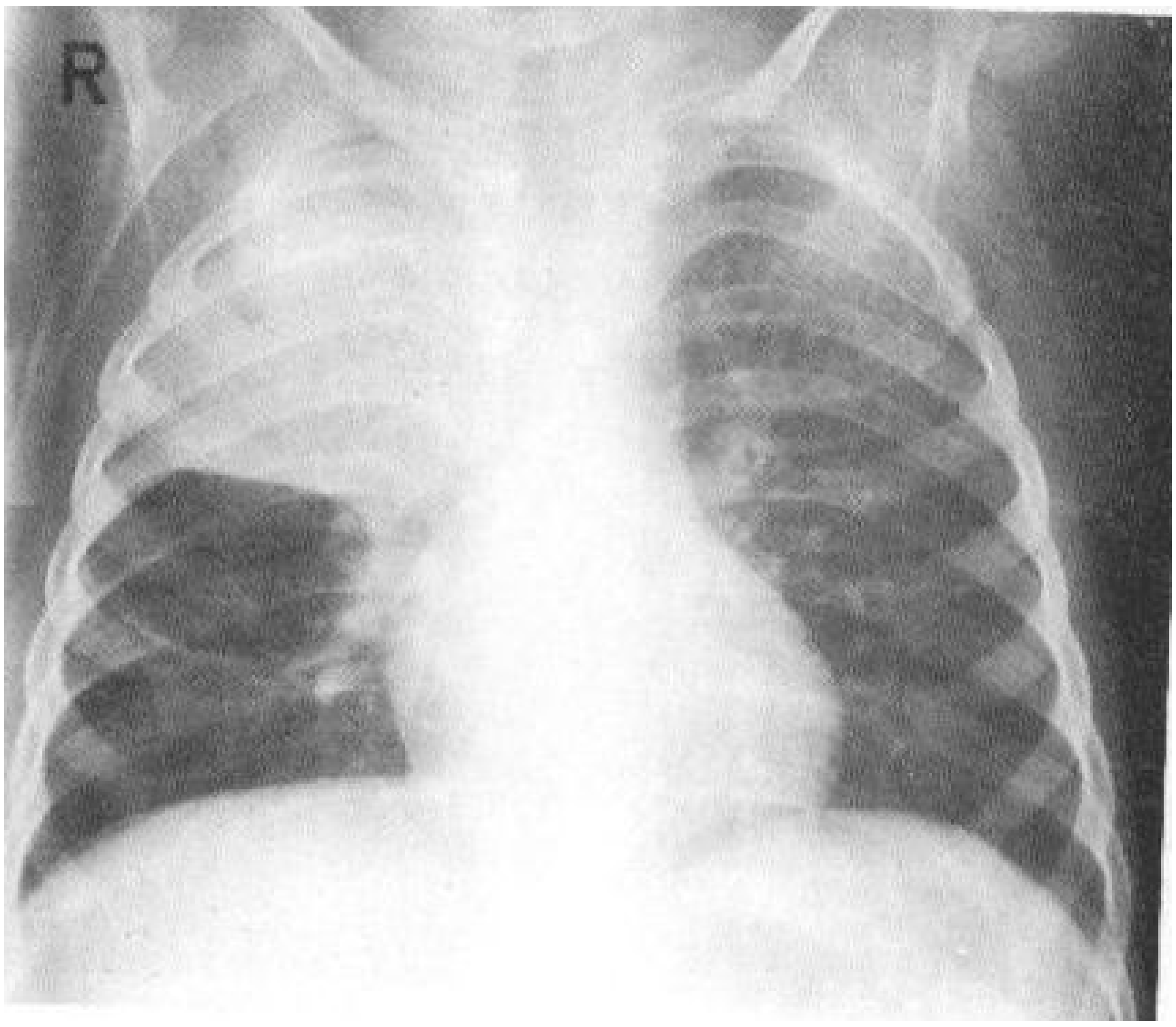

- Plain X ray chest & heart
- PA view
- The patient is not centralized ..
- Costophrenic angle on the both sides is free
- The upper and middle lobe of the right lung is obliterated by heterogonous opacity .

Right lobar pneumonia

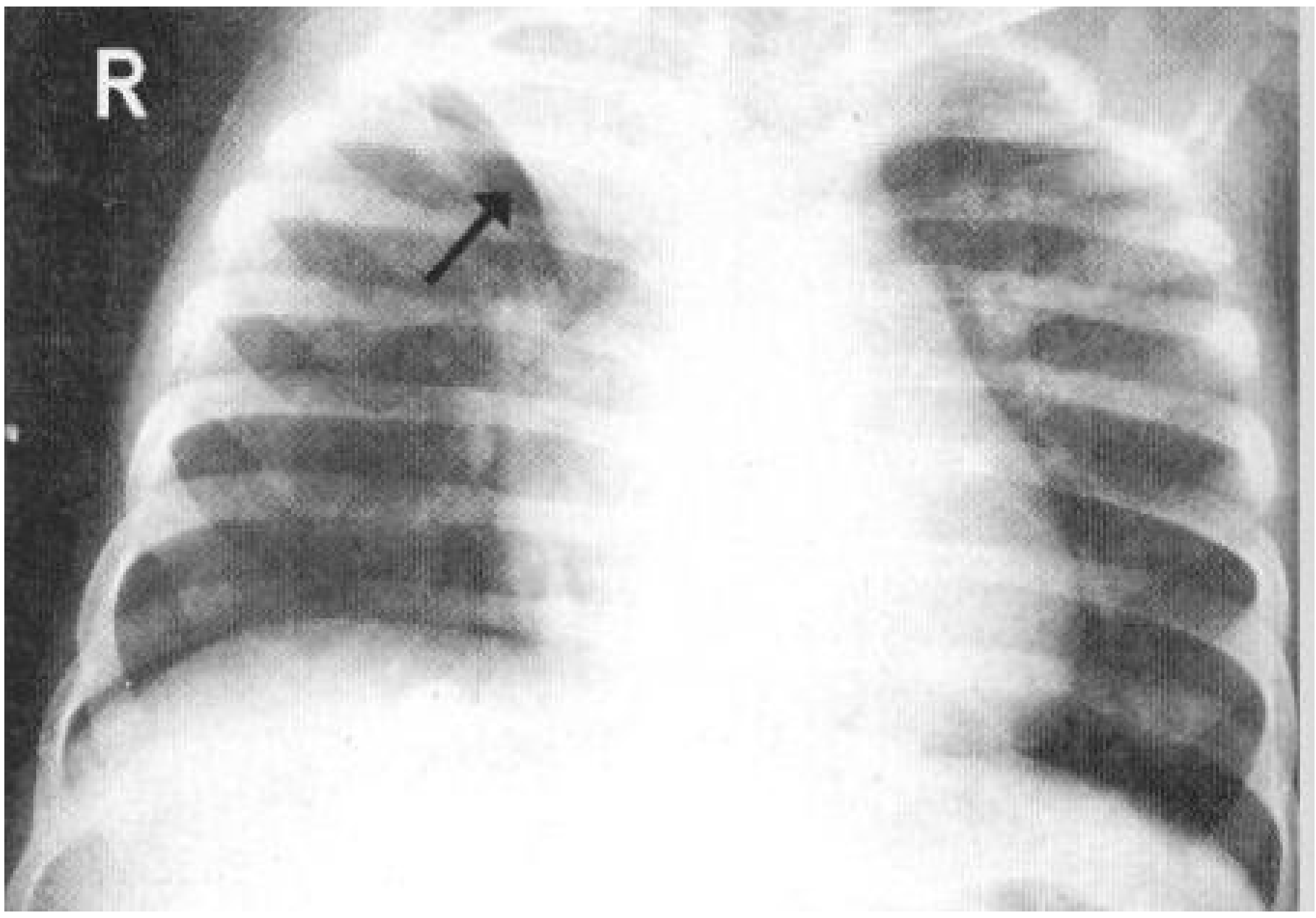

- Plain X ray chest & heart
- PA view
- The patient is not centralized.
- The mediastinum is central .
- Costophrenic angle on the both sides is free

The upper homogonous opacity of the right lung (triangular shape) .

Right upper lobar collapse .

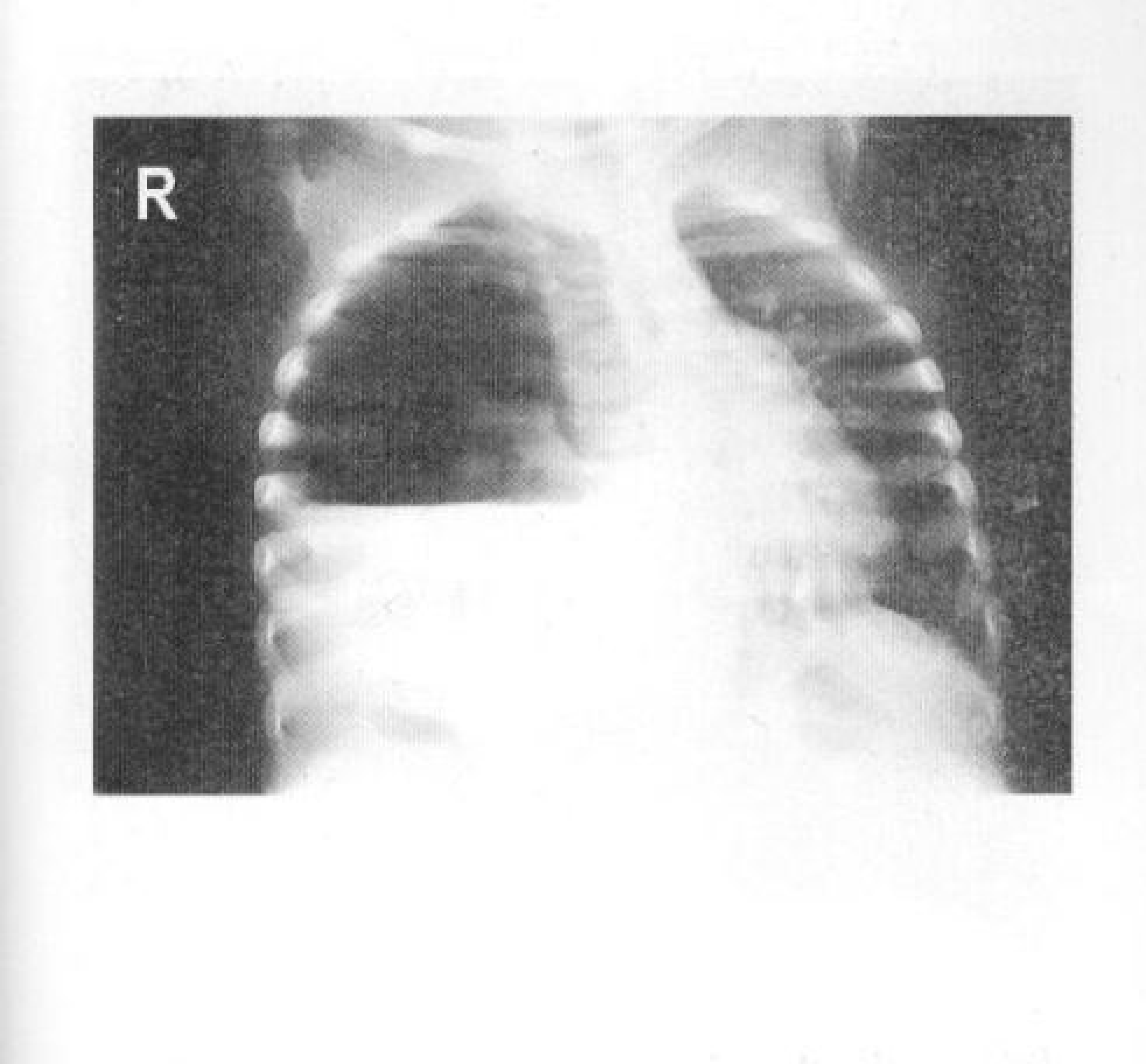

- Plain X ray chest & heart
- PA view
- The patient is not centralized .
- Shifted mediastinum to the opposite side .

- Costophrenic angle on the left side is free while in the right side is obliterated by homogenous opacity with transverse upper border (fluid level). The upper part of RT lung is jet black (air) .

Right hydropneumothorax .